

**Case Report****Myofibroma as a Rapidly Growing Gingival Mass in a 4-year-old Boy:  
a Case Report**Saede Atarbashi-Moghadam <sup>1</sup>, Ali Lotfi <sup>1</sup>, Shokoufeh Shahrabi-Farahani <sup>2</sup>, Fazele Atarbashi-Moghadam <sup>3</sup><sup>1</sup> Dept. of Oral and Maxillofacial Pathology, School of Dentistry, Shahid Beheshti University of Medical Sciences, Tehran, Iran.<sup>2</sup> Division of Oral and Maxillofacial Pathology, Dept. of Diagnostic Sciences and Oral Medicine, University of Tennessee Health Science Center, College of Dentistry, Memphis, TN.<sup>3</sup> Dept. of Periodontics, School of Dentistry, Shahid Beheshti University of Medical Sciences, Tehran, Iran.**KEY WORDS**Myofibroma;  
Smooth Muscle Actin;  
Gingiva;  
Immunohistochemistry;  
Soft Tissue Neoplasms;Received January 2017;  
Received in Revised form April 2017;  
Accepted May 2017;**ABSTRACT**

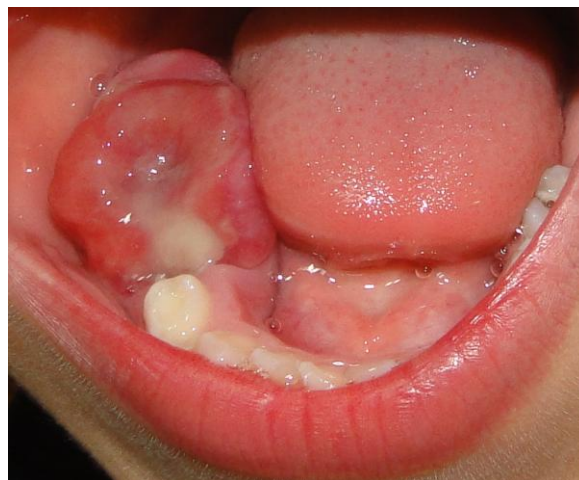Solitary myofibroma is an uncommon benign soft tissue neoplasm of myofibroblastic origin exhibiting head and neck region predilection but its presence in the jaws is rare. Myofibroma presents as painless mass and may demonstrate rapid enlargement and growth that clinically mimic malignancies. This report presents a 4-year-old male patient with a rapidly growing mandibular gingival mass with some evidence of underlying alveolar bone destruction. Incisional biopsy was performed and the specimen was stained with hematoxylin and eosin and immunohistochemical antibodies for  $\alpha$ SMA, CD34, S100 and desmin. The diagnosis of myofibroma was made and the lesion was completely excised. The knowledge about microscopic features of this rare neoplasm helps to have a proper diagnosis and avoid unnecessary treatment.

**Corresponding Author:** Atarbashi-Moghadam F., Dept. of Periodontics, 1st Floor, School of Dentistry, Shahid Beheshti University of Medical Sciences, Daneshjoo Blvd, Evin, Chamran HWY, Tehran, Iran.  
Email: fatarbashim@sbm.ac.ir Tel: +98-9123276580 Fax: +98-21-66597142

Cite this article as: Atarbashi-Moghadam S., Lotfi A., Shahrabi-Farahani Sh., Atarbashi-Moghadam F. Myofibroma as a Rapidly Growing Gingival Mass in a 4-year-old Boy: a Case Report. *J Dent Shiraz Univ Med Sci.*, 2018 June; 19(2): 164-167.

**Introduction**

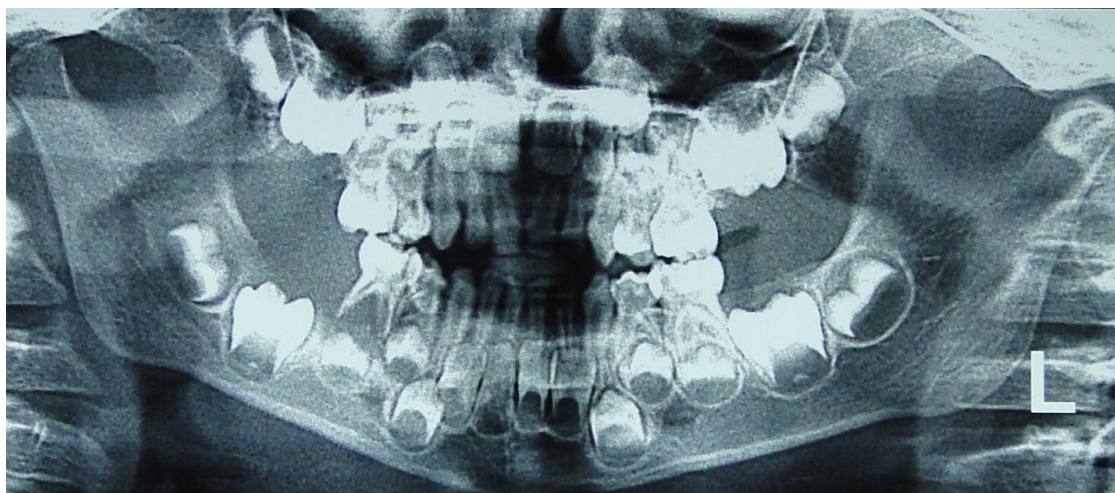
Myofibroma is a rare benign neoplasm of myofibroblastic origin with solitary or multicentric form. [1] Series of reports have shown a predilection for the head and neck region, oral cavity, in particular. [2-3] Intraorally, myofibroma presents as slow-growing painless mass with an intact overlying mucosa, but some may demonstrate rapid growth, which may lead to misdiagnosis as a sarcoma. [3] Children and young patients are more affected with a slight male predilection. [3-7] The mandibular gingiva and tongue are the most common sites of occurrence. [8] Some cases of oral myofibroma have been misdiagnosed because it may be confused with more aggressive spindle cell tumors. [9-10] This paper presents a case of myofibroma affecting the mandibular gingiva of a 4-year old boy and describes the clinical, histopathologic and immunohistochemical features along with a discussion about the differential diagnosis and importance of myofibroma cases diagnosis.



**Figure 1:** A painless focally ulcerative mandibular gingival mass

**Case Report**

A 4-year-old boy referred to a private oral and maxillofacial pathology center (Tehran, Iran) for evaluation of a rapidly growing, painless submucosal ulcerated mass in the right mandibular gingiva in retromolar pad area (be-



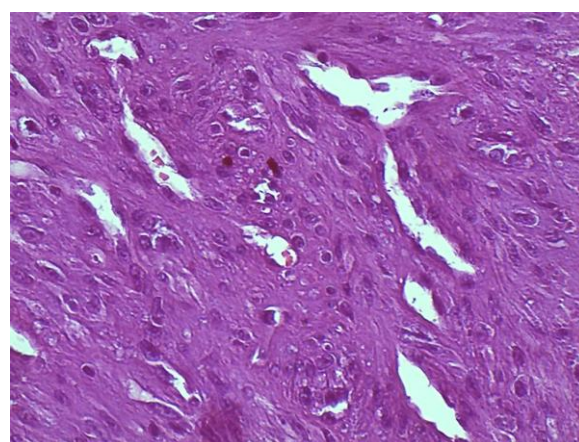
**Figure 2:** Panoramic radiography shows underlying bone erosion and bone destruction around the right second primary molar tooth

hind the right mandibular D) which had been present for four months (Figure 1). There was no history of previous trauma and the patient had no other medical problems. Extra-oral examination was normal. The mass was firm in consistency measuring 3.5×2.5cm.

The patient had incomplete closure of the mouth due to the occlusal interaction of the lesion with opposing teeth. The panoramic radiograph revealed evidence of alveolar ridge destruction and bone loss, which caused floating-in-air appearance of the right mandibular D (Figure 2). There was no cervical lymphadenopathy and the laboratory data were unremarkable.

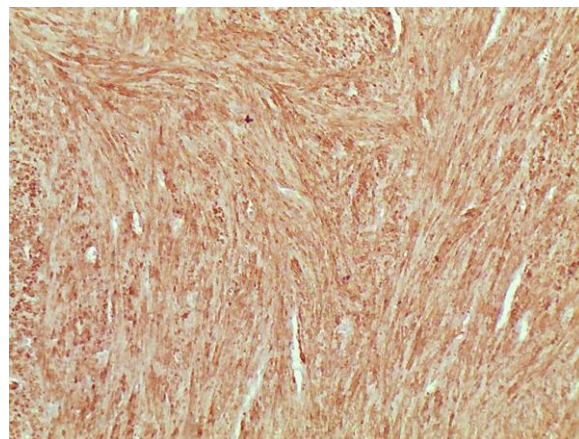
Considering both clinical and radiographic features, all those reactive/inflammatory lesions with potential aggressiveness (e.g. peripheral giant cell granuloma), local aggressive soft tissue neoplasms (e.g. fibromatosis) and malignant tumors (e.g. lymphoma and sarcomas) were considered in differential diagnosis. To make final diagnosis, incisional biopsy was performed under local anesthesia. The specimen demonstrated a solid, white, and homogenous cut surface and it was processed for Hematoxylin and Eosin histopathologic study.

Microscopic examination showed a soft tissue tumor covered by ulcerated mucosa, composed of interlacing bundles of spindle shaped cells with tapered and blunt-ended nuclei and eosinophilic cytoplasm. Prominent vascularity as hemangiopericytoma-like pattern and mild infiltration of mixed inflammatory cells were noted (Figure 3). Scattered mitosis was also seen but atypia was not present. The nature of the spindle cells was determined through immunohistochemistry (IHC).



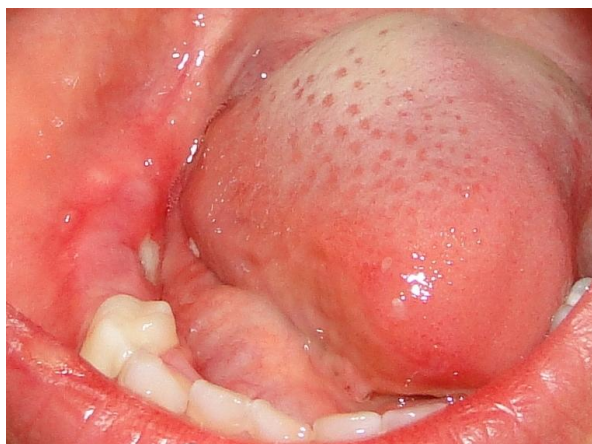
**Figure 3:** Fascicles of bland looking, spindle-shaped cells, exhibiting eosinophilic cytoplasm and prominent vascular structures (H & E, 100 X)

For IHC study, the avidin–biotin peroxidase complex method was used. The sections were stained with monoclonal antibodies for  $\alpha$ SMA, CD34, S100 and desmin. The tumoral cells were strongly and diffusely positive for  $\alpha$ SMA (Figure 4).



**Figure 4:** Positive cytoplasmic immunoreactivity for  $\alpha$ SMA antibody (immunohistochemistry, 100 X)

No immunoreactivity was seen for CD34, S100 and desmin. The histopathological features in combination with those immunohistochemical findings were consistent with the myofibroma diagnosis. The lesion was completely excised under general anesthesia. The histopathologic features of resected tumor confirmed the diagnosis of myofibroma. Clinical follow-up was performed at 3, 6, 12 and 22 months after surgery. The patient was free of disease for 2 years postoperatively (Figure 5).



**Figure 5:** Intra-oral examination shows healing surgical site after 12 months

### Discussion

The incidence of oral myofibroma is extremely low. Most of the reported cases of oral myofibroma were in children with slight male predilection. [3-7] Myofibroma characteristically presents as slow-growing, painless mass, but may exhibit rapid growth and ulceration, which increases the concern of a malignant process. [11] Myofibroma of the gingiva may involve the underlying bone as the present case. This condition was also described by Tanaka *et al.* [10] The myofibroma arising within the jaw bones in children may present two patterns of growth as shown by Abramowicz *et al.* [4]; one type as an aggressive exophytic type associated with ulcerated gingival mass of rapid growth, and the other type as nonaggressive intra-osseous type which may be found incidentally. Our case presented as a rapidly growing, predominantly exophytic, ulcerated gingival mass. Seemingly, our case was an example of extra-osseous myofibroma with some evidence of underlying bone involvement.

Diagnosis of myofibroma is based on histopathologic and immunohistochemical studies. Myofibroma

are composed of spindle-shaped cells arranged in fascicles with indistinct eosinophilic cytoplasmic border and bland-looking nuclei. Pleomorphism and mitotic figures are rarely seen in myofibroma although some features including loosely cohesive or absent myoid nodules, infiltrating borders, intravascular growth and perineural invasion/nerve entrapment and mitosis (5 mitoses/10 high-power fields) have been considered in the morphologic spectrum of this tumor. [12] Hemangiopericytoma-like pattern of stromal structures is characteristic in myofibroma. [3] In histopathologic differential diagnosis, all benign and malignant tumors with spindle-shaped cells can be considered, particularly those, which are commonly seen in children. These tumors include fibromatosis, spindle cell rhabdomyosarcoma and infantile fibrosarcoma. Chinta *et al.* [13] reported a case of myofibroma, which was histopathologically diagnosed as fibrosarcoma. Precise and careful histopathologic and immunohistochemical studies are needed for distinguishing myofibroma from such tumors to avoid any misdiagnosis and mismanagement. [13-14]

Immunohistochemically, myofibroma shows reactivity to vimentin and  $\alpha$ -SMA, but is negative for CD34 (excluding the diagnosis of solitary fibrous tumor/ hemangiopericytoma), S100 (excluding the diagnosis of neural tumors) and desmin (excluding the diagnosis of smooth muscle tumors). [3, 5, 8-9] The very low rate of cell proliferation is valuable information in order to exclude malignant mesenchymal neoplasms. [14] Immunohistochemical analysis of the present case confirmed the diagnosis of myofibroma.

The etiology and pathogenesis of myofibroma is still unknown, although autosomal dominant and recessive patterns of inheritance have been reported in cases of infantile myofibromatosis. [15] Some investigators have shown few cytogenetic abnormalities such as monosomy 9q, trisomy 16q, and del (6) (q12;q15). [16-18] Eley *et al.* [11] suggested a previous history of trauma as a possible cause for development of myofibroma in their case, which occurred after tooth extraction. Our case showed neither familial history nor trauma.

The treatment of choice for solitary myofibroma is complete excision with a border of clinically normal tissue because they are unencapsulated tumors. The recurrence rates for myofibromas are relatively low and can be associated with difficult surgical access or in-

complete elimination. [3] In our current case, there was no evidence of tumor for two years of regular postsurgical follow-up. No malignant transformation was reported for myofibroma. [3]

### Conclusion

In case of a rapidly growing soft tissue mass in the gingiva in child, myofibroma should be considered in differential diagnosis. Precise evaluation of the histopathologic features and immunohistochemical studies are essential for definite diagnosis, to prevent any misdiagnosis with some malignant spindle cell tumors, and to provide appropriate treatment.

### Acknowledgments

The authors would like to appreciate Dr. Rezvani for his help as pediatric dentist.

### Conflict of Interest

The authors of this manuscript certify that they have no financial or other competing interest concerning this article.

### References

- [1] Lee YM, Son SM, Kim KW, Lee OJ. Solitary myofibroma of the adult mandible: a case report and review of literature. *Korean J Pathol.* 2014; 48: 307-310.
- [2] Beham A, Badve S, Suster S, Fletcher CD. Solitary myofibroma in adults: clinicopathological analysis of a series. *Histopathology.* 1993; 22: 335-341.
- [3] Foss RD, Ellis GL. Myofibromas and myofibromatosis of the oral region: A clinicopathological analysis of 79 cases. *Oral Surg Oral Med Oral Pathol Oral Radiol Endod.* 2000; 89: 57-65.
- [4] Abramowicz S, Simon LE, Kozakewich HP, Perez-Atayde AR, Kaban LB, Padwa BL. Myofibromas of the jaws in children. *J Oral Maxillofac Surg.* 2012; 70: 1880-1884.
- [5] Narayen V, Ahmed SA, Suri C, Tanveer S. Myofibroma of the gingiva: a rare case report and literature review. *Case Rep Dent.* 2015; 2015: 243894.
- [6] Andreadis D, Epivatianos A, Samara A, Kirili T, Iordanidis F, Pouloupoulos A. Myofibroma of the oral mucosa: a case report. *Med Princ Pract.* 2012; 21: 288-291.
- [7] Brasileiro BF, Martins-Filho PR, Piva MR, da Silva LC, Nonaka CF, Miguel MC. Myofibroma of the oral cavity. A rare spindle cell neoplasm. *Med Oral Patol Oral Cir B-ucal.* 2010; 15: e596-e600.
- [8] Aiki M, Yoshimura H, Ohba S, Kimura S, Imamura Y, Sano K. Rapid growing myofibroma of the gingiva: report of a case and review of the literature. *J Oral Maxillofac Surg.* 2014; 72: 99-105.
- [9] Jordan RC, Regezi JA. Oral spindle cell neoplasms: a review of 307 cases. *Oral Surg Oral Med Oral Pathol Oral Radiol Endod.* 2003; 95: 717-724.
- [10] Tanaka Y, Yamada H, Saito T, Nakaoka K, Kumagai K, Fujihara H, et al. Solitary myofibroma of the mandible in an adult with magnetic resonance imaging and positron emission tomography findings: a case report. *World J Surg Oncol.* 2014; 12: 69.
- [11] Eley KA, Fisher C, Gould S, Watt-Smith SR. A rapidly enlarging mandibular swelling. *Oral Surg Oral Med Oral Pathol Oral Radiol.* 2013; 115: 431-435.
- [12] Linos K, Carter JM, Gardner JM, Folpe AL, Weiss SW, Edgar MA. Myofibromas with atypical features: expanding the morphologic spectrum of a benign entity. *Am J Surg Pathol.* 2014; 38: 1649-1654.
- [13] Chinta M, Sankar AJ, Gantha SN, Kanumuri PK. Tumour that challenged diagnosis: mandibular myofibroma. *BMJ Case Rep.* 2016; 2016. pii: bcr2016217890. doi: 10.1136/bcr-2016-217890.
- [14] Lopes RN, Alves Fde A, Rocha AC, Suassuna TM, Kowalski LP, de Castro JF, et al. Head and neck solitary infantile myofibroma: Clinicopathological and immunohistochemical features of a case series. *Acta Histochem.* 2015; 117: 431-436.
- [15] Zand DJ, Huff D, Everman D, Russell K, Saitta S, McDonald-McGinn D, et al. Autosomal dominant inheritance of infantile myofibromatosis. *Am J Med Genet A.* 2004; 126A: 261-266.
- [16] Thennavan A, Narayanaswamy V, Niazi TM, Rao L, Radhakrishnan R. Infantile myofibroma eroding into the frontal bone: a case report and review of its histopathologic differential diagnosis. *Case Rep Pediatr.* 2012; 2012: 630804.
- [17] Sirvent N, Perrin C, Lacour JP, Maire G, Attias R, Pedoutour F. Monosomy 9q and trisomy 16q in a case of congenital solitary infantile myofibromatosis. *Virchows Arch.* 2004; 445: 537-540.
- [18] Stenman G, Nadal N, Persson S, Gunterberg B, Angervall L. del(6)(q12q15) as the sole cytogenetic anomaly in a case of solitary infantile myofibromatosis. *Oncol Rep.* 1999; 6: 1101-1104.