

Literature Review

Decompression or Marsupialization; Which Conservative Treatment is Associated with Low Recurrence Rate in Keratocystic Odontogenic Tumors? A Systematic Review

Reza Tabrizi, DMD, MScD¹- Mohammad Reza Hosseini Kordkheili, DMD²-Mohammad Jafarian, DMD, MScD¹- Farzad Aghdashi DMD, MScD¹

¹ Dept. of Oral and Maxillofacial Surgery, Dental School, Shahid Beheshti University of Medical Sciences, Tehran, Iran.

² Dental School, Shahid Beheshti University of Medical Sciences, Tehran, Iran.

KEY WORDS

Odontogenic cysts;
Mandible;
Decompression;
Jaw Cysts;

ABSTRACT

Various treatment modalities have been reported for keratocystic odontogenic tumors (KOT), with different recurrence rates. Marsupialization and decompression are two different conservative surgical techniques for the treatment of KOTs.

This study aimed at comparing the recurrence rate between marsupialization and decompression in the treatment of KOTs with or without adjunctive treatments.

This is a systematic review study. The research sources utilized were PubMed (MEDLINE), Google scholar, Ovid MEDLINE and Cochrane Library. The keywords which were selected based on Medical Subject Heading (MeSH) terms and PICOS criteria were odontogenic keratocyst, keratocyst odontogenic tumor AND marsupialization OR decompression OR cystectomy OR enucleation OR curettage. Statistical analyses were performed to compare the recurrence rate between marsupialization and decompression with or without adjunctive treatments, regarding various follow-up times.

The number of subjects that underwent marsupialization was 182. There was a significant difference for the recurrence rate between the marsupialization and decompression groups without considering adjunctive treatments ($p=0.001$). However, considering adjunctive treatments, there was no difference between marsupialization and the decompression groups ($p=0.18$).

It appears that decompression without any adjuvant treatment may have a lower recurrence rate than marsupialization. The recurrence rate was not different when enucleation or cystectomy was performed after decompression and marsupialization.

Corresponding Author: Hosseini Kordkheili MR, OMFS Dept. Shahid Beheshti Dental School, Velenjak, Tehran, Iran. Tel: +98-9128988150 Email: mohammadrezaho3eini@gmail.com

Received: October 2018;
Revised: November 2018;
Accepted: December 2018;

Cite this article as: Tabrizi R, Hosseini Kordkheili MR, Jafarian M, Aghdashi F. Decompression or Marsupialization; Which Conservative Treatment is Associated with Low Recurrence Rate in Keratocystic Odontogenic Tumors? A Systematic Review. *J Dent Shiraz Univ Med Sci.* 2019; 20(3): 145-151.

Introduction

The keratocystic odontogenic tumor (KOT) is locally aggressive with a high recurrence rate compared to other odontogenic cysts and neoplasms. KOTs have the tendency to invade adjacent tissues [1]. It was described by Philipsen in 1956 [2] as an odontogenic keratocyst. KOT was named in 2005, when the World Health Organization termed KOT over odontogenic keratocyst which had been used as a traditional term [3].

Various treatment modalities have been reported with differing recurrence rates: Enucleation [4], enu-

cleation with cryotherapy [5], marsupialization [6], decompression [7] and resection [8]. Marsupialization and decompression have been defined as different surgical techniques. These approaches are aimed at decreasing the size of extensive KOTs prior to enucleation [9] or completely solve the lesions [6]. The main advantage of marsupialization and decompression is the preservation of important anatomical structures such as inferior alveolar nerve and the prevention of a consequent possible deformity [10]. In marsupialization technique, a part of the KOT's body is cut and removed followed by sutur-

ing the lesion's exposed boundaries to the adjacent mucosa. The created surgical window exposes the cyst to the oral cavity. In the decompression technique, a drain is placed in the lesion, which maintains communication with the cystic cavity. This decreases the intracystic pressure and may result in bone formation [11]. The main difference between these two techniques is the use of a cylindrical device (drain) to prevent closure of the mucosa [12]. Both techniques result in a decrease of the intraluminal pressure/volume or resolving KOT. The lining of many decompressed or marsupialized cysts are more similar to the oral mucosa than to KOT in histological evaluation [11, 13]. There is no universal consensus regarding the best management of KOTs.

Concerning the KOTs of jaws, this review was conducted to find out which conservative treatment is associated with a lower recurrence rate and determine if it is necessary to have adjunctive modalities in conservative treatment. It may be hypothesized that there is no difference in the recurrence rate of marsupialization and decompression techniques. Therefore, the aim of this review was to compare the recurrence rate of these two methods with or without adjunctive treatments.

Description of search strategy of relevant literature

Objective

The objective of this study was to compare the recurrence rate between marsupialization and decompression in the treatment of KOTs with or without adjunctive treatments.

Criteria for considering studies (PICO)

The studies considered for inclusion in this literature review include case series, retrospective and prospective cohort studies, and randomized clinical trial studies (Table 1).

Search Strategies

The PubMed (MEDLINE) database of the United States

Table 1: Issues of interest based on study population, intervention, control group and outcome measures (PICO)

Parameters for eligible studies

P	Patients who had non-syndromic KOT
I	Marsupialization and decompression with or without cystectomy
C	Marsupialization without cystectomy Decompression without cystectomy
O	Marsupialization follows by cystectomy Decompression follows by cystectomy
O	Recurrence rate
P, population; I, intervention; C, control; O, outcome.	

National Library of Medicine, Google scholar, Ovid MEDLINE and Cochrane Library were used as search sources. The keywords were selected based on Medical Subject Heading (MeSH) terms and PICOS criteria. The keywords for search included: odontogenic keratocyst, KOT and marsupialization OR decompression OR cystectomy OR enucleation OR curettage. To avoid missing an article, the references of each selected manuscript was rechecked manually through Google Scholar.

Inclusion criteria

A protocol was used for establishment of the inclusion and exclusion criteria. Full-text articles in English language were assessed for the following inclusion criteria including (1) patients who had non-syndromic pathologic proved KOTs, (2) the technique was decompression or marsupialization with or without enucleation or cystectomy and (3) the follow-up time was documented. Studies were excluded if they were animal or *in vitro* studies. Duplicate publications (risk of bias), syndromic KOTs, articles without histopathological diagnosis or without complete demographic information of each patient were removed from the study.

Quality assessment

Each full-text article was evaluated by two reviewers. We followed the methodological index for non-randomized studies (MINORS) which had a clearly stated aim, inclusion of consecutive patients, prospective collection of data, endpoints appropriate to the aim of the study, unbiased assessment of the study endpoint, follow-up period appropriate to the aim of the study, loss to follow-up less than 5% and prospective calculation of the study size [14]. This systematic review was conducted based on the Preferred Reporting Items for Systematic reviews and Meta-Analyses (PRISMA) statement for reporting systematic reviews [15].

Statistical analysis

The statistical analyses were conducted using the statistical package SPSS for PCs, version 19 (IBM, USA). Kaplan Miere test (Log-rank) was applied to compare the recurrence rate between study groups regarding diverse follow-up times.

Evaluation of papers and level of evidence

In an initial research, 1096 articles were identified through electronic database. After removing duplications, 593 articles were evaluated. Twenty-five manuscripts met the inclusion criteria of the research. The

total subject number was 341 (Table 2). The mean follow up time was 58.30±32.80 months.

The number of subjects who underwent marsupialization was 182 (118 subjects received marsupialization without any adjunctive treatments, 64 underwent enucleation or cystectomy after marsupialization) and 159 subjects received decompression (74 subjects underwent decompression without any adjunctive treatments whereas 85 subjects had enucleation or cystectomy after decompression) (Figure 1).

In 118 subjects who had marsupialization without any extra treatments, 32(27.12%) subjects experienced recurrence lesion whereas among 64 subjects who received marsupialization with enucleation or cystectomy, 7(10.94 %) subjects had recurrence lesion. In 74 subjects who underwent decompression without any extra treatments, 4(5.40%) subjects had recurrence lesions and in 85 subjects who had decompression + enucleation or cystectomy, 12 (14.12%) subjects had recurrence lesions (Table 3). Log rank test showed a significant difference for the recurrence rate between the marsupialization and decompression groups without considering adjunctive treatments ($p= 0.001$) (Figure 2). However,

considering adjunctive treatments, there was no difference between the marsupialization and decompression groups ($p= 0.18$).

Discussion

KOTs are common benign jaw lesions, which are associated with high recurrence rate after various treatments. Aggressive treatments such as partial resection have a low risk of recurrence. However, jaw deformity and the need of further reconstruction are the drawbacks of such treatments [39]. In this systematic review, the recurrence rates of two conservative treatments with or without adjuvant procedures were evaluated.

In the first analysis, the recurrence rate was higher in the marsupialization group without any adjuvant treatments. It could be hypothesized that creating a larger window in marsupialization than decompression increased the risk of distribution of daughter cysts which increase the recurrence rate. In fact, a small path is created for the placement of a drain in decompression, which results to minimal manipulation of the KOT wall. In the second analysis, there was no statistical difference for the recurrence rate between marsupialization and

Table 2: Summary of the involved studies

Author	Year	Follow up(months)	Case number	Primary treatment	Secondary Treatment	Recurrence
Ribeiro-Júnior et al.[16]	2017	43.5	15	Decompression	Enucleation	2(15.4%)
Zhang et al. [17]	2016	21	1	Decompression	Enucleation	1(100%)
de Molon et al. [18]	2015	60	1	Marsupialization	No	0
Srivatsan et al. [19]	2014	36	2	Marsupialization	No	0
Padaki et al. [20]	2014	60	1	Decompression	No	0
Hyun et al. [21]	2009	43	1	Decompression	No	1(100%)
Pogrel[22]	2013	34.8	10	Marsupialization	No	0
Berge et al. [23]	2016	66	70	Marsupialization	No	23(32.86%)
Tabrizi et al. [24]	2012	60	13	Marsupialization	Enucleation in 3 cases	0
Güler et al. [25]	2012	40.54	30	Marsupialization	Enucleation	0
Rossi et al. [26]	2012	60	3	Marsupialization	Cystectomy	0
Zecha et al. [27]	2010	58	10	Marsupialization	No	4(40%)
Matijević et al. [28]	2012	84	1	Marsupialization	Enucleation	0
Madras et al. [29]	2008	24	3	Marsupialization	No	0
Habibi et al. [30]	2007	32.5	6	Marsupialization	No	2(33.33%)
Habibi et al. [30]	2007	32.5	11	Marsupialization	Enucleation	0
Nakamura et al. [31]	2002	24	23	Marsupialization	Enucleation	6 (26.08%)
Nakamura et al. [31]	2002	24	5	Marsupialization	No	0
Marker et al. [32]	1996	156	12	Decompression	Cystectomy	0
Marker et al. [32]	1996	56.4	11	Decompression	Cystectomy	2(18.18%)
Brøndum et al. [33]	1991	108	44	Decompression	Cystectomy	8(18.18%)
Maurette et al. [12]	2006	24.89	28	Decompression	No	4(14.3%)
Tolstunov et al. [34]	2008	30	1	Marsupialization	Cystectomy	1(100%)
Zhao et al. [35]	2002	93.6	11	Marsupialization	Enucleation	0
Jung et al. [36]	2005	24	2	Decompression	Enucleation	0
August et al. [37]	2003	33.6	14	Decompression	No	0
Kolokythas et al. [2]	2007	24	11	Marsupialization	No	2(18.18%)
Sánchez-Burgos et al.[38]	2014	60	2	Marsupialization	No	1(50%)

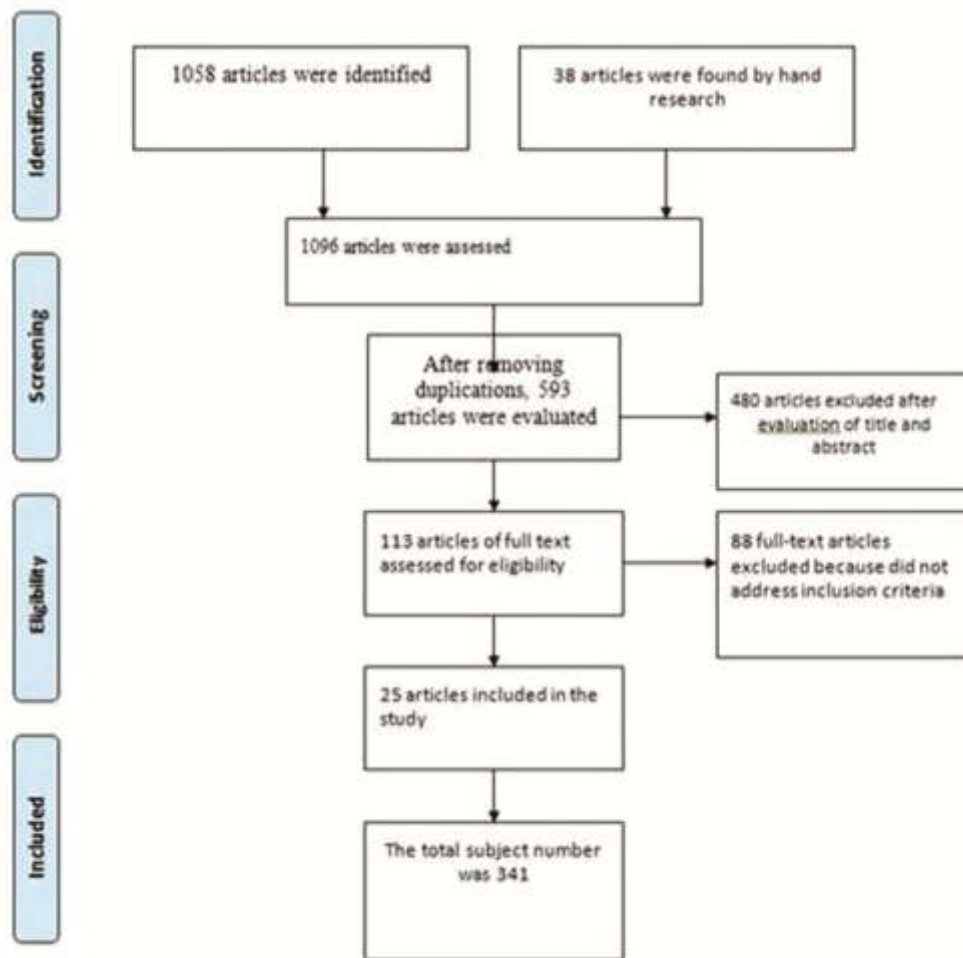


Figure 1: Flowchart of the systematic review process (PRISMA 2009 Flow Diagram) [15]

Table 3: Outcomes of various KOTs treatments

Treatment groups	With recurrence	Without recurrence
Marsupialization	32(27.12%)	86(72.88%)
Without extra treatments 118(N)	7 (10.94%)	57(89.06%)
With extra treatments 64 (N)		
Decompression	4 (5.40%)	81(94.60%)
Without extra treatments 74(N)	12 (14.12%)	73(85.88%)
With extra treatments 85 (N)		

decompression with further enucleation or cystectomy. Removing any remnant lesion by enucleation or cystectomy may serve as an explanation of this event.

Al-Moraissi *et al.* [40] conducted a systematic review on recurrence rate following various treatments in KOTs. They concluded that cystectomy is necessary after marsupialization for the reduction of recurrence rate. A systematic review was performed by de Castro *et al.* [11] on the conservative treatments of KOTs. Their results demonstrated a lower recurrence rate in decompression, followed by enucleation compared to pure enucleation.

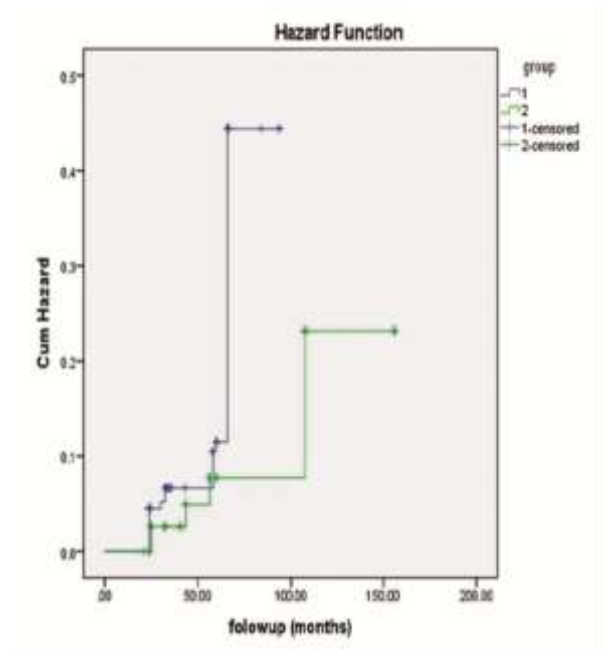


Figure 2: Hazard plot according to Kaplan Meier test (Log-rank) for recurrence of KOTs in group1 (Marsupialization group) and group 2 (Decompression)

Wushou and Zhao [10] stated that marsupialization decreases the recurrence of KOTs more than enucleation and surgical resection and it may be the ideal treatment for KOTs. Antonoglou *et al.* [3] studied non-syndromic and syndromic KOTs in a systematic review and meta-analysis for recurrences. They concluded that resection or marsupialization might be associated with a lower recurrence rate. It was suggested that the use of a cyst plug following marsupialization, might accelerate bone regeneration in large mandibular KOTs [41].

In a systematic review by Mojsa *et al.* [13], no high quality evidence was found after assessing recurrence rates in terms of the treatment modalities of KOTs. In many articles, the surgical approach for decompression or marsupialization was not clearly described. This could be regarded as a limitation for this study [6, 9-10]. Pogrel and Jordan [6] mentioned that the terms decompression and marsupialization were applied interchangeably in some articles. However, they are different techniques.

Conclusion

It appears that decompression without any adjuvant treatment may have a lower recurrence rate than marsupialization. The recurrence rate was not different when enucleation or cystectomy was performed following decompression and marsupialization.

Conflict of Interest

None declared.

References

- [1] Chirapathomsakul D, Sastravaha P, Jansisanont P. A review of odontogenic keratocysts and the behavior of recurrences. *Oral Surg Oral Med Oral Pathol Oral Radiol Endod.* 2006; 101: 5-9.
- [2] Kolokythas A, Fernandes RP, Pazoki A, Ord RA. Odontogenic keratocyst: to decompress or not to decompress? A comparative study of decompression and enucleation versus resection/peripheral osteotomy. *J Oral Maxillofac Surg.* 2007; 65: 640-644.
- [3] Antonoglou GN, Sándor GK, Koidou VP, Papageorgiou SN. Non-syndromic and syndromic keratocystic odontogenic tumors: Systematic review and meta-analysis of recurrences. *Journal of Cranio-Maxillo-Facial Surgery.* 2014; 42: e364-e371.
- [4] Singh M, Gupta K. Surgical treatment of odontogenic keratocyst by enucleation. *Contemp Clin Dent.* 2010; 1: 263-267.
- [5] Schmidt BL, Pogrel MA. The use of enucleation and liquid nitrogen cryotherapy in the management of odontogenic keratocysts. *J Oral Maxillofac Surg.* 2001; 59: 720-725.
- [6] Pogrel MA, Jordan RC. Marsupialization as a definitive treatment for the odontogenic keratocyst. *J Oral Maxillofac Surg.* 2004; 62: 651-655.
- [7] Marker P, Brøndum N, Clausen PP, Bastian HL. Treatment of large odontogenic keratocysts by decompression and later cystectomy: a long-term follow-up and a histologic study of 23 cases. *Oral Surg Oral Med Oral Pathol Oral Radiol Endod.* 1996; 82: 122-131.
- [8] Williams TP, Connor FA Jr. Surgical management of the odontogenic keratocyst: aggressive approach. *J Oral Maxillofac Surg.* 1994; 52: 964-966.
- [9] Dohan Ehrenfest DM, Rasmusson L, Albrektsson T. Classification of platelet concentrates: from pure platelet-rich plasma (P-PRP) to leucocyte- and platelet-rich fibrin (L-PRF). *Trends Biotechnol.* 2009; 27: 158-167.
- [10] Wushou A, Zhao YJ, Shao ZM. Marsupialization is the optimal treatment approach for keratocystic odontogenic tumour. *J Craniomaxillofac Surg.* 2014; 42: 1540-1544.
- [11] de Castro MS, Caixeta CA, de Carli ML, Ribeiro Júnior NV, Miyazawa M, Pereira AAC, et al. Conservative surgical treatments for nonsyndromic odontogenic keratocysts: a systematic review and meta-analysis. *Clin Oral Investig.* 2018; 22: 2089-2101.
- [12] Maurette PE, Jorge J, de Moraes M. Conservative treatment protocol of odontogenic keratocyst: a preliminary study. *J Oral Maxillofac Surg.* 2006; 64: 379-383.
- [13] Kaczmarzyk T, Mojsa I, Stypulkowska J. A systematic review of the recurrence rate for keratocystic odontogenic tumour in relation to treatment modalities. *Int J Oral Maxillofac Surg.* 2012; 41: 756-767.
- [14] Slim K, Nini E, Forestier D, Kwiatkowski F, Panis Y, Chipponi J. Methodological index for non-randomized studies (minors): development and validation of a new instrument. *ANZ J Surg.* 2003; 73: 712-716.
- [15] Liberati A, Altman DG, Tetzlaff J, Mulrow C, Gøtzsche PC, Ioannidis JP, et al. The PRISMA statement for reporting systematic reviews and meta-analyses of studies that evaluate health care interventions: explanation and elaboration. *PLOS Medicine.* 2009; 6: e1000100.

- [16] Ribeiro-Júnior O, Borba AM, Alves CAF, Gouveia MM, Deboni MCZ, Naclério-Homem MDG. Reclassification and treatment of odontogenic keratocysts: A cohort study. *Braz Oral Res.* 2017; 31: e98.
- [17] Zhang Q, Li W, Han F, Huang X, Yang X. Recurrent keratocystic odontogenic tumor after effective decompression. *J Craniofac Surg.* 2016; 27: e490-e491.
- [18] de Molon RS, Verzola MH, Pires LC, Mascarenhas VI, da Silva RB, Cirelli JA, et al. Five years follow-up of a keratocyst odontogenic tumor treated by marsupialization and enucleation: A case report and literature review. *Contemp Clin Dent.* 2015; 6(Suppl 1): S106-S110.
- [19] Srivatsan KS, Kumar V, Mahendra A, Singh P. Bilateral keratocystic odontogenic tumor: A report of two cases. *Natl J Maxillofac Surg.* 2014; 5: 86-89.
- [20] Padaki P, Laverick S, Bounds G. Conservative management of a large keratocystic odontogenic tumour. *J Surg Case Rep.* 2014; 2014: rju091.
- [21] Hyun HK, Hong SD, Kim JW. Recurrent keratocystic odontogenic tumor in the mandible: a case report and literature review. *Oral Surg Oral Med Oral Pathol Oral Radiol Endod.* 2009; 108: e7-e10.
- [22] Pogrel MA. Decompression and marsupialization as a treatment for the odontogenic keratocyst. *Oral Maxillofac Surg Clin North Am.* 2003; 15: 415-427.
- [23] Berge TI, Helland SB, Sælen A, Øren M, Johannessen AC, Skartveit L, et al. Pattern of recurrence of nonsyndromic keratocystic odontogenic tumors. *Oral Surg Oral Med Oral Pathol Oral Radiol.* 2016; 122: 10-16.
- [24] Tabrizi R, Özkan BT, Dehgani A, Langner NJ. Marsupialization as a treatment option for the odontogenic keratocyst. *J Craniofac Surg.* 2012; 23: e459-e461.
- [25] Güler N, Sençift K, Demirkol O. Conservative management of keratocystic odontogenic tumors of jaws. *ScientificWorldJournal.* 2012; 2012: 680397.
- [26] Rossi D, Borgonovo AE, Vavassori V, Poli PP, Santoro F. Combined treatment of odontogenic keratocysts: initial marsupialization and successiveenucleation with peripheral ostectomy plus Carnoy's solution application. A five-year follow-up experience. *Minerva Stomatol.* 2012; 61: 101-112.
- [27] Zecha JA, Mendes RA, Lindeboom VB, van der Waal I. Recurrence rate of keratocystic odontogenic tumor after conservative surgical treatment without adjunctive therapies - A 35-year single institution experience. *Oral Oncol.* 2010; 46: 740-742.
- [28] Matijević S, Damjanović Z, Lazić Z, Gardašević M, Radenović-đurić D. Peripheral ostectomy with the use of Carnoy's solution as a rational surgical approach to odontogenic keratocyst: a case report with 5-year follow-up. *Vojnosanit Pregl.* 2012; 69: 1101-1105.
- [29] Madras J, Lapointe H. Keratocystic odontogenic tumour: reclassification of the odontogenic keratocyst from cyst to tumour. *J Can Dent Assoc.* 2008; 74: 165.
- [30] Habibi A, Saghravani N, Habibi M, Mellati E, Habibi M. Keratocystic odontogenic tumor: a 10-year retrospective study of 83 cases in an Iranian population. *Journal of oral science.* 2007; 49: 229-235.
- [31] Nakamura N, Mitsuyasu T, Mitsuyasu Y, Taketomi T, Higuchi Y, Ohishi M. Marsupialization for odontogenic keratocysts: long-term follow-up analysis of the effects and changes in growth characteristics. *Oral Surg Oral Med Oral Pathol Oral Radiol Endod.* 2002; 94: 543-553.
- [32] Marker P, Brøndum N, Clausen PP, Bastian HL. Treatment of large odontogenic keratocysts by decompression and later cystectomy: a long-term follow-up and a histologic study of 23 cases. *Oral Surg Oral Med Oral Pathol Oral Radiol Endod.* 1996; 82: 122-131.
- [33] Brøndum N, Jensen VJ. Recurrence of keratocysts and decompression treatment. *Oral Surg Oral Med Oral Pathol.* 1991; 72: 265-269.
- [34] Tolstunov L, Treasure T. Surgical treatment algorithm for odontogenic keratocyst: combined treatment of odontogenic keratocyst and mandibular defect with marsupialization, enucleation, iliac crest bone graft, and dental implants. *J Oral Maxillofac Surg.* 2008; 66: 1025-1036.
- [35] Zhao YF, Wei JX, Wang SP. Treatment of odontogenic keratocysts: a follow-up of 255 Chinese patients. *Oral Surg Oral Med Oral Pathol Oral Radiol Endod.* 2002; 94: 151-156.
- [36] Jung YS, Lee SH, Park HS. Decompression of large odontogenic keratocysts of the mandible. *J Oral Maxillofac Surg.* 2005; 63: 267-271.
- [37] August M, Faquin WC, Troulis MJ, Kaban LB. Dedifferentiation of odontogenic keratocyst epithelium after cyst decompression. *J Oral Maxillofac Surg.* 2003; 61: 678-683.
- [38] Sánchez-Burgos R, González-Martín-Moro J, Pérez-Fernández E, Burgueño-García M. Clinical, radiological and therapeutic features of keratocystic odontogenic tumours: a study over a decade. *J Clin Exp Dent.* 2014; 6: e259-e264.

- [39] Morgan TA, Burton CC, Qian F. A retrospective review of treatment of the odontogenic keratocyst. *J Oral Maxillofac Surg.* 2005; 63: 635-639.
- [40] Al-Moraissi EA, Dahan AA, Alwadeai MS, Oginni FO, Al-Jamali JM, Alkhatari AS, et al. What surgical treatment has the lowest recurrence rate following the management of keratocystic odontogenic tumor? A large systematic review and meta-analysis. *J Craniomaxillofac Surg.* 2017; 45: 131-144.
- [41] Zhao Y, Liu B, Han QB, Wang SP, Wang YN. Changes in bone density and cyst volume after marsupialization of mandibular odontogenic keratocysts (keratocystic odontogenic tumors). *J Oral Maxillofac Surg.* 2011; 69: 1361-1366.