

Eosinophilic Granuloma: Report of a Misconstrued Case

Rezvani G.^a, Deghani Nazhvani A.^b

^a Dept. of Oral & Maxillofacial Pathology, School of Dentistry, Shahed University of Medical Sciences, Tehran, Iran

^b Dept. of Oral & Maxillofacial Pathology, School of Dentistry, Shiraz University of Medical Sciences, Shiraz, Iran

KEY WORDS

Histiocytosis;
Eosinophilic Granuloma;
Aggressive Periodontitis;
Case Report

Received Jan. 2012;
Received in revised form July 2012 ;
Accepted Oct. 2012.

ABSTRACT

Eosinophilic granuloma (EG) is the mildest and localized form of a group of diseases named Histiocytosis X. It is a destructive osseous lesion characterized by presence of a vast number of eosinophils and histiocytes. It has a neoplastic nature especially in the chronic forms. Based on the site of the lesion, three types are elucidated: 1- intraosseous 2- alveolar 3- mixed. In the last two types, extensive alveolar involvement and loosening of the teeth clinically may resemble aggressive periodontitis (AP). We report a case of EG which was initially diagnosed and treated as AP. The rapid progress, diagnostic problems, etiologic factors and the consequences of late diagnosis and treatment of eosinophilic granuloma are discussed. This explicates why dentists need to know the differential diagnosis of EG with AP for early diagnosis and treatment.

Corresponding Author: Deghani Nazhvani A., Dept. of Oral & Maxillofacial Pathology, School of Dentistry, Shiraz University of Medical Sciences, Shiraz, Iran Tel: +98-0711-6263193-4 Email: alideghaninazhvani@yahoo.com

Cite this article as: Rezvani G., Deghani Nazhvani A. Eosinophilic Granuloma: Report of a Misconstrued Case. *Journal of Dentistry Shiraz University of Medical Sciences* 2012; 13(4): 181-183.

Introduction

Eosinophilic granuloma (EG) is the mildest and localized form of Langerhans' cell diseases formerly called Histiocytosis X [1]. The term was introduced as a collective designation for a spectrum of clinicopathological disorders characterized by proliferation of histiocyte-like cells accompanied by varying numbers of eosinophils, plasma cells and multinucleated giant cells. Monostotic or polyostotic eosinophilic granuloma of bone is a solitary or multiple bone lesions without visceral involvement [2] and it may occur over a wide age range but more than 50% of all cases are seen in 1st and 2nd decade of life. The jaws are affected in 10% to 20% of all cases. Dull pain and tenderness often accompany bone lesions. Radiographically, the lesions often appear as punched out radiolucencies without a corticated rim. Bone involvement in the mandible usually occurs in the posterior areas and a characteristic "scooped out" appearance may be evident when the superficial alveolar bone is destroyed (alveolar and mixed types of the lesion). Extensive alveolar involvement may result in "floating in air" appearance of teeth [2-3]. Thus tooth mobility and deep periodontal pockets may be found. Ulcerative or proliferative mucosal lesions with erythema and severe bleeding tendency on probing may

develop if the disease breaks out of the bone. These clinical and radiographic features resemble severe aggressive periodontitis (AP), which can be ruled out by appropriate laboratory tests and histopathological evaluation. We report a case of EG which initially was diagnosed and treated as AP.

Case Report

An 18 year old man, with the chief complaint of ulcer and pain on buccal and lingual gingiva of his upper left premolars and first molar, was diagnosed as aggressive periodontitis in the Periodontology Department of Shiraz Dental School (Figure 1).

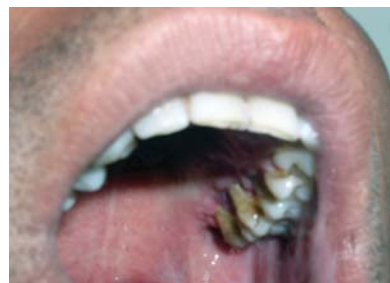

Figure 1 Gingival recession in palatal aspect of left upper premolars and molars

He had severe inflammation and gingival recession with focal areas of plaque and calculus not

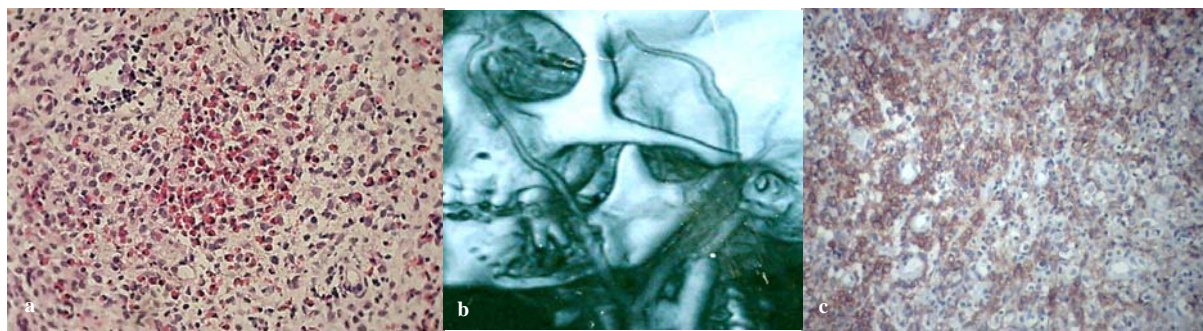


Figure 2a Diffuse infiltration of pale-stained Langerhans cells intermixed with numerous eosinophils (X400, H&E staining), **b** Reconstructed 3D CT scan view showing left mandibular molar hanging in air, **c** Positive immunostaining for CD1a marker (X400),

corresponding to the amount of recession. Vertical and horizontal bone loss in the region was detected in periapical radiographs. He had a positive history of alcohol consumption, smoking, sleep problems and severe fatigue since two years ago. These factors probably contributed to the pain and ulcer and made him visit a periodontologist after three weeks. He underwent routine periodontal treatment (scaling and root planning) and periodontal surgery was recommended and planned for him. An incisional biopsy was taken from the buccal gingiva of upper left first premolar under local anaesthesia and sent to the oral pathology department of Shiraz Dental School for final diagnosis. Histological sections showed sheets of oval cells with plump coffee-seed shaped nuclei and vast cytoplasm, mixed with large numbers of eosinophils which lead to the diagnosis of Histiocytosis X (Figure 2a). Then the patient was sent for total body scan and evaluation of his skeleton, but the patient declined due to the temporary healing of his lesion. During the last two years, the patient has experienced periods of progression and remissions, but not full recovery. He encountered similar lesions in the posterior area of all jaw quadrants and underwent extraction of all his posterior teeth and also canines since severe bone loss and consequent severe mobility made them hopeless (Figure 2b). Curettage was introduced and samples of soft and hard tissue from the deep tissues were sent for histopathological evaluation. Soft tissue samples showed the histopathological features of eosinophilic granuloma which was approved by S100 and CD1a positive immunohistochemical staining (Figure 2c). Hard tissue samples taken from the treated tooth sockets illustrated only a reactive bone; hence the final diagnosis was soft tissue eosinophilic granuloma. Para-clinical evaluations like Complete Blood Cell counts (CBC) and total body scan was requested and checked.

The results were in normal range and no involvements of other bones were detected. Extraction of the involved teeth with an accurate curettage was performed. This provided a good healing result for the patient so that he was referred for prosthetic procedures afterwards. The patient has been followed up every 4 months for one year and no recurrence has been notified.

Discussion

The term eosinophilic granuloma was first introduced in 1940 by Lichtenstein and Jaffee. Oral lesions in EG may simulate periodontitis or periapical infections and may be early or in many cases the only manifestation of the disease [1, 4]. Silvestros et al. reported a case of EG which periodontal problem was the first displayed oral manifestation [1] and Vandana et al. described a patient with periodontitis-like lesions which made diagnostic challenges with eosinophilic granuloma [5]. EG usually occurs as a solitary radiolucency in radiological images although some cases with bilateral or multifocal involvement mimicking advanced periodontal disease have been described. Rapid progressive periodontitis, now usually classified as generalized aggressive periodontitis or early onset periodontitis is clinically characterized by episodic, generalized emergence of severe and rapid bone destruction without any consistent pattern [6]. Eosinophilic granuloma may occasionally be misdiagnosed and treated as a periodontal condition, similar to the present case [1, 6-7].

Interestingly, periodontitis-like lesions in eosinophilic granuloma may indeed respond partially to scaling, root planning and subgingival curettage, but this treatment approach is considered improper [8- 9]. Ulcerations in oral mucosa may be present less frequently, as solitary EG lesions of the oral mucosa are extremely rare [9]. Regarding the previously reported cases, gingi-

val recession intermixed with loosening of the teeth were the first clinical manifestation of the disease [1, 7]. The case presented by Rapp et al. had high-grade tooth mobility and floating teeth in the radiographic views [7], and the case reported by Zaghbani et al. showed similar periodontal dilemma [6] which masked the actual origin of oral lesions spotted in all cases.

We should also consider the lesions such as multiple myeloma, metastasis and osteomyelitis in differential diagnosis of EG. It is believed that all these lesions should undergo biopsy to establish an accurate diagnosis. Concurrent with biopsy, the soft gray material which occupies the area of bone destruction should be curetted which might cause regression of the lesion (2, 9). Unfortunately some patients may avoid continuing necessary relative treatments after this regression as it happened in our case.

Although the exact aetiology of EG is still unknown and its literal pathogenesis remains obscure, immunologic disorders may result in the proliferation of Langerhans cells which are normal components of mucosa and skin and are considered as the origin of the disease [3]. Viruses also have been implicated with the loss of host immunity control [10]. In addition it has been suggested that the disease could result from exuberant reaction to an unknown antigenic factor [3-4]. In this case the patient's history of smoking, alcohol consumption, sleep problem and severe fatigue was related to the worsening of the ulcers, deep and severe pain in the bones and exacerbation of the patient's condition. We may believe that these are associate- factors which have impinged on host defence and subsequently led to the weakness of the immune system.

Eosinophilic granuloma has a neoplastic nature, specially the chronic forms, but the notion for a complete recovery is excellent. A few cases may progress into the more serious and chronic form: Hand-Schüller-Christian disease [6, 8]. However, the neoplastic nature of EG, substantial morbidity of the chronic form and the consequences of the late diagnosis and treatment, particularly at young ages and in severe conditions, imposes the dentists to know the diagnostic criteria and differential diagnosis of EG with AP for early diagnosis and treatment.

Complementary work-ups such as taking biopsies should be performed as soon as possible when a young

patient is appointed with rapid tooth mobility featured with floating tooth in radiographs, gingival recession or bleeding especially in molar areas with no apparent severe plaque or calculus and no or little response to first phase of periodontal treatments.

Acknowledgment

We should thank Dr. Shirvani for his kind helps in making biopsies. The study was self-funded by the authors and their institution.

References

- [1] Silvestros SS, Mamalis AA, Sklavounou AD, Tzerbos FX, Rontogianni DD. Eosinophilic granuloma masquerading as aggressive periodontitis. *J Periodontol* 2006; 77: 917-921.
- [2] Neville BW, Damm DD, Allen CM, Bouquot JE. *Oral and maxillofacial pathology*. 3rd ed., Missouri: Saunders Elsevier; 2009. p. 590-592.
- [3] Regezi JA, Scuibba JJ, Jordan RCK. *Oral pathology: Clinical pathologic correlations*. 5th ed., Missouri: Saunders Elsevier; 2008. p. 296-299.
- [4] Diniz Freitas M, Madriñán Graña P, Antúnez López J, Gándara Vila P, Gándara Rey JM, García García A. Eosinophilic granuloma as a form of inflammatory reaction. A case report. *Med Oral* 2001; 6: 95-100.
- [5] Vandana KL, Desai R, Banupurmamath CR, Kartik M. Eosinophilic granuloma with oral manifestations: a case report. *J Indian Soc Pedod Prev Dent* 2003; 21: 105-107.
- [6] Zaghbani A, Ben-Youssef Boudegga S, Gharbi O, et al. Eosinophilic granuloma or aggressive periodontitis? *Rev Stomatol Chir Maxillofac* 2010; 111: 49-52.
- [7] Rapp GE, Motta AC. Periodontal disease associated with Langerhans' cell histiocytosis: case report. *Braz Dent J* 2000; 11: 59-66.
- [8] Key SJ, O'Brien CJ, Silvester KC, Crean SJ. Eosinophilic granuloma: resolution of maxillofacial bony lesions following minimal intervention. Report of three cases and a review of the literature. *J Craniomaxillofac Surg* 2004; 32: 170-175.
- [9] Chkoura A, El Alloussi M, Taleb B, El Wady W. Resolution of eosinophilic granuloma after minimal intervention. Case report and review of literature. *N Y State Dent J* 2010; 76: 43-36.
- [10] Wood NK, Goaz PW. *Differential diagnosis of oral and maxillofacial lesions*. 5th ed., Missouri: Mosby 1997; p. 386-389.