

Original Article

## Comparison between Glenoid Fossa Roof Thickness in TMD and non-TMD Patients, a CBCT Study

Leila Khojastepour, DMD, MSc<sup>1</sup> - Abdolaziz Haghnegahdar, DMD, MSc<sup>1</sup> - Maryam Eisazadeh, DMD, MSc<sup>2</sup>, Mahboobeh Bahreini, DMD<sup>3</sup>

<sup>1</sup> Dept. of Oral and Maxillofacial Radiology, School of Dentistry, Shiraz University of Medical Sciences, Shiraz, Iran.

<sup>2</sup> Postgraduate Student, Dept. of Oral and Maxillofacial Radiology, School of Dentistry, Shiraz University of Medical Sciences, Shiraz, Iran.

<sup>3</sup> Student Research Committee, School of Dentistry, Shiraz University of Medical Sciences, Shiraz, Iran.

### KEY WORDS

Roof of glenoid fossa;  
Cone beam computed tomography;  
Temporomandibular joint;  
Temporomandibular joint disorder;

Received: April 2018;  
Revised: June 2018;  
Accepted: July 2018;

### ABSTRACT

**Statement of the Problem:** Various pathologic conditions can affect the thickness of the roof of glenoid fossa (RGF). The relationship between the RGF thickness and temporomandibular joint disorder (TMD) is not explicitly investigated. Considering the changes in RGF thickness, as a radiographic sign for TMD diagnosis, the phenomenon may necessitate specific treatment and may influence the treatment course and results.

**Purpose:** This research was designed to examine the relationship between TMD and RGF thickness changes compared to non-TMD group.

**Materials and Method:** In this cross sectional analytic research CBCT images of 70 TMD patients (140 joints) and 70 non-TMD individuals (140 joints) as control group were evaluated for thickness of RGF and presence of discontinuity in RGF. The distance between superior and inferior cortex of glenoid fossa was measured as RGF thickness. Inability to follow the course of cortex in any given image was considered as discontinuity. T-test, Chi-square and odds ratio (OR) were used for statistical analysis. In this study,  $p < 0.05$  was considered meaningful.

**Results:** The mean thickness of RGF in our non-TMD samples was 1.12 mm. RGF thickness was significantly increased in TMD patients compared non-TMD group ( $p = 0.00$ ). This value was also greater in males. On the other hand, TMD patient showed a higher incidence of discontinuity in RGF, in comparison with non-TMD patients ( $p = 0.006$ ).

**Conclusion:** the increased thickness of RGF can be considered as a sign of TMD, which may help in diagnosis of TMD. It seems that there is a direct relationship between TMD and discontinuity of RGF.

**Corresponding Author:** Eisazadeh M, Dept. of Oral and Maxillofacial Radiology, School of Dentistry, Shiraz University of Medical Sciences, Shiraz, Iran. Tel: +98-7136263193-4  
Email: issazadeh.mari@gmail.com

**Cite this article as:** Khojastepour L, Haghnegahdar A, Eisazadeh M, Bahreini M. Comparison between Glenoid Fossa Roof Thickness in TMD and non-TMD Patients, a CBCT Study. J Dent Shiraz Univ Med Sci. 2019; 20(3): 165-170.

### Introduction

Temporomandibular joint dysfunction (TMD) is one of the most common causes of orofacial pain, demonstrating variable clinical signs and symptoms such as pain, clicking, popping, limited opening, mandibular deviation on opening and closing, muscle tenderness, headaches, earaches, malocclusions, neck pain and

stiffness [1]. Since TMDs are frequently categorized as chronic pain, therefore, it is necessary to manage them properly, so more advanced methods for exact and prompt diagnosis and treatment are needed [2]. Some studies have evaluated relationship between TMD and anatomic indices such as height and inclination of the articular eminence, glenoid fossa shape and depth,

condyle morphology, and disk space width [3-5]. Also, some studies have evaluated the relationship between thickness of RGF changes and age, gender, condyle morphology and remaining teeth in asymptomatic patient in computed tomography (CT) or cone beam computed tomography (CBCT) images [6-7].

The roof of glenoid fossa (RGF) is a thin plate of temporal bone located between the temporomandibular joint (TMJ) components and middle cranial fossa. For the thickness of the RGF, variable values are reported in a range of 0.2 to 0.4 mm in asymptomatic patients, although some pathologic conditions can change it [8]. Honda *et al.* [6] reported the RGF thickness in normal TMJs is not related to age or gender; however, there is an association between thickness of the RGF and perforation of the disk or posterior attachment [9-10]. Increase in thickness of the RGF in symptomatic patients [11-13] and patients with osteoarthritis has been reported [9]. Moreover, recently a case of apparent discontinuity (as the author stated) in RGF in an asymptomatic patient has been reported [8], but until now, discontinuity of RGF has not been studied in TMD patients. According to some studies, minimum thickness of RGF might be related to some complications such as dislocation of mandibular condyle into cranial fossa following facial trauma and intracranial extension of tumors, therefore, these observations highlight the need for more detailed research on the thickness of RGF and its probable relationship with TMD [14-15]. In case of finding a relationship between bone changes and TMD symptoms, it might be possible to use the thickness of the RGF as an auxiliary indicator for TMJ health condition.

The purpose of the current investigation was to compare changes in the thickness of RGF between TMD and non-TMD patients. Additionally, the prevalence of discontinuity in the RGF was compared between two groups.

### Materials and Method

This study protocol was approved by the institutional Ethical Committee of the Shiraz Dental School. All participants were divided into two groups of TMD and non-TMD patients, based on Helkimo clinical dysfunction index [16], proposed by Helkimo in 1974. Participants were clinically evaluated using Helkimo

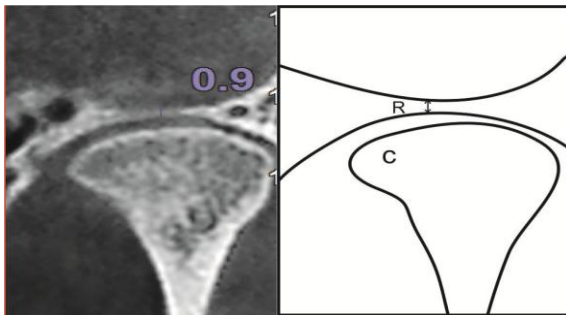
clinical index to be categorized in two groups of non-TMD and TMD patients. Based on the main indications, such as structural assessment of bony components failure to respond to the previous usual treatment for the joint and presence of clinical findings indicating a progressive pathological status in the joint [17-19], patients were referred for CBCT examinations. The subjects of this study consisted of CBCT images of 70 patients (55 women and 15 men) with clinical signs and symptoms of TMD lasting at least for two years. The patients' age ranged from 18 to 65 years. The CBCT images and clinical records of another group of 70 patients (47 women and 23 men aged 18 to 65 years) who sought treatment for purposes other than TMD, such as paranasal sinuses examinations, were used as control. The nature of investigation was completely explained, and a written consent form was taken from each of the subjects enrolled in the study. The age and gender distribution of the patients in the non-TMD group were similar to those of the patients in the TMD group. Inclusion criteria for the non-TMD group were no pain affecting the TMJ area or muscles of mastication, no joint sounds, and no limitation of movement or function in the TMJs (Helkimo clinical Di=0). The exclusion criteria for the TMD and non-TMD groups included either one or all of the following: a positive history of temporomandibular surgery or acute trauma, the presence of congenital abnormalities, musculoskeletal or neurologic disorders, and any systemic diseases that could affect joint morphology. CBCT examination was performed for all of the patients using a NewTom VGi scanner (NewTom, Verona, Italy), field of view size (15×12cm), with the exposure parameters set at 120 KVp, 4.8 mA, and exposure time of 20s in the standard resolution mode (voxel size 0.3 mm). The NewTom Cone Beam 3D Imaging System workstation (NNT Software version 7) was used to prepare the TMJ images. Images of the central region of the mandibular fossa in coronal sections were used for the study measurements. Corrected frontal section images show the lateral edge of the mandibular fossa. The central equivalent region, defined as the thinnest area of the glenoid fossa, was identified through multiple slices on the monitor using a 3DX image program for making the measurements. The distance measurement tool, as a part of the 3DX soft

ware, was employed for measuring distances on the 3DX images. The distance between inferior and superior cortex of RGF was registered as the thickness of RGF. Moreover, the discontinuity was considered for a case only when the interruption of RGF in frontal views was double confirmed in sagittal sections (Figures 1 and 2). The linear measurements were made two times on the monitor by two separate investigators expert in interpretation of CBCT TMJ images. The observers independently assessed the images with a minimum interval of 14 days. The right and left TMJ areas of each patient were evaluated separately.

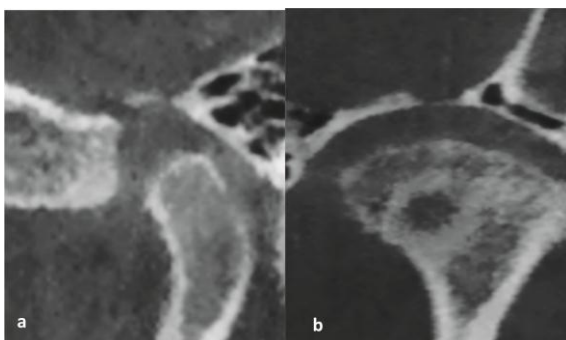
Statistical analysis was performed using SPSS software, version 18.0 (SPSS Inc, Chicago, IL). T-test was used to compare the thickness of the RGF in TMD and non-TMD groups. Chi-square test was used to assess the relationship between apparent discontinuity prevalence and TMD. In addition, odds ratio (OR) was calculated to determine the incidence of apparent discontinuity in TMD patients.

### Results

The distribution of age and gender among participants is presented in Table 1. The correlation of thickness of RGF and TMD is shown in Table 2. According to our



**Figure 1:** Measurement of RGF(R) in corrected frontal section, which demarcates the distance between inferior cortex and the superior one



**Figure 2a:** Discontinuity of RGF in corrected frontal view, **b:** confirmed in corrected sagittal view

**Table 1:** Age and gender distribution

Variable	Group		p Value
	TMD (n=70)	Non-TMD (n=70)	
Age	32.66±12.50	35.67±10.75	0.128
Gender	F 55 (78.6)	47 (67.1)	0.128
	M 15 (21.4)	23 (32.9)	

Age was described using mean±SD and gender was described using frequency (%)

**Table 2:** Comparison between RGF thickness in TMD and non-TMD patients

	RGF thickness [mean(mm)±SD]	p Value
TMD patient (GF=140)	1.91±1.47	0.00*
Non-TMD patient (GF=140)	1.12±0.69	

\* Data were analyzed by t-test, Significant differences: p Value <0.05

study, thickness of RGF significantly increases in TMD patients compared to non-TMD group ( $p < 0.05$ ). This value was also greater in male in non-TMD patients (Table 3). The relationship between prevalence of apparent discontinuity and TMD was also evaluated (Table 4).

### Discussion

CBCT is a reliable and accurate modality to find TMJ bone changes. Likewise, due to high exposure, multi-detector CT is better not to be applied to TMJ diagnosis [8]. Previous researches evaluated bone changes in condyle and articular eminence in TMD patients [3-5]. Thus, the current research focused on glenoid fossa changes.

**Table 3:** Comparison between RGF thickness in TMD and non-TMD patients according to gender

	RGF thickness (mean±SD)		p Value
	Male	Female	
TMD (55 female, 15 male)	2.52±2.21	1.75±1.18	0.01
Non TMD (47 female, 23 male)	1.23±1.01	1.07±0.47	0.34

Data were analyzed by t-test, Significant differences: p Value <0.05

**Table 4:** Association between TMD and apparent discontinuity

Apparent discontinuity	Group		OR (95% CI)	p Value
	TMD (n=140)	Non TMD (n=140)		
Yes	12(8.6)	2(1.4)	6.47(1.45-29.40)	0.006
No	128(91.4)	138 (98.6)		

Data were analyzed by Chi-square and OR index, significant differences: p Value<0.05  
The values in the table are frequency (and %)

Some researchers studied the relationship between glenoid fossa changes and age, remaining tooth, condyle type and morphology, which most of them were done in asymptomatic patients and a few studies evaluated these items in patients with TMD symptoms [11-13]. In addition, the prevalence of discontinuity in RGF, was compared between TMD and non-TMD cases.

Ejima *et al.* [7] reported that condyle morphological changes in coronal aspect and showed no influence on thickness of RGF; though they reported condyle osteoarthritis changes (morphology in sagittal aspect) increased the thickness of RGF. Since we study all types of TMD patients including osteoarthritic, it can be accepted that the increase in thickness of RGF is not restricted to osteoarthritic patients. Evidently, for achieving more reliable results, further evaluations with larger sample sizes are needed.

Matsumoto *et al.* [13] measured minimum thickness of RGF by using CBCT, in osteoarthritic patients who showed joint effusion and disk displacement in MRI examinations. They concluded that increasing of thickness of RGF is significant only in patients with joint effusion. While, Tsuruta *et al.* [12] stated that thickness increase is related to erosive changes.

Some other studies also reported thickness increase in case of TMD symptoms or osteoarthritis in RGF [11, 13]. This increase in thickness may be in response to the increased mechanical stress applied to the TMJ, which led to compose compensated bone in RGF, to help maintain consistency [7].

Despite that in most TMD patients, the thickness of RGF has increased; significantly, higher prevalence of discontinuity of RGF was detected in TMD patients. This is the novel part of our study, which has not been reported before. We believe that discontinuity in the RGF should promote physicians to evaluate patients for TMD sign and symptoms. Thus, finding a relationship between discontinuity prevalence increase and TMD symptoms is useful to diagnose of the disease, in time. This phenomenon may also necessitate treatment that is more sophisticated.

It must be mentioned that, observing discontinuity in CBCT studies may result from larger voxel size (0.3), since bone thickness lower than this, or non-ossified bone is invisible. In our study, CBCT data voxel size is 0.3mm. Thus, similar to Alorainy *et al.*

[8] case study, using the term “apparent discontinuity” is more reasonable. They reported a case of discontinuity in RGF in study of CBCT in an asymptomatic person, but the MRI findings confirmed a thin bone layer in RGF of the individuals. In our research, the prevalence of discontinuity was studied in both groups.

Clinical significance of very thin RGF is not completely known, but the risk of condyle displacement into cranial fossa in case of trauma should be considered, although the displacement into middle cranial fossa is rare [14, 20-21]. The factors that increase the risk of displacement into cranial fossa include round condyle, increased pneumatization of the temporal bone, and lack of posterior dentition [14, 21]. It must be considered that infection can spread into the cranial fossa through the glenoid fossa subsequent to ear infections. In addition, malignant otitis externa might spread to the TMJ via penetration of the infection through the capsule of the joint, or as osteomyelitis of the skull base involving the glenoid fossa [22-23].

Indeed, further investigations with larger sample size are needed to confirm or refute the results of the present investigation. It would also be a good idea to do more studies in TMD patients with discontinuity of the RGF by MRI imaging. This study was subjected to some limitations such as limited number of cases, and lack of recognizing the patient based on duration and severity of the disease.

## Conclusion

According to the results of this study, the thickness of the RGF increases in TMD patients significantly. TMD patients also show a meaningful higher incidence of apparent discontinuity in RGF in CBCT images.

## Acknowledgements

The authors thank the Shiraz University of Medical Sciences, for supporting this research. This manuscript has been extracted from the Thesis of Dr. Maryam Eisazadeh, which was conducted under the supervision of Dr. Leila Khojastepour and the advisory of Dr. Abdolaziz Haghnegahdar. The authors would also like to express gratitude to Dr. Mehrdad Vossoughi from Dental Research Development Center at Shiraz School of Dentistry for the statistical analysis.

### Conflict of Interest

Leila Khojastepour, Abdolaziz Haghnegahdar, Maryam Eisazadeh declare that they have no conflict of interest.

### References

- [1] De Leeuw R, Klasser GD. Orofacial pain: guidelines for assessment, diagnosis, and management. *Am J Orthod Dentofacial Orthop.* 2008; 134: 171.
- [2] Barros Vde M, Seraidarian PI, Côrtes MI, de Paula LV. The impact of orofacial pain on the quality of life of patients with temporomandibular disorder. *J Orofac Pain.* 2009; 23: 28-37.
- [3] Paknahad M, Shahidi S, Akhlaghian M, Abolvardi M. Is Mandibular Fossa Morphology and Articular Eminence Inclination Associated with Temporomandibular Dysfunction? *J Dent (Shiraz).* 2016; 17: 134-141.
- [4] Sümbüllü MA, Çağlayan F, Akgül HM, Yılmaz AB. Radiological examination of the articular eminence morphology using cone beam CT. *Dentomaxillofac Radiol.* 2012; 41: 234-240.
- [5] Çağlayan F, Sümbüllü MA, Akgül HM. Associations between the articular eminence inclination and condylar bone changes, condylar movements, and condyle and fossa shapes. *Oral Radiology.* 2014; 30: 84-91.
- [6] Honda K, Kawashima S, Kashima M, Sawada K, Shinoda K, Sugisaki M. Relationship between sex, age, and the minimum thickness of the roof of the glenoid fossa in normal temporomandibular joints. *Clin Anat.* 2005; 18: 23-26.
- [7] Ejima K, Schulze D, Stippig A, Matsumoto K, Rottke D, Honda K. Relationship between the thickness of the roof of glenoid fossa, condyle morphology and remaining teeth in asymptomatic European patients based on cone beam CT data sets. *Dentomaxillofac Radiol.* 2013; 42: 90929410.
- [8] Alorainy IA. Apparent discontinuity of the roof of the glenoid fossa on cone-beam computed tomography images of an asymptomatic temporomandibular joint. *Oral Radiology.* 2016; 32: 61-65.
- [9] Honda K, Larheim TA, Sano T, Hashimoto K, Shinoda K, Westesson PL. Thickening of the glenoid fossa in osteoarthritis of the temporomandibular joint. An autopsy study. *Dentomaxillofac Radiol.* 2001; 30: 10-13.
- [10] Honda K, Larheim TA, Bjornland T, Westesson PL. Increased thickness of the roof of the glenoid fossa 10 years after discectomy of the temporomandibular joint. In: Fuchihata H, editor. *Oral and maxillofacial radiology today.* 1th ed. Amsterdam: Elsevier; 2000. p. 527-530.
- [11] Kijima N, Honda K, Kuroki Y, Sakabe J, Ejima K, Nakajima I. Relationship between patient characteristics, mandibular head morphology and thickness of the roof of the glenoid fossa in symptomatic temporomandibular joints. *Dentomaxillofac Radiol.* 2007; 36: 277-281.
- [12] Tsuruta A, Yamada K, Hanada K, Hosogai A, Tanaka R, Koyama J, et al. Thickness of the roof of the glenoid fossa and condylar bone change: a CT study. *Dentomaxillofac Radiol.* 2003; 32: 217-221.
- [13] Matsumoto K, Honda K, Sawada K, Tomita T, Araki M, Kakehashi Y. The thickness of the roof of the glenoid fossa in the temporomandibular joint: relationship to the MRI findings. *Dentomaxillofac Radiol.* 2006; 35: 357-364.
- [14] Barron RP, Kainulainen VT, Gusenbauer AW, Hollenberg R, Sándor GK. Management of traumatic dislocation of the mandibular condyle into the middle cranial fossa. *J Can Dent Assoc.* 2002; 68: 676-680.
- [15] Kai Y, Matsumoto K, Ejima K, Araki M, Yonehara Y, Honda K. Evaluation of the usefulness of magnetic resonance imaging in the assessment of the thickness of the roof of the glenoid fossa of the temporomandibular joint. *Oral Surg Oral Med Oral Pathol Oral Radiol Endod.* 2011; 112: 508-514.
- [16] Helkimo M. Studies on function and dysfunction of the masticatory system. II. Index for anamnestic and clinical dysfunction and occlusal state. *Sven Tandlak Tidskr.* 1974; 67: 101-121.
- [17] Glick M. *Burket's Oral Medicine.* 12th ed. People's Medical Publishing: USA; 2015. p.289-290.
- [18] Ferreira LA, Grossmann E, Januzzi E, de Paula MV, Carvalho AC. Diagnosis of temporomandibular joint disorders: indication of imaging exams. *Braz J Otorhinolaryngol.* 2016; 82: 341-352.
- [19] Lewis EL, Dolwick MF, Abramowicz S, Reeder SL. Contemporary imaging of the temporomandibular joint. *Dent Clin North Am.* 2008; 52: 875-890.
- [20] Yale SH, Allison BD, Hauptfuehrer JD. An epidemiological assessment of mandibular condyle morphology. *Oral Surg Oral Med Oral Pathol.* 1966; 21: 169-177.
- [21] da Fonseca GD. Experimental study on fractures of the

- mandibular condylar process (mandibularcondylar process fractures). *Int J Oral Surg.* 1974; 3: 89-101.
- [22] Dobbyn L, O'Shea C, McLoughlin P. Malignant (invasive) otitis externa involving the temporomandibular joint. *J Laryngol Otol.* 2005; 119: 61-63.
- [23] Mardinger O, Rosen D, Minkow B, Tulzinsky Z, Ophir D, Hirshberg A. Temporomandibular joint involvement in malignant external otitis. *Oral Surg Oral Med Oral Pathol Oral Radiol Endod.* 2003; 96: 398-403.