

**Original Article**

## Comparison of Dental Panoramic Radiography and CBCT for Measuring Vertical Bone Height in Different Horizontal Locations of Posterior Mandibular Alveolar Process

Shoaleh Shahidi <sup>1</sup>, Barbad Zamiri <sup>2</sup>, Masoud Abolvardi <sup>3</sup>, Marzieh Akhlaghian <sup>4</sup>, Maryam Paknahad <sup>5</sup>

<sup>1</sup> Dept. of Oral and Maxillofacial Radiology, Biomaterials Research Center, School of Dentistry, Shiraz University of Medical Sciences, Shiraz, Iran.

<sup>2</sup> Dept. of Oral and Maxillofacial Surgery, School of Dentistry, Shiraz University of Medical Sciences, Shiraz, Iran.

<sup>3</sup> Postgraduate Student of Orthodontics, Dept. of Orthodontics, School of Dentistry, Hamadan University of Medical Sciences, Hamadan, Iran.

<sup>4</sup> Postgraduate Student of Prosthodontics, Dept. of Prosthodontics, School of Dentistry, Shiraz University of Medical Sciences, Shiraz, Iran.

<sup>5</sup> Oral and Dental Disease Research Center, Dept. of Oral and Maxillofacial Radiology, School of Dentistry, Shiraz University of Medical Sciences, Shiraz, Iran.

**KEY WORDS**

Dental panoramic radiograph;  
Cone-beam computed tomography;  
Dental implant;  
Available bone height;

**ABSTRACT**

**Statement of the Problem:** Accurate measurement of the available bone height is an essential step in the pre-surgical phase of dental implantation. Panoramic radiography is a unique technique in the pre-surgical phase of dental implantations because of its low cost, relatively low-dose, and availability.

**Purpose:** This article aimed to assess the reliability of dental panoramic radiographs in the accurate measurement of the vertical bone height with respect to the horizontal location of the alveolar crest.

**Materials and Method:** 132 cone-beam computed tomography (CBCT) of the edentulous mandibular molar area and dental panoramic radiograph of 508 patients were selected. Exclusion criteria were bone abnormalities and detectable ideal information on each modality. The alveolar ridge morphology was categorized into 7 types according to the relative horizontal location of the alveolar crest to the mandibular canal based on CBCT findings. The available bone height (ABH) was defined as the distance between the upper border of the mandibular canal and alveolar crest. One oral radiologist and one oral surgeon measured the available bone height twice on each modality with a 7-day interval.

**Results:** We found a significant correlation between dental panoramic radiographs and cone-beam computed tomography values (ICC=0.992,  $p < 0.001$ ). A positive correlation between the horizontal distance of the alveolar crest to the mandibular canal and measured differences between two radiographic modalities had been found ( $r=0.755$ ,  $p < 0.001$ ). For each single unit of increase in the horizontal distance of the alveolar crest to the mandibular canal, dental panoramic radiographs showed 0.87 unit of overestimation ( $p < 0.001$ ).

**Conclusion:** Dental panoramic radiographs can be employed safely in the pre-surgical phase of dental implantation in posterior alveolus of mandible, especially in routine and simple cases.

**Corresponding Author:** Abolvardi M., Dept. of Orthodontics, School of Dentistry, Hamadan University of Medical Sciences, Hamadan, Iran. Tel: +98-7136263193-4 Email: abolvardim@gmail.com

Received January 2017;  
Received in Revised form May 2017;  
Accepted July 2017 ;

**Cite this article as:** Shahidi Sh., Zamiri B., Abolvardi M., Akhlaghian M., Paknahad M. Comparison of Dental Panoramic Radiography and CBCT for Measuring Vertical Bone Height in Different Horizontal Locations of Posterior Mandibular Alveolar Process. J Dent Shiraz Univ Med Sci., 2018 June; 19(2): 83-91.

**Introduction**

Replacing missing teeth has always been an important

issue in dentistry. There are different choices to achieve this goal such as removable partial denture, fixed partial

denture, and dental implants. [1] Among them, dental implants have the highest long-term success rate reported to be up to 96.4%. [2-4] This high success rate contributes to improvements in the surface and design of dental implants, [5] different surgical approaches, [4, 6] and also advancements in radiologic techniques. [7-10] Accurate measurement of the alveolar bone height and thickness, and a safe margin from anatomic structures such as maxillary sinus, mental foramen, and inferior alveolar nerve canal are important factors in pre-surgical planning phase of dental implant placing. [11]

There are different methods of radiographic imaging to assess the candidate area of implant inserting including peri-apical, [12] dental panoramic radiography (DPR), [12-16] lateral cephalometry, [17] conventional tomography, [8, 12] computed tomography (CT), [8, 12, 18] and cone-beam computed tomography (CBCT). [5, 8, 19] Although the advanced imaging techniques (CT and CBCT) have many advantages such as cross-sectional information and multi-dimensional views, [20] DPR keeps its values in pre-surgical planning phase of dental implantation. [8, 20-24]

DPR displays the whole body of the mandible, most parts of the maxilla, and their internal structures such as mandibular canal and maxillary sinus on a single projection. [25] The length and the mesiodistal angulation of a dental implant are usually determined in DPR even though it has some limitations such as ghost image of the vertebra in the anterior part, positioning errors and magnification. [26] Moreover, DPR is easily available and is relatively inexpensive. Regarding its advantages, DPR is considered as the most common single radiographic examination used in dental implant treatment planning. [14]

The comparison of DPR with other non-tomographic techniques started in 2006 by Wakoh and colleagues who assessed the reliability of DPR and standardized peri-apical radiographs. [27] Their study suggested that standardized peri-apical radiographs were more accurate than DPR in linear distance measurement for dental implantation. Furthermore, a comparison between DPR and lateral cephalometry was done in 2007 by Beltrão and colleagues, [17] who concluded that lateral cephalographs could be a useful guide for maxillary dental implant-based reconstruction. [17] Later, CBCT as a technique of choice for precise

measurements, even on normal structures and jaw pathoses, was used in the field of dental implantation. [28-31] While some studies introduced DPR as a reliable technique for measurements of available bone height for dental implantation, [5, 8, 20-21, 32-33] others claimed that DPR could not provide reliable information and might lead to the failure of treatment. [5, 19, 22-23, 34-36] Therefore, we aimed to determine the reliability of DPR as a two-dimensional imaging method in measuring the precise vertical bone height by evaluating the horizontal location of the alveolar crest.

## Materials and Method

### Data acquisition

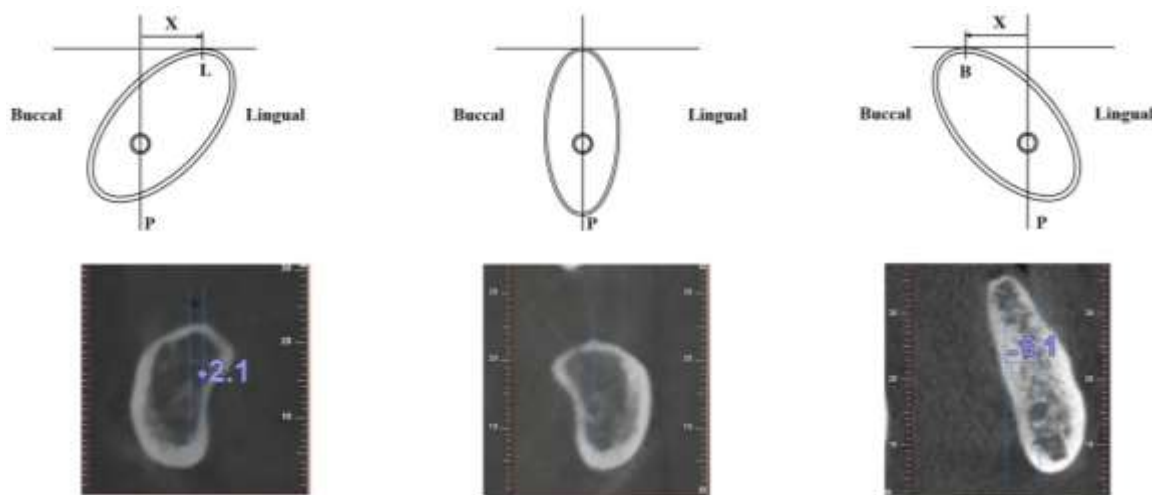
From the CBCT and DPR images of 508 (246 men, 262 women) candidates for dental implants in a private Oral and Maxillofacial Radiology Clinic in Shiraz, Southern Iran, from Feb. 2013 to Feb. 2014, 144 images of edentulous mandibular molar areas were recruited retrospectively.

The exclusion criteria comprised both patient and image related factors. The patient related factors involved any pathosis in the area of measurement, recent extraction sockets retained root, mental foramen on the level of the alveolar crest, history of confirmed osteoporosis, and any other uncontrolled systemic diseases. In the image related category, all images with undetectable superior cortex of the mandibular canal or indistinct crestal cortex of the alveolar process in DPR or those lacking the ideal quality in the CBCT were excluded.

DPRs in this study were taken with respect to the optimum situations, which were provided by the manufacturer. One machine for DPR (Planmeca cc-proline, Finland) and one CBCT machine (NewTom VGi) were used. A standardized protocol of the NewTom for the extended (12\*15 cm) field of view with 0.3mm slice thickness and 26.9 seconds acquisition time was used. All DPRs were taken using Konica CR receptor image plate (12×10 inch) and were displayed on the Fuji Computed Radiography system (Fuji Computed Radiography 5000R, Fuji Photo Film Co. Ltd., Dusseldorf, Germany).

### Alveolar bone shape classification

The alveolar ridge morphology was categorized into seven types according to the relative horizontal location of the peak of the alveolar crest to the mandibular canal



**Figure 1:** Seven types of location of the peak point of the alveolar crest according to the mandibular canal. B and L, peak point of the alveolar crest; P: Vertical line passing through the center of the mandibular canal and perpendicular to the lower border of each image. Type N:  $X=0$  Type B1:  $-2\text{mm} \leq X \leq 0$  Type B2:  $-4\text{mm} \leq X \leq -2\text{mm}$  Type B3:  $X < -4\text{mm}$   
 Type L1:  $0 < X \leq +2\text{mm}$  Type L2:  $+2\text{mm} < X \leq +4\text{mm}$  Type L3:  $X > +4\text{mm}$

on reformatted cross-sectional CBCT images (Figure 1).

Type N: the peak point of the alveolar crest was positioned in the center compared with the vertical line passing through the center of the mandibular canal and perpendicular to the lower border of each image.

Type B1: the peak point of the alveolar crest was positioned in the buccal side and the distance from the vertical line was less than 2mm.

Type B2: the peak point of the alveolar crest was positioned in the buccal side and the distance from the vertical line was greater than 2mm and less than 4mm.

Type B3: the peak point of the alveolar crest was positioned in the buccal side and the distance from the vertical line was greater than 4mm.

Type L1: the peak point of the alveolar crest was positioned in the lingual side and the distance from the vertical line was less than 2mm.

Type L2: the peak point of the alveolar crest was

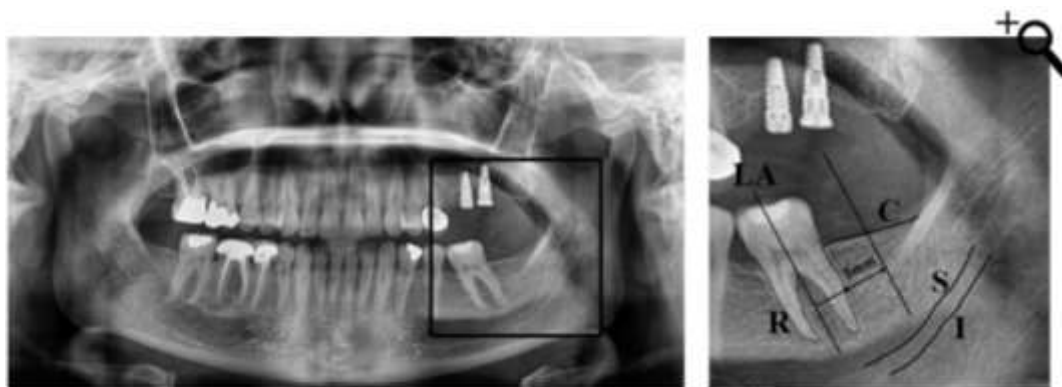
positioned in the lingual side and the distance from the vertical line was greater than 2mm and less than 4mm.

Type L3: the peak point of the alveolar crest was positioned in the lingual side and the distance from the vertical line was greater than 4mm.

**Measurement**

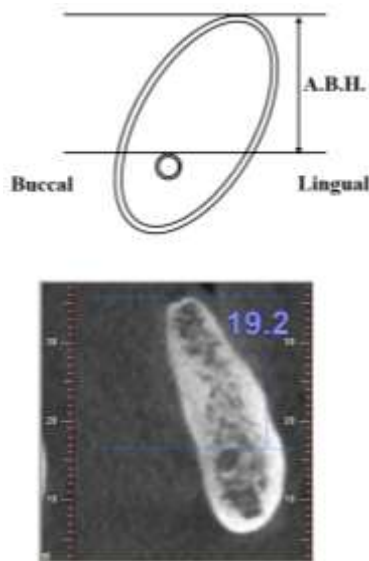
In order to match the sections in each modality, the cross-sections in CBCT were obtained perpendicular to the true horizontal plan and the DPR sections were obtained perpendicular to the lower border of each image which was parallel to the true horizontal plan in standard situations. The mesio-distal location of the first candidate site was defined to have 5mm distance from the nearest natural tooth or dental implant at the level of the alveolar crest and for the next sites, another 5mm was added to the previous distance (Figure 2).

The available bone height in CBCT views was defined as the distance between the line tangential to the



**Figure 2:** a: A DPR of a patient. b: Cropped image of Figure 2a, showing the producer of measuring the mesiodistal location of dental implant insertion site. C: alveolar crest; S: Superior border of mandibular canal; I: Inferior border of mandibular canal; LA: Long axis of the nearest tooth (or implant); R: Outer surface of the root of the nearest tooth (or implant)

upper border of the mandibular canal and the line tangential to the peak of the alveolar crest, which were both parallel to the lower border of reformatted cross-sectional CBCT images (Figure 3).



**Figure 3:** The ABH in CBCT was defined as the distance between the line tangential to the upper border of the mandibular canal and the line tangential to the peak of the alveolar crest, which were both parallel to the lower border of the image

The available bone height in DPR was measured as follows: a line was depicted from the most superior point of the alveolar crest perpendicular to the lower border of image. Then the distance between the alveolar crest and the superior border of the mandibular canal was measured (Figure 4).

The linear measurements and the angular measurements were performed using the CBCT software (M-view TM PS [Infinit, Seoul, republic of Korea]). The available bone height was measured twice on both imaging modalities with an interval of seven days and the differences were compared according to their types.

**Statistical analysis**

Data were analyzed using SPSS software, version 17.0 (SPSS, Chicago, IL). Intra-class correlation coefficient (ICC) was used to evaluate the agreement between values measured in DPR and CBCT. Pearson’s correlation(r) and linear regression were used to assess the relationship between the vertical available bone height measurements difference ( $\Delta$ ) of the two methods (DPR and CBCT) and the horizontal distance of the alveolar crest to the center of mandibular canal.

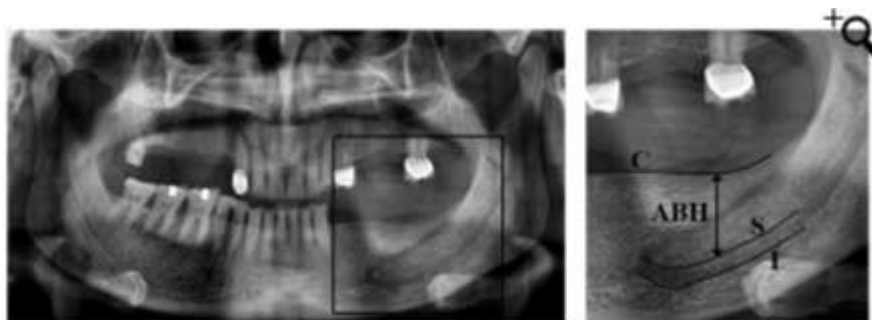
**Results**

All 508 CBCT and DPR images were assessed in this study, consisting of 109 cases for type L3, 92 cases for type L2, 83 cases for type L1, 13 cases for type N, 67 cases for type B1, 84 cases for type B2, and 60 cases for type B3 (Figure 5).

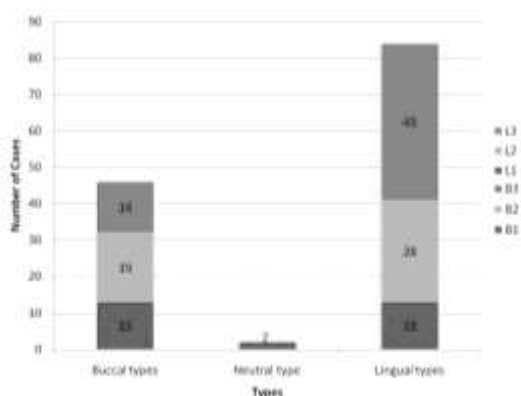
Of the selected 144 cases, 12 cases were excluded because of having recent extraction sockets or being a known case of osteoporosis. The other 132 cases were recruited in the study (response rate=91.6%). Of these 132 cases, the type L3 had the most frequent with 43 cases (32.57%) followed by type L2 (n=28, 21.21%), and type N (n=2, 1.51%) was the rarest and least frequent (Table 1).

**Table 1:** Descriptive characteristics of the studied cases (n=132)

Alveolar bone shape classification	Frequency (%)
L3	43(32.57)
L2	28(21.21)
L1	13(9.84)
N	2(1.51)
B1	13(9.84)
B2	19(14.40)
B3	14(10.6)
Total	132(100)



**Figure 4a:** A DPR of patient. **b:** Cropped image of Figure 4a, showing the producer of measure ABH in PDRs. C: Alveolar crest; S: Superior border of mandibular canal; I: inferior border of mandibular canal and ABH: The distance between C and S on the line which is perpendicular to the lower border of main image



**Figure 5:** Descriptive characteristics of the studied cases (N=132)

Intra-class correlation coefficient showed a significant correlation between DPR and CBCT values (ICC=0.992,  $p < 0.001$ ). By dividing the cases into three major categories (buccal, lingual, and neutral) the intra-class correlation coefficient again demonstrated a strong correlation between DPR and CBCT values (in buccal types: ICC=0.998,  $p < 0.001$ ; and in lingual types: ICC=0.993,  $p < 0.001$ , Table 2).

**Table 2:** The correlation between values of DPR and CBCT (N=132)

	Frequency	intra-class correlation	p Value
Buccal types	46	0.998	<0.001
Lingual types	84	0.993	<0.001
Neutral types	2		
Total	132	0.992	<0.001

There was a positive correlation between the horizontal distance of the alveolar crest to the center of mandibular canal and  $\Delta$  ( $r = 0.755$ ,  $p < 0.001$ ). Regression analysis showed that for each single-unit increase in the horizontal distance of the alveolar crest to the center of mandibular canal, the DPR values were 0.87 unit more than CBCT ones ( $p < 0.001$ , Table 3).

**Table 3:** The relationship between horizontal distance and the amount of  $\Delta$

r	$\beta$	SE	p Value
0.755	0.87	.008	<0.001

$\Delta$ : (value of DPR -value of CBCT); SE: standard error

The mean (median) error of DPR in detecting the ABH for edentulous ridges in posterior of mandible was  $0.21^{mm} \pm 0.42^{mm}$  ( $0.20^{mm}$ ).

**Discussion**

In the present study, we assessed the reliability of DPR

in measuring the available bone height in comparison with CBCT. Meanwhile, the effect of horizontal location of the alveolar crest related to the center of mandibular canal on this vertical height had been appraised. Our findings showed there was a strong and linear relationship between the values measured on each modality. The mean error of DPR in detecting the available bone height for edentulous ridges in posterior of mandible was  $0.21mm \pm 0.42mm$ , which did not make a serious confusion in pre-surgical planning of dental implant therapy, especially in routine cases.

This mean error in DPR ( $0.21mm \pm 0.42mm$ ) had a regular distribution in a way that the values on DPR were smaller than the real values on CBCT when the alveolar crest was located buccally compared with the mandibular canal. Moreover, these values get closer to the real as the alveolar crest displays lingually (N types) and finally, when the alveolar crest was located more than 4mm lingual to the mandibular canal, the values on DPR were more than true ABH. An important issue is the image production method in DPR machines in which the X-ray beam has a negative degree of projection ( $-4$  to  $-7^{degrees}$ ) to eliminate the image of the skull base in the radiographs. It means that the DPR plane is not exactly coinciding with the true vertical plane. This minor difference in vertical planes results in wider and upper-located images of the objects in the lingual aspect of the image layer. It could be the reason for overestimation in lingual types.

Moreover, of 132 enrolled cases, only two showed the alveolar crest exactly on the top of the mandibular canal. So that the alveolar crest was displaced buccally or lingually after tooth extraction quiet frequently. This displacement was more likely towards the lingual side in the posterior segment of the mandible, which is compatible with clinical observations.

Contrasting results with other studies could be attributed to the sample size and/or the inclusion and exclusion criteria. In our study, from 508 available CBCT and DPR images, we selected only 144cases based on our image related exclusion factors. In the next step, 12 cases of this new sample population were excluded due to patient-related factors. Although these strict inclusion and exclusion criteria decreased the number of available cases, the remaining cases were acceptable for the current investigation since they were large enough to be

statistically meaningful. In 1994, a comparison between diagnostic value of DPR and CBCT was performed by Reedy and colleagues. [37] They concluded that the values of DPR were significantly underestimated. However, in our study we found that DPR had some degree of overestimation especially when the alveolar crest was placed more than 4mm lingual to the mandibular canal. The difference between our study and the mentioned one might be due to different sample sizes. In the mentioned study, only one human mandible was used with ten sites for measurements while in our study 132 cases had been assessed. This large number of samples could neutralize the effect of inter-case differences. Therefore, the results of our study seemed to be more reliable in terms of sample size and consequently it could have application that is more clinical.

The impact of observation error in radiologic studies could not be ignored. The expertise and number of observers, the agreement between them, and the frequency and interval of measurement by each observer are all important factors in reducing the error of human involved measurements. Bennemann and colleagues [19] observed that three groups of people involved in dentistry (oral surgeons, orthodontists and dental student) did not have any dissension in measuring the mini-screw position between the DPR and CBCT images. Although in our study the results showed an acceptable precision of DPR compared with CBCT, the difference between the values of DPR and CBCT were small. The main difference between our study and the mentioned study (in spite of other possible facts such as different study population, and so on) was most probably the difference in observers. The dental students used in the mentioned study do not seem to be expert enough for detecting the precise location of dental implants concerning their inadequate clinical experience. Furthermore, single measurement of each modality without any repeat could lead to errors. In our study, two expert professors in dental implantology team (one oral radiologist and one oral surgeon) measured each modality twice with 7-day intervals. This method could reduce the inter-examiner error and the 7-day interval could decrease or eliminate the effect of recall bias in measurements. Regarding these attempts, the values yielded by our study might be considered more accurate.

The area surveyed could be another important fac-

tor in proposing a strict guideline in such investigations. Hu and colleagues [5] assessed the reliability of both DPR and CBCT modalities in human cadavers. They concluded that DPR was a safe technique for measurements in mandible, but CBCT was recommended for maxillary dental implants especially in bucco-lingual measurements. These data were similar to our results, which show that although the DPR values had a mean error ( $0.21^{\text{mm}} \pm 0.42^{\text{mm}}$ ); they could be used safely for pre-surgical phase of dental implant therapy in posterior segments of the mandible. Since in our investigation we had no measurement on the maxillary bone, we could not confirm or reject these results, and it seems that more investigations on maxillary measurements are necessary.

The method of categorizing the edentulous ridges is also an important issue. In an almost similar study to ours, Lee and colleagues [18] investigated the effects of the location of alveolar crest on the vertical bone height in DPR. They categorized the horizontal distance to four types including three lingual types and one type for both buccal and neutral positions. They concluded that the horizontal location of alveolar crest influenced the vertical bone height on DPR. The vertical bone height was overestimated especially when the buccal cortex of bone had been resorbed. In our study, we defined seven types for the horizontal location of the alveolar crest related to the mandibular canal in order to differentiate between buccal and lingual types more efficiently. Our results related to the lingual part were same as the mentioned study. We found that for every one millimeter of transforming of alveolar crest to lingual side, the values of DPR showed  $0.87^{\text{mm}}$  over-estimation. Nevertheless, the other part of our study, which was not included in any other similar study, showed that the available bone height in DPR was underestimated in buccal types. Therefore, we could realize that in the areas showing under-estimation potential of DPR for measurement of available bone height in posterior parts of mandible, the crestal cortex would be located buccally. Therefore, our categorization might be more accurate.

This study was limited to measurements in posterior segment of the mandible. Assessment on the maxillary bone, especially in the posterior segment is recommended for the future studies. Also further studies in premolar area of mandible, concerning its proximity to

the mental foramen, are recommended.

### Conclusion

DPR can be used safely in the pre-surgical phase of dental implantation in the posterior mandible especially in routine and simple cases when CBCT is not available. Considering the overestimation of DPR, when the alveolar crest is located more than 4mm lingual to the mandibular canal, this study suggests using CBCT in situations with severe alveolar resorption.

### Acknowledgements

The authors thank the Vice-Chancellor for Research Affairs of Shiraz University of Medical Sciences for supporting this research (Grant# 92-01-76-6918). The authors also thank Dr. Sh. Hamedani (DDS, MSc) for his suggestions and editorial assistance in the manuscript and Dr. M. Vosoughi from Dental Research Development Center, of the School of Dentistry for statistical analyses.

### Conflicts of Interest

The authors declare no conflict of interest.

### References

- [1] GA Z. Boucher's prosthodontic treatment for edentulous patients. Bolender CI CGE, editor. 13th ed. St. Louis: Mosby; 2013. p. 1-8.
- [2] Misch CE, Perel ML, Wang HL, Sammartino G, Galindo-Moreno P, Trisi P, et al. Implant success, survival, and failure: the International Congress of Oral Implantologists (ICOI) Pisa Consensus Conference. *Implant Dent*. 2008; 17: 5-15.
- [3] Charyeva O, Altynbekov K, Zhartybaev R, Sabdanaliev A. Long-term dental implant success and survival--a clinical study after an observation period up to 6 years. *Swed Dent J*. 2012; 36: 1-6.
- [4] Froum SJ, Khouly I. Survival Rates and Bone and Soft Tissue Level Changes Around One-Piece Dental Implants Placed With a Flapless or Flap Protocol: 8.5-Year Results. *Int J Periodontics Restorative Dent*. 2017; 37: 327-337.
- [5] Hu KS, Choi DY, Lee WJ, Kim HJ, Jung UW, Kim S. Reliability of two different presurgical preparation methods for implant dentistry based on panoramic radiography and cone-beam computed tomography in cadavers. *J Periodontal Implant Sci*. 2012; 42: 39-44.
- [6] Chrcanovic BR, Albrektsson T, Wennerberg A. Flap-less versus conventional flapped dental implant surgery: a meta-analysis. *PLoS One*. 2014; 9(6): e100624.
- [7] Widmann G, Fischer B, Berggren JP, Denhardt A, Schullian P, Reto B, et al. Cone Beam Computed Tomography vs Multislice Computed Tomography in Computer-Aided Design/Computer-Assisted Manufacture Guided Implant Surgery Based on Three-Dimensional Optical Scanning and Stereolithographic Guides: Does Image Modality Matter? *Int J Oral Maxillofac Implants*. 2016; 31: 527-533.
- [8] Pertl L, Gashi-Cenkoglu B, Reichmann J, Jakse N, Pertl C. Preoperative assessment of the mandibular canal in implantsurgery: comparison of rotational panoramic radiography (OPG), computed tomography (CT) and cone beam computed tomography (CBCT) for preoperative assessment in implantsurgery. *Eur J Oral Implantol*. 2013; 6: 73-80.
- [9] Shiki K, Tanaka T, Kito S, Wakasugi-Sato N, Matsumoto-Takeda S, Oda M, et al. The significance of cone beam computed tomography for the visualization of anatomical variations and lesions in the maxillary sinus for patients hoping to have dental implant-supported maxillary restorations in a private dental office in Japan. *Head Face Med*. 2014; 10: 20.
- [10] Ritter L, Elger MC, Rothamel D, Fienitz T, Zinser M, Schwarz F, et al. Accuracy of peri-implant bone evaluation using cone beam CT, digital intra-oral radiographs and histology. *Dentomaxillofac Radiol*. 2014; 43(6): 20130088.
- [11] JR H. Contemporary oral and maxillofacial surgery. 6th ed. Ellis E TMR, editor. St. Louis: Elsevier; 2014. p. 261-262.
- [12] Gupta S, Patil N, Solanki J, Singh R, Laller S. Oral Implant Imaging: A Review. *Malays J Med Sci*. 2015; 22: 7-17.
- [13] Vazquez L, Saulacic N, Belser U, Bernard JP. Efficacy of panoramic radiographs in the preoperative planning of posterior mandibular implants: a prospective clinical study of 1527 consecutively treated patients. *Clin Oral Implants Res*. 2008; 19: 81-85.
- [14] Sakakura CE, Morais JA, Loffredo LC, Scaf G. A survey of radiographic prescription in dental implant assessment. *Dentomaxillofac Radiol*. 2003; 32: 397-400.
- [15] Kütük N, Gönen ZB, Yaşar MT, Demirbaş AE, Alkan A.

- Reliability of panoramic radiography in determination of neurosensory disturbances related to dental implant placement in posterior mandible. *Implant Dent.* 2014; 23: 648-652.
- [16] Kim YK, Park JY, Kim SG, Kim JS, Kim JD. Magnification rate of digital panoramic radiographs and its effectiveness for pre-operative assessment of dental implants. *Dentomaxillofac Radiol.* 2011; 40: 76-83.
- [17] Beltrão GC, de Abreu AT, Beltrão RG, Finco NF. Lateral cephalometric radiograph for the planning of maxillary implant reconstruction. *Dentomaxillofac Radiol.* 2007; 36: 45-50.
- [18] Lee SM, Lee SS, Huh KH, Yi WJ, Heo MS, Choi SC. The effects of location of alveolar crest on the vertical bone heights on panoramic radiographs. *Dentomaxillofac Radiol.* 2012; 41: 117-121.
- [19] Bennemann R, Baxmann M, Keilig L, Reimann S, Braumann B, Bourauel C. Evaluating miniscrew position using orthopantomograms compared to cone-beam computed tomography. *J Orofac Orthop.* 2012; 73: 236-648.
- [20] Alkhader M, Hudieb M. Comparison of mesiodistal space measurements of single-implant sites on panoramic and oblique images generated by cone-beam CT. *Surg Radiol Anat.* 2014; 36: 255-258.
- [21] Alghamdi AS. Pain sensation and postsurgical complications in posterior mandibular implant placement using ridge mapping, panoramic radiography, and infiltration anesthesia. *ISRN Dent.* 2013; 2013: 134210.
- [22] Correa LR, Spin-Neto R, Stavropoulos A, Schropp L, da Silveira HE, Wenzel A. Planning of dental implant size with digital panoramic radiographs, CBCT-generated panoramic images, and CBCT cross-sectional images. *Clin Oral Implants Res.* 2014; 25: 690-695.
- [23] Fortin T, Camby E, Alik M, Isidori M, Bouchet H. Panoramic images versus three-dimensional planning software for oral implant planning in atrophied posterior maxillary: a clinical radiological study. *Clin Implant Dent Relat Res.* 2013; 15: 198-204.
- [24] Mehra A, Pai KM. Evaluation of dimensional accuracy of panoramic cross-sectional tomography, its ability to identify the inferior alveolar canal, and its impact on estimation of appropriate implant dimensions in the mandibular posterior region. *Clin Implant Dent Relat Res.* 2012; 14: 100-111.
- [25] Peker I, Alkurt MT, Michcioglu T. The use of 3 different imaging methods for the localization of the mandibular canal in dental implant planning. *Int J Oral Maxillofac Implants.* 2008; 23: 463-470.
- [26] Kapila S, Conley RS, Harrell WE Jr. The current status of cone beam computed tomography imaging orthodontics. *Dentomaxillofac Radiol.* 2011; 40: 24-34.
- [27] Wakoh M, Harada T, Otonari T, Otonari-Yamamoto M, Ohkubo M, Kousuge Y, et al. Reliability of linear distance measurement for dental implant length with standardized periapical radiographs. *Bull Tokyo Dent Coll.* 2006; 47: 105-115.
- [28] Peck JN, Conte GJ. Radiologic techniques using CBCT and 3-D treatment planning for implant placement. *J Calif Dent Assoc.* 2008; 36: 287-297.
- [29] Ganz SD. Restoratively driven implant dentistry utilizing advanced software and CBCT: realistic abutments and virtual teeth. *Dent Today.* 2008; 27: 122-127.
- [30] Ganz SD. Defining new paradigms for assessment of implant receptor sites. The use of CT/CBCT and interactive virtual treatment planning for congenitally missing lateral incisors. *Compend Contin Educ Dent.* 2008; 29: 256-267.
- [31] Fornell J, Johansson LÅ, Bolin A, Isaksson S, Sennerby L. Flapless, CBCT-guided osteotome sinus floor elevation with simultaneous implant installation. I: radiographic examination and surgical technique. A prospective 1-year follow-up. *Clin Oral Implants Res.* 2012; 23: 28-34.
- [32] Guerrero ME, Noriega J, Castro C, Jacobs R. Does cone-beam CT alter treatment plans? Comparison of preoperative implant planning using panoramic versus cone-beam CT images. *Imaging Sci Dent.* 2014; 44: 121-128.
- [33] Park JB. The evaluation of digital panoramic radiographs taken for implant dentistry in the daily practice. *Med Oral Patol Oral Cir Bucal.* 2010; 15: e663-e666.
- [34] Schropp L, Stavropoulos A, Gotfredsen E, Wenzel A. Comparison of panoramic and conventional cross-sectional tomography for preoperative selection of implant size. *Clin Oral Implants Res.* 2011; 22: 424-429.
- [35] Martínez-González JM, Barona-Dorado C, Arias-Irímia O, Martínez-Rodríguez N, Fernández-Domínguez M. Panoramic and tomographic implant studies: role in the diagnosis of sinus disorders. *Med Oral Patol Oral Cir Bucal.* 2010; 15: e611-e615.
- [36] Angelopoulos C, Thomas SL, Hechler S, Parisis N, Hlavacek M. Comparison between digital panoramic radiography and cone-beam computed tomography for the identification of the mandibular canal as part of presurgi-



cal dental implant assessment. J Oral Maxillofac Surg. 2008; 66: 2130-2135.

[37] Reddy MS, Mayfield-Donahoo T, Vanderven FJ, Jeffcoat

MK. A comparison of the diagnostic advantages of panoramic radiography and computed tomography scanning for placement of root form dental implants. Clin Oral Implants Res. 1994; 5: 229-238.