

Original Article

Comparative Analysis of the Histopathologic Features, β -Catenin, and Ki67 Expression between Fibromatosis and Fibrosarcoma

Parviz Deyhimi¹, Mahmoud Reza Arefian², Parvin Mahzouni³

¹ Dept. of Oral and Maxillofacial Pathology, Dental Research Center, School of Dentistry, Isfahan University of Medical Sciences, Isfahan, Iran.

² Postgraduate Student Dept. of Oral and Maxillofacial Pathology, Dental Research Center, School of Dentistry, Isfahan University of Medical Sciences, Isfahan, Iran.

³ Dept. of Pathology, School of Medicine, Isfahan University of Medical Sciences, Isfahan, Iran.

KEY WORDS

Fibrosarcoma;
Fibromatosis;
Histopathology;
 β -catenin;
Ki-67;

Received ;
Received in revised form ;
Accepted ;

ABSTRACT

Statement of the Problem: The Biologic behavior and histopathological features of fibromatosis are intermediate between those of fibroma and fibrosarcoma.

Purpose: The aim of the present study was to determine useful histopathologic and immunohistochemical characteristics for the differentiation of these lesions.

Materials and Method: In this cross-sectional descriptive study, 40 specimens comprising 20 fibrosarcoma and 20 fibromatosis biopsies were selected. The histopathologic characteristics of these lesions were identified and immunohistochemical staining for Ki67 and β -catenin markers was performed. Sections were examined by light microscopy and positively stained cells were counted. Results were analyzed by SPSS 20 using Chi-square test, Mann-whitney test, and t-test ($p < 0.05$).

Results: Statistical significant differences were observed between fibromatosis and fibrosarcoma in terms of distribution frequency, mitotic rate, herringbone pattern, cellularity, overlapping of nuclei, mean Ki67 score, and atypia rate. The other features including age, gender, necrosis, clarity of nucleoli and mean β -catenin were not significantly different.

Conclusion: The present findings suggest the mitotic figures, Ki67, herringbone pattern, cellularity, and atypia are useful to differentiate fibromatosis from fibrosarcoma.

Corresponding Author: Deyhimi P., Dept. of Oral and Maxillofacial Pathology, School of Dentistry, Isfahan University of Medical Sciences, Hezar Jerib Avenue, Isfahan, Iran. Tel: +98-31-37925579 Fax: +98-31-37925577 Email: deihimy@dent.mui.ac.ir

Cite this article as:

Introduction

Fibromatosis is a tumor of well differentiated fibroblastic and myofibroblastic proliferations, which its biological trend and histopathological pattern is in-between benign fibroblastic lesions and fibrosarcoma. However, fibrosarcoma is a malignant mesenchymal neoplasm showing no evidence of cell differentiation [1-4]. The general term of fibromatosis was at first proposed for the lesions with particular characteristics such as proliferation of well-differentiated fibroblasts or

myofibroblasts, infiltrative growth pattern, presence of variable (but usually abundant) amount of collagen between infiltrating cells, lack of cytological features of malignancy, lack of or low mitotic activity, and aggressive clinical behavior with frequent local recurrence. However, no potential of distant metastasis should be present [5].

Histopathological and immunohistochemical (IHC) features and the role of β -catenin in pathogenesis of fibromatosis have been considered by various

researches, but their results have been slightly different or variable [6-15].

Fibrosarcoma is more evenly cellular than fibromatosis and cells are in a stable and continuous growth pattern of herringbone fascicular arrangement. Unlike fibromatosis, cells have often overlapping and are separated by less collagen and nuclei are more hyperchromatic and atypical; its nucleoli are more obvious than those in fibromatosis. Fibrosarcoma is suspected in the cases when mitotic activity is over 1 in 10 fields of high magnification (400X) [1-4, 16-20].

Currently, by using histochemical, IHC, and ultrastructural studies, the extent of the lesions classified as fibrosarcoma is being reduced. In the study of Bahrami [21] from 195 cases, which had been previously diagnosed as adult fibrosarcoma, only 26 cases (16%) met World Health Organization (WHO) criteria for fibrosarcoma. In this study, fibromatosis was in differential diagnosis with low-grade fibrosarcoma more than other tumors [21].

Comparing fibrosarcoma and fibromatosis, Soares *et al* [17], Angiero *et al* [7], and Wong [20] reported the lack of mitoses and very low degree of cellular atypia in fibromatosis as histologic criteria for differentiation of fibromatosis from fibrosarcoma. Accordingly, since fibrosarcoma, especially low-grade fibrosarcoma, overlaps fibromatosis in histopathologic diagnosis, the present study was performed to find useful criteria for histopathological and immunohistochemical distinction of these lesions by using Ki67 marker, a non-histone protein related nuclear antigen expressed by the cells in mitotic phases and β -catenin, a protein with a central role in cell adhesion and Wnt carcinogenesis pathway as nuclear messenger [4, 22].

Materials and Method

In this cross-sectional and descriptive-analytical study, the study samples included the paraffin blocks of fibrosarcoma and fibromatosis in archives of Pathology Departments of hospitals of Isfahan and Tehran University of Medical Sciences in the course of 10 years from 2003-2013, selected by sampling method. After observation of microscopic hematoxylin-eosin (H&E) slides of 300 specimens, 40 samples including 20 fibrosarcomas and 20 fibromatoses were selected. Fibrosarcomas were selected from conventional or

classic type, which were 16 cases (80%) of low grade, 2 cases (10%) of intermediate grade, and 2 cases (10%) of high grade. For precise diagnosis of fibrosarcoma, various IHC markers had been previously used to rule out similar histopathologic lesions. Fibromatoses were selected from desmoid type, which is considered in differential diagnosis of fibrosarcoma.

The including criteria considered for each tumor were large samples, preparation from excisional biopsy, and having necessary or moderate cellularity for comparison. The excluding criteria for each tumor were small samples, preparation from incisional biopsy, fibrotic samples, and poor fixation. The samples were already fixed by formalin and embedded in paraffin. After preparation of intended blocks, the technique of IHC staining was used in order to detect the presence of β -catenin and Ki-67. The main steps of the technique were carried out as follows.

After preparation of 3-micron thick sections from paraffin block of each sample, they were mounted on slides smeared by Poly-L-Lysine to prevent tissue dislocation. The slides were kept in 60 C° for 45 minutes and then three xylol changes for removing paraffin and three alcohol changes for re-hydration in descending order of 100, 96, and 70 degrees to distilled water were performed on them. Then, the samples were immersed in Tris buffer solution pH=9 in order to stabilize antigens. This collection was set in the microwave for 15-20 minutes, in order to restore by controlled heating the molecular structure of the antigen, which was deformed due to fixation. The samples were cooled at room temperature for 20 minutes and then were transferred to the solution of phosphate buffered saline (PBS) and incubated for 5 minutes in 3% hydrogen peroxide to block endogenous peroxidase activity. After washing the samples in PBS solution, they were incubated in the monoclonal antibodies of Ki-67(Dako, Carpinteria, CA, USA, Antibody codeM7240, Lot number 20020008) and β -catenin (Biogenex, San Ramon, CA, USA, Antibody codeANS10-5M, and Lot numberAN5100512X) for 1 hour, and then washed in PBS solution. Afterward, they were incubated in Envision solution (a secondary antibody) for 30 minutes, and finally the samples were incubated for 5 minutes in diluted chromogen diaminobenzidin (DAB), and then washed in distilled water and PBS.

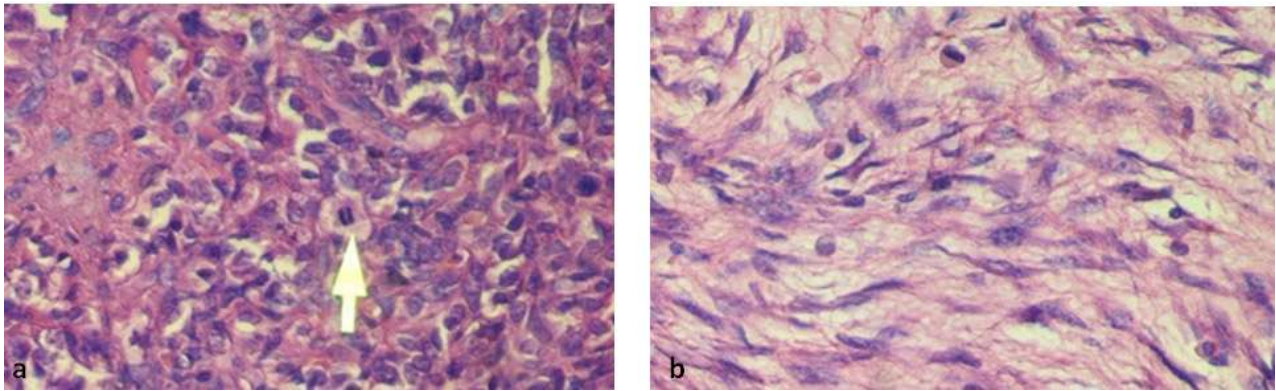


Figure 1a: Presence of mitosis (spindle division) with pleomorphism, hyperchromatism, overlapping of nuclei, and high cellularity in fibrosarcoma (400 X), **b:** Lack of mitosis, lack of pleomorphism, absence of nuclei overlapping and low cellularity in fibromatosis (400 X)

Subsequently, all samples were stained by hematoxylin. In the final phase, the samples were placed in alcohol in ascending order of 70%, 96%, and 100% in order to be dehydrated, and then in xylol in order to become transparent. Finally, they were mounted using the glue PV mount entellan (Mount PV, Walnut creek, CA, USA).

The positive controls were high-grade lymphoma for Ki67 and Signet ring cell carcinoma for β -catenin. Moreover, negative controls were the same samples of fibrosarcoma and fibromatosis in which the primary antibody was eliminated.

The samples were evaluated separately by two pathologists blind to the study. At first, H&E slides were assessed for comparison of 7 histopathologic and morphologic characteristics of both tumors including (1) mitosis (2) hyperchromatism, pleomorphism and atypia (3) herringbone pattern, (4) cellularity, (5) necrosis, (6) nucleolus, and (7) overlapping of nuclei.

To determine the number of mitosis, ten high power fields (HPFs) with magnification of 400 were observed and the presence of spindle division and serrate chromatin were considered as mitosis. Three scores were determined in which zero and one in 10 HPFs indicated fibromatosis and scores more than one in 10 HPFs was considered fibrosarcoma [2].

To determine hyperchromatism, pleomorphism, and atypia, ten fields were observed with magnification of 400, and were categorized as mild, moderate, high, and none. To determine the herringbone pattern, five fields were observed with medium power field (MPF) (100X), and reported as “with,” “without,” and “low or partly clear,” and the mode of typical branched fascicular was considered for this purpose. To determine the cellularity, five fields were assessed as low, moderate, and high with the magnification of 100 and 400. To determine the necrosis, ten fields were observed with magnification of 400 and reported as with necrosis, without necrosis, and with several necroses (in the case

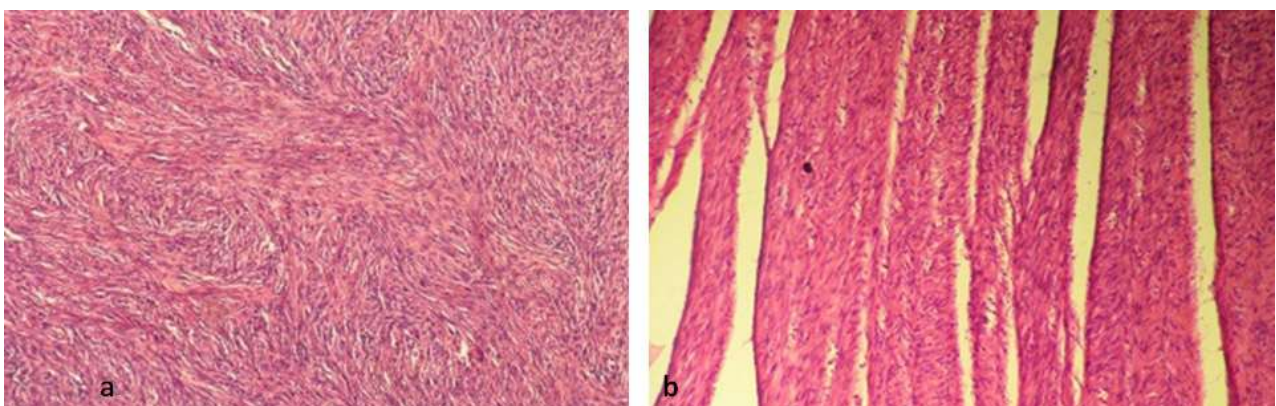


Figure 2a: Presence of prominent herringbone pattern in fibrosarcoma with high cellularity (100 X), **b:** Absence of herring bone pattern in fibromatosis (100 X)

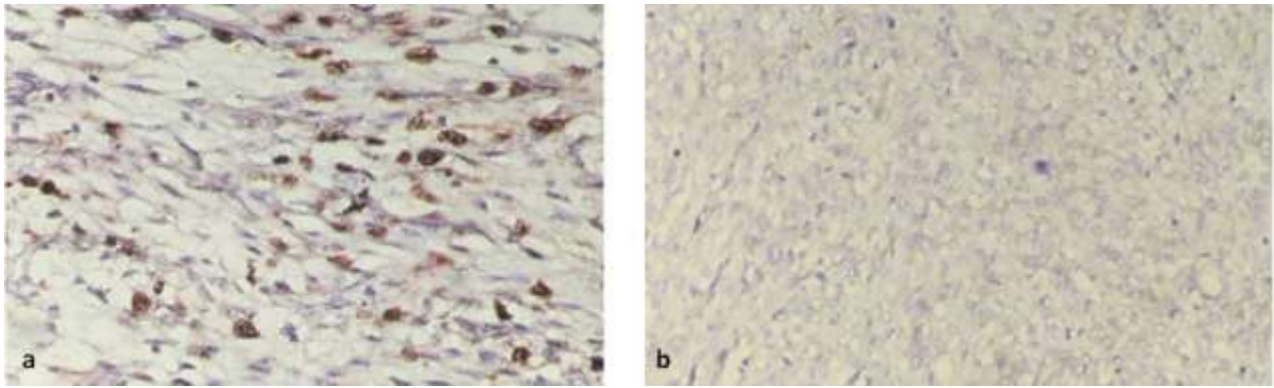


Figure 3a: Positive expression of β -catenin in fibromatosis (400 X), **b:** Absence of β -catenin in fibrosarcoma (400 X)

of having several necrotic areas). The typical granular mode without cell was the criterion.

To determine the nucleolus, it was observed in ten fields with magnification of 400 and the observation of strapped or small circle chromatin figures in nucleus considered as nucleolus. It was reported as “often with,” “often without,” and “partly clear,” and dotted chromatin was not considered as nucleolus. In this classification, “often with” and “partly clear” meant there was 90-95% and 25% nucleolus respectively, and “often without” meant there was not 90-95% nucleolus in total.

To determine the overlapping of nuclei, ten fields were observed with magnification of 400 and reported as “often with,” “often without,” and “partly with.” In this classification, “often with” and “partly with” meant there was 90- 95% and 25% overlapping of nuclei respectively, and “often without” meant there was not 90-95% overlapping of nuclei in total.

After histomorphological evaluations, IHC slides were assessed for Ki67 and β -catenin markers. The rate or percentage of cellular (nuclear) staining expression for β -catenin was estimated by counting stained brown

cells for 100 cells in 10 high power fields with magnification of 400. The results were recorded as a semi- quantitative and ranked as scores: 1+ =1- 25%, 2+ = 26 – 50 %, 3+ = 51- 75% and 4+ >75% of cells. Furthermore, the rate of staining intensity (ranging from negative to deep brown) was evaluated as scores: 0= negative, +1= very low, +2= low, +3= moderate and 4= high. Finally staining intensity distribution (SID) index was obtained via multiplying the two scores of the staining expression and intensity of each sample [23-24].

In Ki-67staining, at first 1000 cells were counted in 10 microscopic fields at magnification of 400, and percentage of positive cells was calculated. In the present study according to published resources, for Ki-67-limit, the mean values less than 5% was considered as fibromatosis and more than 5% as fibrosarcoma [25].

After gathering data, obtained information were analyzed at a significant level of 5% by statistical software SPSS 20 using Mann-Whitney test on both groups for ranked qualitative variables, Student t- test for continuous quantitative variables, and Chi-square

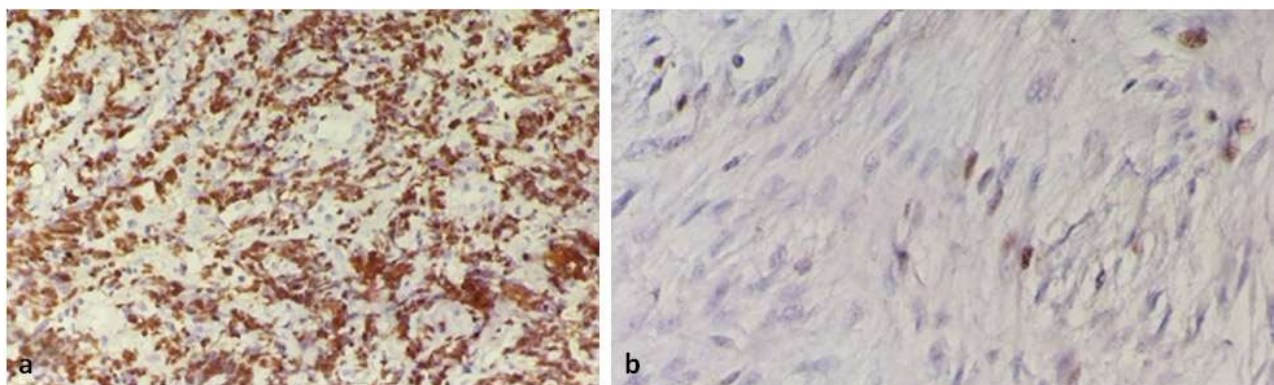
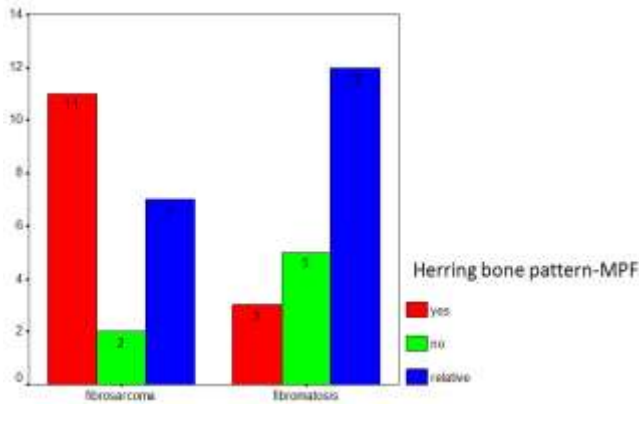
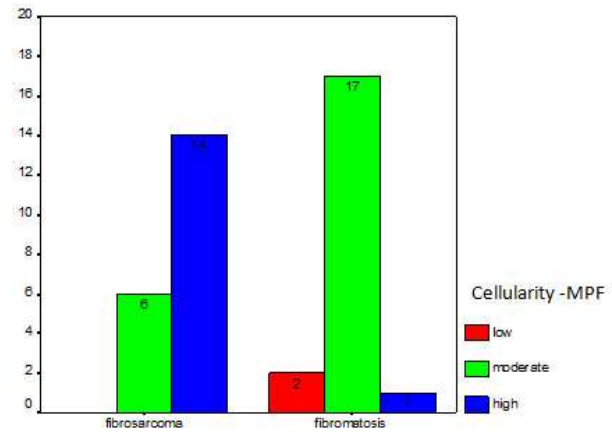


Figure 4a: Severe expression of Ki-67 in high-grade fibrosarcoma (400 X), **b:** Weak expression of Ki-67 in fibromatosis (400 X)



Graph 1: Frequency distribution of herringbone pattern based on type of tumor



Graph 2: Frequency distribution of cellularity based on type of tumor

test for nominal qualitative variables.

Results

The results of the present study can be classified in three subheadings of patients’ demographics, histopathologic findings, and IHC analysis.

Patients’ demographics

Mean age of occurrence of fibrosarcomas was 43.60-year-old. Six cases (30%) were men and 14cases (70%) were women. Four cases (20%) were in head and neck, 11 cases (55%) were in extremities, and 5 cases (25%) were in trunk. The mean age of occurrence of fibromatoses was 30.85 years. Ten cases (50%) were men and 10 cases (50%) were women. Four cases (20%) were in head and neck, 3 cases (15%) were in extremities, and 13 cases (65%) were in trunk. Based on the statistical results obtained in the present study (Table 1), no significant differences between fibromatosis and fibrosarcoma was found in terms of the mean age and gender frequency distribution, but

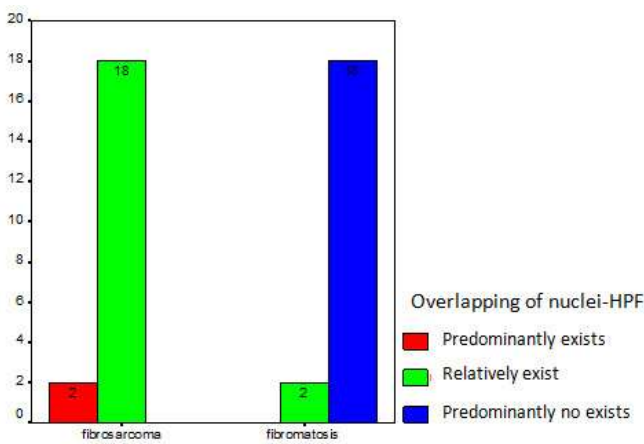
there was a significant difference between those in site frequency distribution.

Histopathologic findings

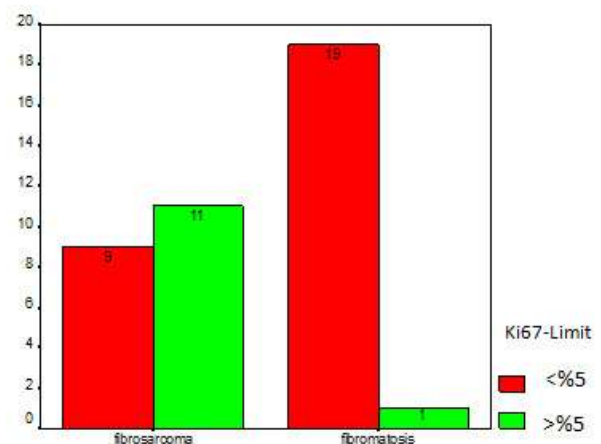
Based on the statistical results obtained in the present study (Table 1), no significant differences between fibromatosis and fibrosarcoma was found in terms of necrotic rate and rate of clarity of nucleoli. However, there was a significant difference between those in terms of mitotic rate (Figures 1a and b), herringbone pattern (Graph 1, Figures 2a and b), degree of cellularity (Graph 2, Figures 1a and b), rate of overlapping of nuclei (Graph 3, Figures 1a and b) and degree of atypia (Graph 5, Figures 1a and b).

IHC analysis

Based on the statistical results obtained in the present study (Table 1), no significant difference was found between fibromatosis and fibrosarcoma considering the mean SID of β -catenin (Table 2, Figures 3a and b), but there was a significant difference between those in



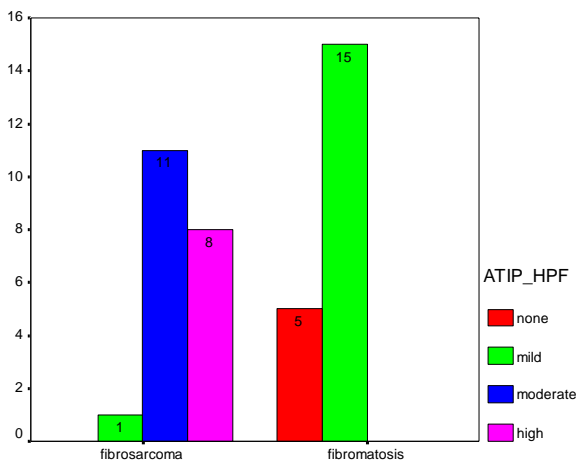
Graph 3: Frequency distribution of overlapping of nuclei based on type of tumor



Graph 4: Frequency distribution of expression rate of Ki67 mitotic marker less and more than 5% in both tumors

Table 1: Comparison of features between fibrosarcoma and fibromatosis based on statistical tests

Feature	Statistical test	p Value	Importance
Mean age	T-student	0.063	Not significant
Gender frequency distribution	Chi-square	0.197	Not significant
Necrotic rate	Mann-Whitney	0.602	Not significant
Rate of clarity of nucleoli	Mann-Whitney	0.799	Not significant
Mean SID of β -catenin	Mann-Whitney	0.369	Not significant
Area frequency distribution	Chi-square	0.017	significant
Mitotic rate	Mann-Whitney	<0.001	significant
Herringbone pattern	Mann-Whitney	0.043	significant
Degree of cellularity	Mann-Whitney	<0.001	significant
Rate of overlapping of nuclei	Mann-Whitney	<0.001	significant
Mean of Ki67	Mann-Whitney	0.046	significant
Mean of Ki67-limit	Chi-square	0.001	significant
Degree of atypia	Mann-Whitney	<0.001	significant

**Graph 5:** Frequency distribution of atypia based on type of tumor in studied sample

terms of mean of Ki67 and mean of Ki67- limit (Graph 4, Figures 4a and b).

Discussion

despite overlapping the histopathologic features of fibromatosis and fibrosarcoma, especially low-grade lesions, biologic behavior of them is different. Therefore, it is necessary to establish a precise differential diagnosis to treat these tumors effectively. Therefore, the present study was proposed to differentiate these two tumors precisely.

Analysis of the results of the present study between two tumors showed that there was no significant difference regarding age and gender prevalence but there was significant difference regarding local prevalence ($p=0.017$). The results from the present study are in consistent with the suggestions of Neville [1], Regezi [3], Rosai [4] and Enzinger [2]. The present study revealed that fibrosarcoma occurs mainly in extremities whereas fibromatosis is seen mainly in trunk; however,

in the head and neck region, the prevalence rate of both tumors was equal.

In the present study, herringbone pattern showed statistically significant difference in two tumors ($p=0.043$), because of remarkable expression in fibrosarcomas, especially low grade and absence or indeterminate expression in fibromatosis. In this regard, the obtained results of the present study were consistent with those by Neville [1], Regezi [3], Rosai [4], Enzinger [2] as well as those by Soares *et al* [17], Seper *et al* [6, 12] and Bahrami *et al* [21]. Accordingly, herringbone pattern can be regarded as an important morphological distinction between fibrosarcoma and fibromatosis.

In the present study, the difference of overlapping of nuclei and cellularity was significant between two tumors ($p<0.001$). In this regard, the obtained results were in accordance with those reported by Enzinger [2]. Thus overlapping of nuclei and cellularity can be regarded as important criteria in differential diagnosis of fibrosarcoma from fibromatosis.

In the present study, it was found that the amount of hyperchromatism and pleomorphism or atypia were significantly different between two tumors ($p<0.001$), which were in accordance with opinions of most researchers and authors such as Enzinger [2], Rosai [4], Angiero *et al* [7], and Soares *et al* [17]. Thus, hyperchromatism and atypia can be regarded as important criteria in differential diagnosis of fibrosarcoma from fibromatosis.

In the present study, it was found out that the rate of necrosis between two tumors was not significantly different ($p=0.602$). Higher necrosis is seen in high-grade fibrosarcoma, while the present study was perfor-

Table 2: Comparing Mean±sd of staining(S) and intensity (I) of β -catenin and product of multiplying of them (SID) in both tumors

Tumor	Number	Mean of staining(S)± sd	Mean of intensity(I) ±sd	Mean of SID±sd
Fibrosarcoma	20	0.0100±0.03078	0.0100±0.03078	0.0010±0.00308
Fibromatosis	20	0.2450±0.71191	0.2400±0.67153	0.5125±1.89424

Mann-Whitney test, p Value for each of three variable S, I and SID=0.369

med mostly on low-grade fibrosarcoma. In this regard, the obtained results are consistent with those by Enzinger [2] who stated that necrosis is rare in low-grade fibrosarcomas. However, necrosis could not be a good differential criterion for distinction of fibrosarcoma from fibromatosis due to the lower number of observed cases.

The rate of clarity of nucleoli showed no statistically significant difference between two tumors ($p= 0.799$). The obtained results of the present study were not in accordance with those by Enzinger [2]. Although according to Enzinger [2], clarity of nucleoli is easily more prominent in low-grade fibrosarcoma than fibromatosis; however, more prominent nucleoli are seen more often in high-grade fibrosarcoma, whereas in the present study fibrosarcomas were mostly low-grade.

Higher rate of mitosis in some cases of the present study was related to fibrosarcomas with moderate and high-grade of malignancy; however, the main purpose of the present study was to distinguish low-grade fibrosarcoma from fibromatosis. So, the present authors considered the mitotic activity higher than 1 in 10 high power fields as criterion and consequently the obtained results verified the results of valid resources including Enzinger [2] in which the differences between these values were statistically significant ($p < 0.001$).

In the present study, a significant difference ($p= 0.046$) was obtained between two groups considering the mean of Ki-67. In addition, the percentage of Ki-67 was less than 5% for fibromatosis, and more than 5% for fibrosarcoma, and the difference was statistically significant. Cutpoint of 5% was selected because this criterion has been suggested for differentiation of low-grade malignant tumors with their benign counterparts in many reliable resources [2, 4, 25]. High percentage of Ki67 relating to moderate and high grades of fibrosarcoma was not considered in this study. The results of the current study were consistent with those reported by Gnepp [25] on basal cell adenoma and basal cell adenocarcinoma in which Ki-67 was reported less

and more than 5% for basal cell adenoma and basal cell adenocarcinoma, respectively. In the current study, the expression percentage of Ki-67 was obtained 0% to 60% for fibrosarcoma and 0% to 5% for fibromatosis. Because of the dispersion of results from this study, it was impossible to assess more accurately. Therefore, the amounts below 5% and above 5% were considered as criteria for fibromatosis and fibrosarcoma respectively in order to achieve precise statistical evaluation. In study of Lin *et al* [26], the mean ki67 index of fibrosarcoma was significantly higher than fibromatosis that is in line with the results of the present study.

The mean SID of β -catenin was not significantly different between two tumors ($p= 0.369$). Therefore, it was not considered an important distinction. Moreover, the results were inconsistent with those obtained by Enzinger [2], Rosai [4], Ferenc *et al* [13], Bo *et al* [14] and Lips *et al* [15] that reported expression of β -catenin in fibromatosis to be remarkable. However, Clarke [27] pointed out the limitation of β -catenin immunohistochemistry in desmoid tumors. In addition, Amary *et al* [28] indicated that β -catenin immunohistochemistry is a sensitive but not a specific test for desmoid type fibromatosis. On the other hand, Bhattacharya *et al* [29] claimed that nuclear β -catenin expression distinguishes deep fibromatosis from other benign and malignant fibroblastic and myofibroblastic lesions such as fibrosarcoma, since all other lesions tested excluding fibromatosis lack nuclear labeling for β -catenin, showing only cytoplasmic accumulation. Accordingly, β -catenin is stained as nuclear in fibromatosis and is considered as an important diagnostic factor in distinguishing these two tumors from each other [29]. In studied samples, because the studied blocks were old, it is likely that the antigens were not activated and it may be one of the causes of low β -catenin expression in fibromatosis samples. Another reason for the lack of β -catenin expression can be low sensitivity of the IHC technique used. Antigen expression may be shown by more advanced and sensitive techniques. It is recommended to use more

new, sensitive, and specific methods of IHC in future studies. In addition, it is recommended to use a larger sample size to achieve more statistically valid tests.

Conclusion

In differentiating fibrosarcoma from fibromatosis, there was a significant difference between two tumors in terms of rate of mitotic figures, overlapping of nuclei, expression of mitotic marker of Ki-67, herringbone pattern, cellularity, hyperchromatism and pleomorphism or atypia. Thus, these features can be used to differentiate the relevant pathological lesions. However, the expression and the intensity of β -catenin, the clarity of nucleoli, and presence of necrosis were not significantly different and consequently, these features cannot be considered as important differential criteria. It is likely that β -catenin would be helpful in differentiation of these tumors if more advanced IHC methods and more new paraffin blocks could be used.

Acknowledgement

This research with investigative proposal number and ethical code of 392076 has been performed by scientific and financial support of vice-chancellery for research of Isfahan University of medical sciences. Here authors would like to thank Miss Shamsifar for her excellent technical assistance in IHC tests.

Conflict of Interest

None declared.

References

- [1] Neville BW, Damm DD, Allen CM. Oral and Maxillofacial Pathology. 4th ed. Saint Louis: Elsevier; 2016. p. 481-482, 516-517.
- [2] Sharon SW, Goldblum JR, editors. In: Enzinger & Weiss's Soft tissue tumors. 5th ed. Philadelphia: Mosby Elsevier; 2008. p. 227-228, 304.
- [3] Regezi JA, Sciubba JJ, Jordan RC. Oral pathology: clinical pathologic correlations. 7th ed. St Louis: Elsevier; 2017. p. 169-171.
- [4] Rosai J, editor. In: Rosai and Ackerman's Surgical Pathology. 10th ed. Philadelphia: Mosby Elsevier; 2011. p. 47, 65, 2116-2120.
- [5] Stout AP. Juvenile fibromatoses. *Cancer*. 1954; 7: 953-978.
- [6] Seper L, Hoppe P, Kruse-Lösler B, Büchter A, Joos U, Kleinheinz J. Aggressive fibromatosis in the jaw and facial region with bone involvement. A review. *Mund Kiefer Gesichtschir*. 2005; 9: 349-362.
- [7] Angiero F, Benedicenti S, Stefani M. Fibromatosis of the head and neck: morphological, immunohistochemical and clinical features. *Anticancer Res*. 2008; 28(3B): 1725-1732.
- [8] Lü D, Yue L, Li D, Zeng H, Yang H. Aggressive fibromatosis of the head and neck (A report of two cases and literature review). *Lin Chung Er Bi Yan Hou Tou Jing Wai Ke Za Zhi*. 2012; 26: 107-109.
- [9] Liu Y, Guan GF, Jin CS, Yang JP. Aggressive fibromatosis of the larynx: case report and brief review. *J Int Med Res*. 2011; 39: 682-689.
- [10] Abikhzer G, Bouganim N, Finesilver A. Aggressive fibromatosis of the head and neck: case report and review of the literature. *J Otolaryngol*. 2005; 34: 289-294.
- [11] Owens CL, Sharma R, Ali SZ. Deep fibromatosis (desmoid tumor): cytopathologic characteristics, clinicoradiologic features, and immunohistochemical findings on fine-needle aspiration. *Cancer*. 2007; 111: 166-172.
- [12] Seper L, Bürger H, Vormoor J, Joos U, Kleinheinz J. Aggressive fibromatosis involving the mandible--case report and review of the literature. *Oral Surg Oral Med Oral Pathol Oral Radiol Endod*. 2005; 99: 30-38.
- [13] Ferenc T, Wroński JW, Kopczyński J, Kulig A, Sidor M, Stalińska L, et al. Analysis of APC, alpha-, beta-catenins, and N-cadherin protein expression in aggressive fibromatosis (desmoid tumor). *Pathol Res Pract*. 2009; 205: 311-324.
- [14] Bo N, Wang D, Wu B, Chen L, Ruixue Ma. Analysis of β -catenin expression and exon 3 mutations in pediatric sporadic aggressive fibromatosis. *Pediatr Dev Pathol*. 2012; 15: 173-178.
- [15] Lips DJ, Barker N, Clevers H, Hennipman A. The role of APC and beta-catenin in the aetiology of aggressive fibromatosis (desmoid tumors). *Eur J Surg Oncol*. 2009; 35: 3-10.
- [16] Folpe AL. Fibrosarcoma: a review and update. *Histopathology* 2014; 64: 12-25.
- [17] Soares AB, Lins LH, Macedo AP, Pereira-Neto JS, Vargas PA. Fibrosarcoma originating in the mandible. *Med Oral Patol Oral Cir Bucal*. 2006; 11: E243-E246.

- [18] Wadhwan V, Chaudhary MS, Gawande M. Fibrosarcoma of the oral cavity. *Indian J Dent Res.* 2010; 21: 295-298.
- [19] Yuwanati MB, Tupkari JV. Fibrosarcoma of mandible: a case report. *Case Rep Dent.* 2011; 2011: 536086.
- [20] Wong SL. Diagnosis and management of desmoid tumors and fibrosarcoma. *J Surg Oncol.* 2008; 97: 554-558.
- [21] Bahrami A, Folpe AL. Adult-type fibrosarcoma: A reevaluation of 163 putative cases diagnosed at a single institution over a 48-year period. *Am J Surg Pathol.* 2010; 34: 1504-1513.
- [22] Ng TL, Gown AM, Barry TS, Cheang MC, Chan AK, Turbin DA, et al. Nuclear beta-catenin in mesenchymal tumors. *Mod Pathol.* 2005; 18: 68-74.
- [23] Flórez-Moreno GA, Henao-Ruiz M, Santa-Sáenz DM, Castañeda-Peláez DA, Tobón-Arroyave SI. Cytomorphometric and immunohistochemical comparison between central and peripheral giant cell lesions of the jaws. *Oral Surg Oral Med Oral Pathol Oral Radiol Endod.* 2008; 105: 625-632.
- [24] Deyhimi P, Hashemzadeh Z. Study of the biologic behavior of odontogenic keratocyst and orthokeratinized odontogenic cyst using TGF-alpha and P53 markers. *Pathol Res Pract.* 2014; 210: 201-204.
- [25] Gnepp DR. *Diagnostic Surgical Pathology of the Head and Neck.* 2th ed. Philadelphia: Saunders Elsevier; 2009. p. 460.
- [26] Lin XY, Wang L, Zhang Y, Dai SD, Wang EH. Variable Ki67 proliferative index in 65 cases of nodular fasciitis, compared with fibrosarcoma and fibromatosis. *Diagn Pathol.* 2013; 8: 50.
- [27] Clarke LE. Fibrous and fibrohistiocytic neoplasms: an update. *Dermatol Clin.* 2012; 30: 643-656.
- [28] Amary MF, Pauwels P, Meulemans E, Roemen GM, Islam L, Idowu B, et al. Detection of beta-catenin mutations in paraffin-embedded sporadic desmoid-type fibromatosis by mutation-specific restriction enzyme digestion (MSRED): an ancillary diagnostic tool. *Am J Surg Pathol.* 2007; 31: 1299-309.
- [29] Bhattacharya B, Dilworth HP, Iacobuzio-Donahue C, Ricci F, Weber K, Furlong MA, et al. Nuclear beta-catenin expression distinguishes deep fibromatosis from other benign and malignant fibroblastic and myofibroblastic lesions. *Am J Surg Pathol.* 2005; 29: 653-659.