

Case Report**Angulated Implants for Fabrication of Implant Supported Fixed Partial Denture in the Maxilla**Nicholas Egbert¹, Swati Ahuja², Audrey Selecman², Russell Wicks²¹ Private Practice, Salt Lake City, Utah, USA.² Dept. of Prosthodontics, University of Tennessee Health Science Center, College of Dentistry, Memphis, Tennessee, USA.**KEY WORDS**

Angulated Abutments;
 Angulated Implants;
 Co-axis;
 Labially Inclined;

Received January 2017;
 Received in Revised form March 2017;
 Accepted May 2017;

ABSTRACT

Until recently, angled abutments have been the only solution to correcting the trajectory of the emergence profile of labially inclined implants in the maxilla. However, the clinical implications of angled abutments reveal several shortcomings. Newly designed angulated implants with a 12-degree restorative platform angulation are an alternative to angled abutments. The purpose of this article was to report a case utilizing new angulated implants (Co-axis, Keystone dental, Burlington, MA, USA) in the premaxilla thereby facilitating fabrication of a multi-unit implant retained fixed dental prosthesis.

Corresponding Author: Swati Ahuja, Adjunct Assistant Professor, Department of Prosthodontics, University of Tennessee Health Science Center, College of Dentistry, Memphis, Tennessee, USA.
 Email: sahuja@uthsc.edu

Cite this article as: Egbert N., Ahuja S., Selecman A., Wicks R. Angulated Implants for Fabrication of Implant Supported Fixed Partial Denture in the Maxilla. *J Dent Shiraz Univ Med Sci.*, 2017 December; 18(4): 304-313.

Introduction

Placement and restoration of multiple implants in the maxilla create a host of challenges unique to its anatomic and esthetic requirements. [1-2] Despite bone grafting, computer aided implant positioning software and surgical guides, the labial inclination of the anterior maxilla makes vertical placement of implants difficult and forces the practitioner to labially incline/tilt the implants. [1-6] Traditional implants are intentionally tilted to achieve longer length, to place the implant in maximal bone, and to avoid vital anatomic structures such as maxillary sinuses, inferior alveolar canal, nasal floor, submandibular/sublingual spaces or mental foramen. [6] Pterygomaxillary implants have been used for more than 25 years and were one of the first tilted implant techniques. [7] The study of Balshi *et al.*, [8-9] and the study of Valero'n and Valero'n [10] support the use of pterygomaxillary implants in the resorbed maxilla. Zygomatic implants have been used for 20 years, are also tilted to achieve better bone anchorage and longer implant length. [7] Many studies have concluded that they are predictable and a viable treatment option for severe maxillary resorption. [11-

13] Another category is the distally tilted posterior implants used for the "All on four" approach. [14] They aid in increasing the antero-posterior spread of implants, decreasing the length of the cantilever, increase the posterior extension of the prostheses and decrease the stresses on the implants. [7, 14] Studies by Krekmanov *et al.*, [15] Menini *et al.*, [16] Aparcio *et al.*, [17] have concluded that tilted implants are successful and are not associated with increased bone loss compared to axially/ vertically placed implants. Tilted implants are a successful alternative to bone augmentation and nerve repositioning procedures and aid in decreasing the treatment time, expenses and morbidity associated with complicated surgical procedures. [6]

Tilted implants may make it necessary to use angled abutments to achieve a parallel path of insertion/removal of the definitive prosthesis. [6-7] These abutments improve the trajectory of the emergence profile as well as allow a degree of parallelism with implants placed in the posterior maxilla. [5, 7-9] Parallelism of anterior and posterior implants increases esthetically favorable treatment options while optimizing the biomechanics of the definitive restoration and simplifying

fabrication techniques. [4-5, 21] Eger *et al.*, [18] Sethi *et al.*, [19-20] have concluded in their studies that good function and esthetics can be achieved by restoring tilted implants with angled abutments.

The clinical implications of angled abutments reveal several shortcomings. [6] The impression, transitional prosthesis and definitive restoration may require additional materials, time and expense. [1, 5, 21-22] With an increase in technique, complexity also emanates the increase in potential error. [22] Angled abutments demand additional restorative space creating esthetic problems. [1, 6] Due to the limited angulation of prefabricated angulated abutments, contours of the definitive prosthesis may still require adjustment to the abutment. [1] Adjusting the abutment may weaken it, expose the center screw, reduce the resistance form and affect the retention of the definitive restoration. [1, 6]

Recently, a novel implant design, which permits correction of the restorative trajectory of the tilted implant without the use of angled abutments, has been introduced by Southern Implants (Co-axis, Keystone dental, Burlington, MA, USA). This new design features a 12 degrees (4.0mm ex-hex and 4.3 internal hex, available in US and Europe) and 24 degrees (5.0mm ex hex, marketed in Europe only) prosthetic axis correction built within the implant body itself. The angulation of the implant is at the neck below the crestal bone permitting interference free fabrication of the prosthesis. The angle correction feature of the implant improves parallelism of multiple implants and the path of insertion of the future restoration. These implants also facilitate the use of standard implant abutments.

Brown and Payne [23] performed a study in

which 28 novel designed angulated implants (with 12 degree angled prosthodontic platform) were placed in 27 patients who desired an immediate replacement of single maxillary anterior tooth. They concluded that these novel implants when immediately placed, immediately restored with provisional crowns and subsequent definitive crowns at 8 weeks were successful at 1 year of follow up. Vandeweghe *et al.*, [5] also conducted a similar study; they placed 15 single novel angulated implants in 14 patients and followed them for 1 year. They concluded that these new implants had 100% survival rate, good clinical outcome and the hard and soft tissue levels were stable after 6 months and the first year respectively.

The purpose of this article was to report a case utilizing angulated implants in the premaxilla to facilitate fabrication of a multi-unit implant retained fixed dental prosthesis.

Case Report

An 80-year-old Caucasian male presented to the author's clinic with the chief complaint of poor esthetics, fractured teeth and tenderness associated with the remaining maxillary anterior teeth (teeth#6-#10). Patient had five implants (teeth #3, #4, #12, #13, #14) in the maxillary arch, which were previously restored with porcelain fused to metal full coverage restorations (Figure 1). The remaining maxillary natural teeth were non-restorable (teeth #6-#10). Patient had five posterior implants (teeth #19, #20, #29, #30, #31) in the mandibular arch, which were also restored with porcelain fused to metal full coverage restorations. Patient had a tooth supported fixed dental prostheses in the mandibular anterior region (teeth#22-#25) and porcelain fused

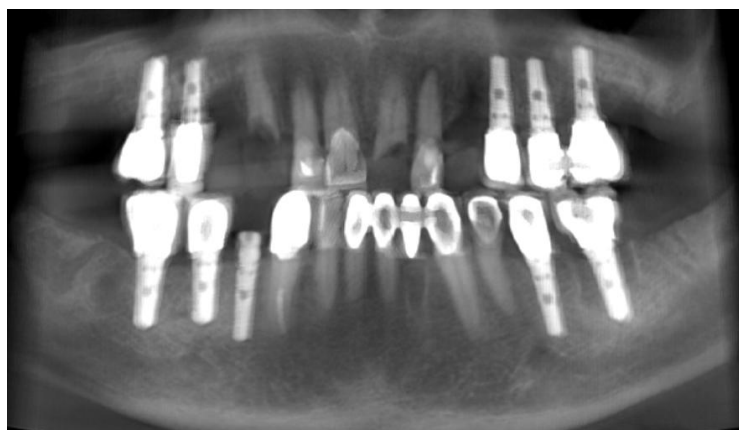


Figure 1: Panoramic radiographic depicting the patient's existing condition

to metal full coverage restorations on teeth #21 and #27, which were serviceable. The patient was satisfied and comfortable with his existing mandibular restorations. The oral hygiene of the patient was good. The patient's medical history was noncontributory and the dental history revealed that the patient had lost his maxillary and mandibular posterior teeth 5 years ago because of caries and periodontal disease. The patient's history and oral examination revealed that the patient had nocturnal parafunction (bruxism).

The following treatment plan was presented to the patient after a thorough consideration of his clinical condition, oral hygiene compliance, and preferences:

1. Cone beam computed tomography (CBCT) to aid diagnosis and implant position planning
2. Extraction of teeth #6 and #9
3. Placement of 2 immediate implants in the maxilla in location of tooth #6 and #9
4. Extraction of teeth #7, #8 and #10
5. Fabrication of an implant supported fixed partial prosthesis utilizing implant in location of teeth #4, #6, #9 and #12.
6. Oral prophylaxis education and maintenance

Planning implant placement

CBCT scan (Planmeca Promax 3D, Helsinki Finland) with the implant planning software (Nobel Clinician, Nobel Biocare, Yorba Linda, CA) was utilized for planning the optimal position and angulation of the implants with consideration of the existing implants, anatomic structures, esthetics and the design of the definitive prosthesis. The CBCT scan revealed proclination of the premaxillary bone, which would require the implants to be placed with a labial inclination resulting in divergence between anterior and posterior implants. This would necessitate the use of angled abutments. To circumvent the disadvantages of angled abutments, novel angulated implants (Co-axis, Keystone dental, Burlington, MA, USA) with a 12-degree restorative platform angulation were planned for the anterior maxilla to achieve parallelism with existing implants and position the screw access holes on the lingual surface of the restoration.

Extractions and Implant Surgery

The patient was administered a single dose of a pre-operative antibiotic and instructed to rinse with 0.2%

chlorhexidine gluconate (Savacol, Colgate, New York, NY, USA) for 1 minute. Under moderate intravenous sedation and local anesthesia, tooth # 6 and #9 were extracted surgically. The adjacent natural teeth were used as a guide for implant placement. Osteotomies were made with osteotomy drills, irrigated both internally and externally, to prevent overheating of the bone. (Figure 2)

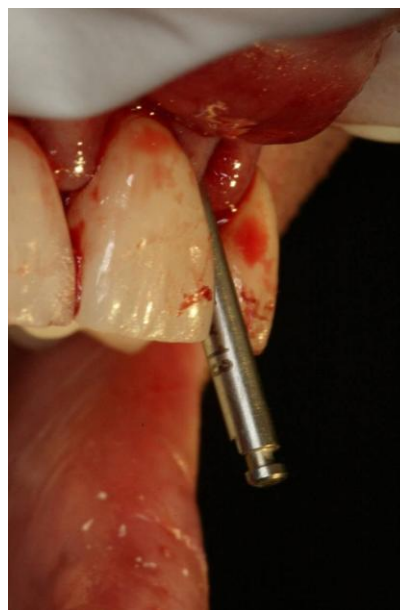

Figure 2: Pilot osteotomy drill demonstrating the labial inclination of the osteotomy

The angled direction indicator, Figure 3a was inserted in to the osteotomy to assess the access-hole position and the parallelism with previously placed implants. (Figure 3b) After verifying the implant trajectory, the osteotomy was enlarged to appropriate implant diameter and length and then novel angulated implants were immediately placed in the locations of #6 and #9. (Figure 4) It is critical to time the implant rotation accurately so that the angle correction occurs at the desired depth. A dimple on the facial aspect of the implant mount is provided by the manufacturers to guide the orientation of the implant. A CBCT scan was also made to evaluate the implant placement. (Figure 5) Once the implants were fully seated, the implant mounts, were removed from the mouth and replaced with cover screws. The upper third of the facio-coronal surface of implant #6 was visible (at the correct surgical-restorative depth) hence guided bone regeneration was accomplished at this site. An allograft (Puros; Zimmer Dental, Carlsbad, CA, USA) and a cell occlu-

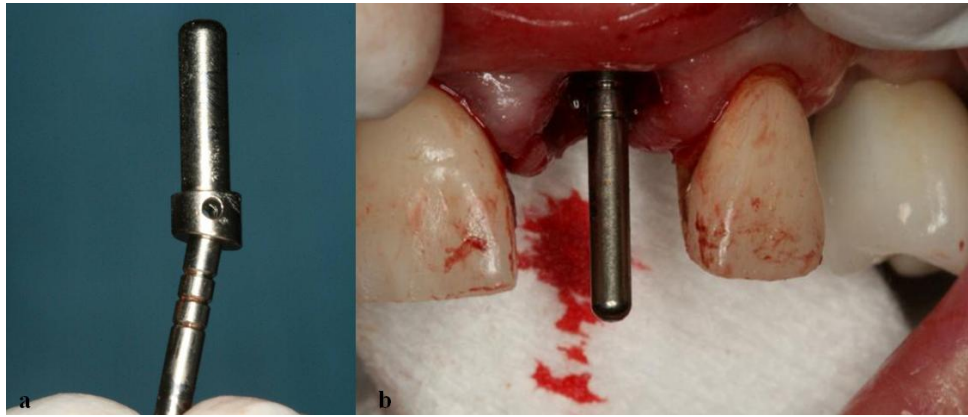


Figure 3a: Guide pin for Coaxis implant (with a built in 12 degree angle correction), **b:** Guide pin demonstrating ideal restorative trajectory of implant

sive barrier membrane (CopiOs, Zimmer Dental, Carlsbad, CA, USA) was draped over the bone graft. Periosteal releasing incisions were made to permit tissue release and tension free primary closure. The implants sites were then allowed to heal for four months. Teeth #7, #8 and #10 were extracted two months after the implant surgery and an immediate transitional removable partial dental prosthesis was delivered to the patient at the same appointment.

Fabrication and delivery of definitive restorations

The implants were uncovered; cover screws removed and the healing abutments attached at a second stage surgery, four months after implant placement surgery. The following procedures were performed to fabricate the definitive restoration: The existing implant crowns on implants #4 and #12 were sectioned and removed. A closed tray impression using indirect transfer copings (Figure 6) and yielding an implant level cast was made, followed by a splinted open-tray definitive im-

pression. Maxillo-mandibular jaw relationship records (face bow record, protrusive record and centric relation record) were registered and the casts were mounted using these records on a semi-adjustable articulator (Whip Mix 2240, Whipmix, Louisville, KY, USA).

Wax try in was accomplished and mounted casts, records and detailed instructions were sent to the laboratory for fabrication of the fixed dental prostheses. (Figure 7a and 7b) Screw access holes were incorporated in the design of the cement retained fixed dental prostheses to facilitate the retrievability of the restoration. On the day of prosthesis delivery, the definitive custom anodized titanium abutments were carefully attached to the implants and torqued as per the manufacturer specifications. (Figure 8a) The placement of novel implants permitted the lingual orientation of the screw access holes on the abutments and fabrication of an esthetic and fracture resistant prostheses. A radiograph was taken to confirm the complete seating of the

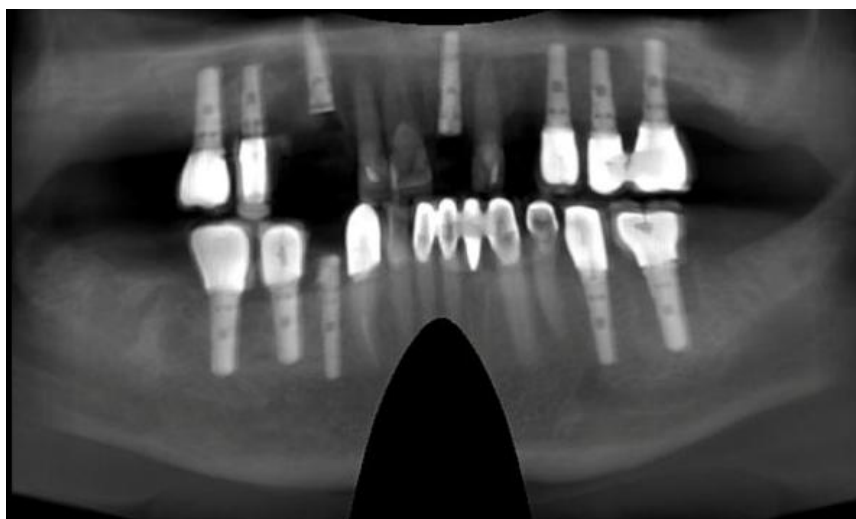


Figure 4: CT scan (Panoramic view) demonstrating placement of two angulated implants at tooth position #6 and #9

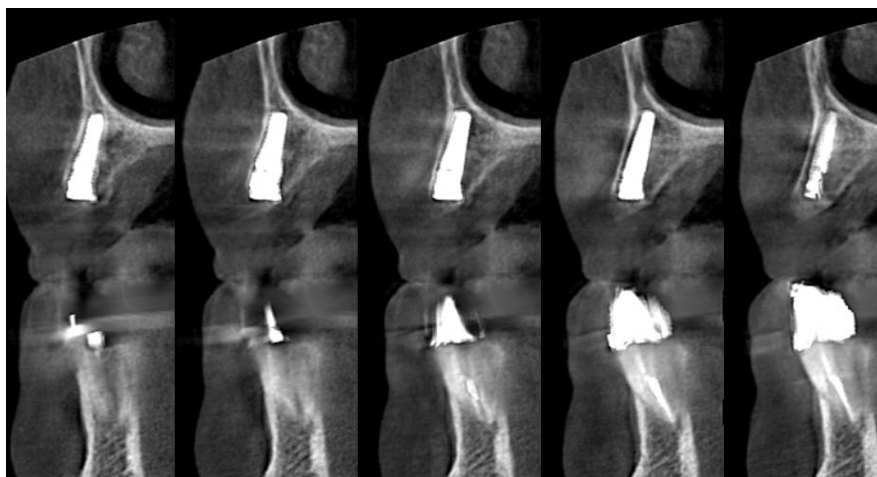

Figure 5: CT scan images depicting placement of angulated implant at position of tooth #6

abutments. The maxillary implant supported fixed dental prostheses was tried in the patients mouth. (Figure 8b) The fit and the occlusion (mutually protected occlusion) was evaluated, adjusted and then finished and polished. The screw access holes were completely blocked with vinyl polysiloxane (VPS) impression material (Aquasil, Dentsply USA, York, PA, USA), the prosthesis was loaded with a minimum amount of radiopaque resin modified glass ionomer cement (GC Fuji plus; GC America, Alsip, IL, USA) with a micro-applicator and, then very carefully seated in the mouth. A very thin explorer was used to check the marginal fit and ensure that there was no residual cement in the marginal area. The equigingival margins of the custom abutments allowed for easy visualization/cleaning of the abutment/prosthesis interface. A radiograph was taken to verify complete cement removal. Finally, approximately 2mm of the VPS material was removed

from the screw access holes and that space was filled with composite resin (Filtek Supreme Ultra universal restorative; 3M, St Paul, MN, USA). The patient was very pleased with his prosthesis. (Figure 9a and 9b) A maxillary occlusal orthosis was fabricated (to protect the teeth and the prostheses from nocturnal parafunction) and delivered to the patient. The patient was given home care instructions regarding the hygiene and maintenance of the prostheses and the occlusal orthosis and placed on a biannual recall schedule.

Discussion

Tilting of implants facilitates the placement of longer implants, reduction of the cantilever length, achievement of better bone anchorage and better antero-posterior spread of implants. [6-7] Tilted implants, which support the prostheses, also aid in stress distribution. [24] Many finite element analysis, [25-29] ani-

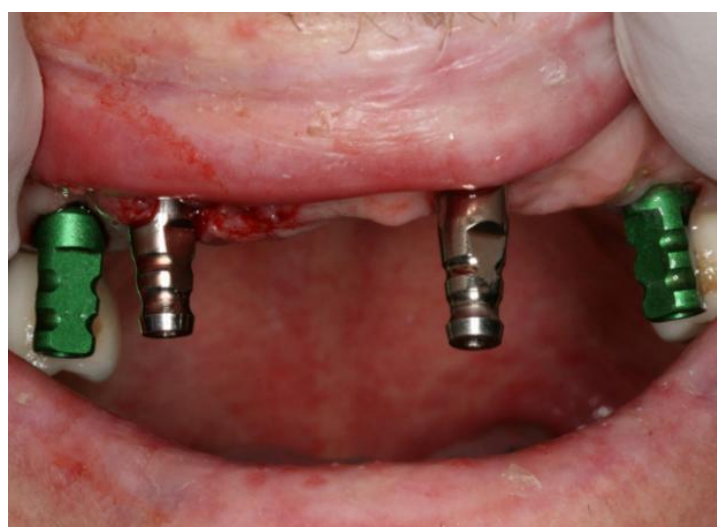

Figure 6: Impression copings demonstrating parallelism between anterior and posterior maxillary implants' restorative angles.

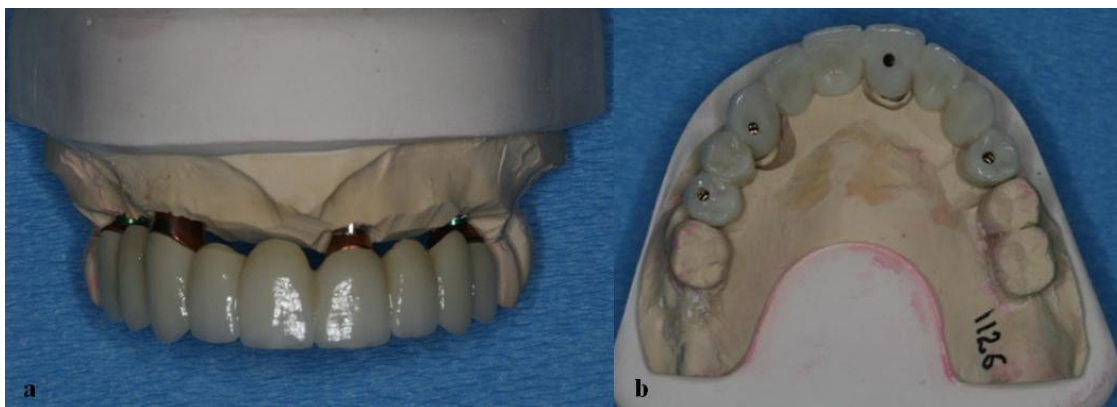


Figure 7a: Definitive restoration (facial view), **b:** Cement retained fixed partial denture with screw access holes for retrievability.

mal studies, [30-31] and clinical studies [14-15, 17, 32] have concluded that there is no significant difference in success and survival rates, bone loss and bone stresses between axially placed and tilted implants.

Accurate 3-dimensional implant placement and achievement of implant parallelism is challenging in the maxilla due to its morphology and anatomy. [1-6] Tilted implants are unavoidable in the anterior maxilla due to osseous labial proclination. [1-6] This often results in screw access that is directed on the facial surface of the restorations, compromising the esthetics and strength of the definitive restoration. Tilted implants require the use of angled abutments to redirect the restorative platform of the implant lingually to achieve the desired esthetics. [6-7] Adjustments to the angled abutment may be required to reduce bulk and achieve the desired esthetics. [1, 6] Adjusting the angled abutment may weaken the abutment and eventually lead to fracture of the definitive restoration. [6]

The use of the novel angulated implants with 12 degree-angled prosthodontic platform in this case, aided in achieving multi-implant parallelism without bone grafting and eliminated the need to use angled abut-

ments. These implants facilitate the use of standard implant abutments for fabrication of a tough and fracture resistant cement retained fixed dental prostheses (critical in this case since the patient had a history of nocturnal parafunction). The use of these implants aided in achieving an ideal implant restorative platform position. They allowed additional implant supported abutments to splint, support and retain the prosthesis, the reduction of additional implant componentry for impressions and prosthesis fabrication, decrease in prosthesis and surgical costs, and increased patient acceptance.

Studies on tapered, roughened-surfaced implants with a novel 12-degree angled prosthodontic platform, conducted by Brown and Payne [23] and Vandeweghe *et al.*, [5] report the successful use of these novel implants for immediate replacement and immediate restoration of single teeth in the esthetic zone, but they are short-term studies with only 1 year of follow up time.

Additional randomized controlled studies and more long-term clinical trials are necessary to evaluate the durability of these implants and restorations fabricated on multiple placements.

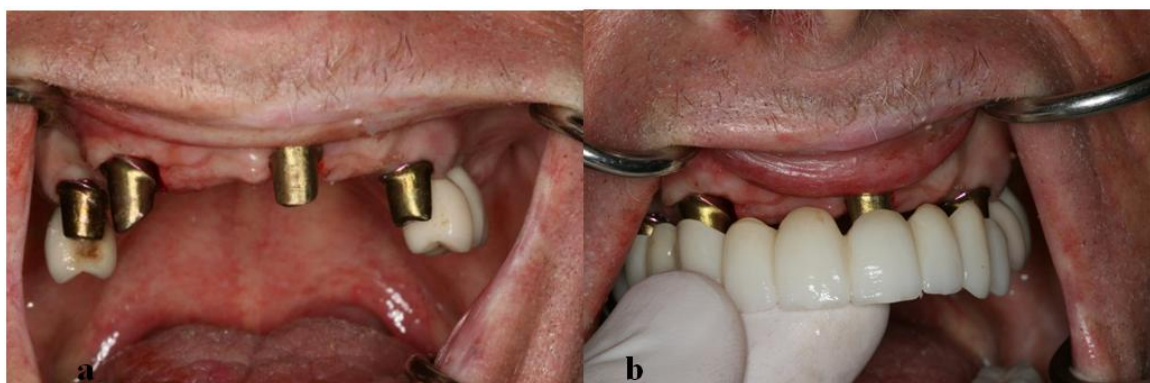


Figure 8a: Definitive abutments attached and torqued to implants. **b:** Definitive restoration tried in the patient's mouth

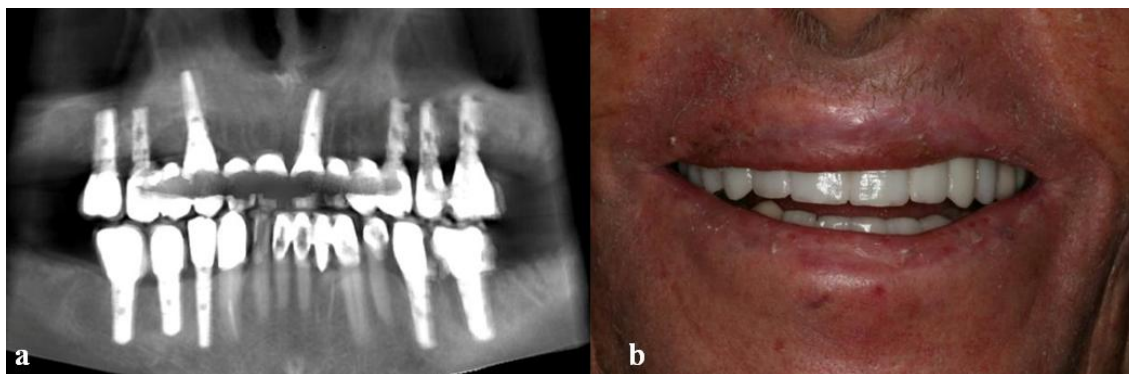


Figure 9a: Panoramic radiograph depicting the implants with the definitive restorations, **b:** Patients smile with definitive restorations

Fixed dental implant supported prostheses can be designed to be cement retained or screw retained. Screw retention was introduced in early 1980's to facilitate retrievability of failing implant restorations. [33] Screw loosening has been reported as a major problem with screw-retained restorations. [33-39] Sectioning and soldering procedures are routinely required for screw-retained prostheses. [33] In addition, screw retained restorations have some substantial disadvantages compared to cement retained restorations including increased costs, greater complexity of components and laboratory procedures, increased chair-side time and compromised esthetics. [33-34] Screw retained prostheses are usually indicated when there is decreased vertical restorative space and/or when retrievability is desired. [33]

Cemented retained implant prostheses have superior stability, [40] occlusion, esthetics and force transmission compared to screw retained implant prostheses [33-34] Zarone *et al.* [41] have concluded that a stronger implant-prosthetic connection is present in cemented restorations compared to screw retained restorations. The major disadvantage of cement-retained restorations is the extrusion of the excess cement into the peri-implant sulcus which may be difficult to recognize and remove especially when the sulcus depth is more than 3mm, resulting in future complications. [33, 42-43] Many techniques have been described in the literature to avoid/minimize the flow of cement in the subgingival sulcus. [44-46] A cement retained FDP with screw access holes was designed for the patient described in this article. Addition of screw access holes in the design would permit easy and quick removal of the prosthesis, in the event that cement would be lodged in the subgingival areas. They also facilitat-

ed future retrievability/access if it were ever needed.

Resin based glass ionomer cement was utilized for cementing the implant prostheses in this patient. In the early 1980's due to the high failure rates, provisional cements were used for cementing definitive implant restorations to maintain their retrievability. [33, 47-49] However, the increased survival and success rate and predictability of implant restorations, has led to a change in trend from provisional to definitive resin-based cements. [50] Of all the definitive cements available today, resin-modified glass ionomer has been reported as the as most commonly used definitive cement, indicated for cementing definitive implant restorations. [50] The screw access holes incorporated in the design of the prosthesis helped in maintaining its retrievability.

Several studies have concluded that a mutually protected occlusion helps significantly reduce muscle activity during parafunctional clenching. [51-57] In this occlusal scheme, the posterior teeth protect the anterior teeth in centric relation position, the incisors protect the canine and posterior teeth in protrusion and canines protect the incisors and posterior teeth during lateral excursive movements. Thus mutually protected occlusion aids in minimizing wear and damage to teeth. [51-57] Patient had a history of nocturnal parafunction hence a mutually protected occlusal scheme was chosen for this patient. A rigid maxillary orthosis with a mutually protected articulation was fabricated for the patient to prevent damage to the prosthesis and teeth during nocturnal parafunction. [58-60] Occlusal orthotics are routinely fabricated for the maxillary arch as they are well tolerated, more stable, avoid tongue crowding, and aid in achieving simultaneous, even, and bilateral occlusal contacts with all opposing teeth

regardless of the maxillomandibular jaw relationship. [59, 61] It is challenging to achieve a mutually protected articulation with a mandibular appliance in patients with Class II and III maxillomandibular jaw relationships. [61]

Conclusion

The novel angulated implants may be a viable alternative to traditional implants used along with angled abutments for replacing and restoring the missing teeth in both the maxilla and the mandible. Further studies are needed to evaluate the success and survival rates of the newly designed implants.

Conflict of Interest

Authors have no conflicts of interest to declare.

References

- [1] Kurtzman GM, Dompkowski DF, Mahler BA, Howes DG. Off-axis implant placement for anatomical considerations using the Co-axis implant. *Inside Dentistry*. 2008; 5: 96-102.
- [2] Schneider AL, Kurtzman GM. Restoration of divergent free-standing implants in the maxilla. *J Oral Implantol*. 2002; 28: 113-116.
- [3] Cavallaro J Jr, Greenstein G. Angled implant abutments: a practical application of available knowledge. *J Am Dent Assoc*. 2011; 142: 150-158.
- [4] de Avila ED, de Molon RS, de Barros-Filho LA, de Andrade MF, Mollo Fde A Jr, de Barros LA. Correction of Malpositioned Implants through Periodontal Surgery and Prosthetic Rehabilitation Using Angled Abutment. *Case Rep Dent*. 2014; 2014: 702630.
- [5] Vandeweghe S, Cosyn J, Thevissen E, Van den Berghe L, De Bruyn H. A 1-year prospective study on Co-Axis implants immediately loaded with a full ceramic crown. *Clin Implant Dent Relat Res*. 2012; 14 Suppl 1: e126-e138.
- [6] Tahmasebi S, Nicolopoulos Costa. Modern implants from a different angle. *Dental Tribune Middle east and Africa edition* 2015; Jan-Feb:24-25. Available at: http://www.dental-tribune.com/articles/specialities/implantology/21668_modern_implants_from_a_different_angle.html
- [7] Graves S, Mahler BA, Javid B, Armellini D, Jensen OT. Maxillary all-on-four therapy using angled implants: a 16-month clinical study of 1110 implants in 276 jaws. *Dent Clin North Am*. 2011; 55: 779-794.
- [8] Balshi TJ, Wolfinger GJ, Balshi SF 2nd. Analysis of 356 pterygomaxillary implants in edentulous arches for fixed prosthesis anchorage. *Int J Oral Maxillofac Implants*. 1999; 14: 398-406.
- [9] Balshi SF, Wolfinger GJ, Balshi TJ. Analysis of 164 titanium oxide-surface implants in completely edentulous arches for fixed prosthesis anchorage using the pterygomaxillary region. *Int J Oral Maxillofac Implants*. 2005; 20: 946-952.
- [10] Valerón JF, Valerón PF. Long-term results in placement of screw-type implants in the pterygomaxillary-pyramidal region. *Int J Oral Maxillofac Implants*. 2007; 22: 195-200.
- [11] Ahlgren F, Størksen K, Tornes K. A study of 25 zygomatic dental implants with 11 to 49 months' follow-up after loading. *Int J Oral Maxillofac Implants*. 2006; 21: 421-425.
- [12] Aparicio C, Ouazzani W, Garcia R, Arevalo X, Muela R, Fortes V. A prospective clinical study on titanium implants in the zygomatic arch for prosthetic rehabilitation of the atrophic edentulous maxilla with a follow-up of 6 months to 5 years. *Clin Implant Dent Relat Res*. 2006; 8: 114-122.
- [13] Bedrossian E, Rangert B, Stumpel L, Indresano T. Immediate function with the zygomatic implant: a graftless solution for the patient with mild to advanced atrophy of the maxilla. *Int J Oral Maxillofac Implants*. 2006; 21: 937-942.
- [14] Maló P, Nobre Mde A, Petersson U, Wigren S. A pilot study of complete edentulous rehabilitation with immediate function using a new implant design: case series. *Clin Implant Dent Relat Res*. 2006; 8: 223-232.
- [15] Krekmanov L, Kahn M, Rangert B, Lindström H. Tilting of posterior mandibular and maxillary implants for improved prosthesis support. *Int J Oral Maxillofac Implants*. 2000; 15: 405-414.
- [16] Menini M, Signori A, Tealdo T, Bevilacqua M, Pera F, Ravera G, et al. Tilted implants in the immediate loading rehabilitation of the maxilla: a systematic review. *J Dent Res*. 2012; 91: 821-827.
- [17] Aparicio C, Perales P, Rangert B. Tilted implants as an alternative to maxillary sinus grafting: a clinical, radiologic, and periosteal study. *Clin Implant Dent Relat Res*. 2001; 3: 39-49.

- [18] Eger DE, Gunsolley JC, Feldman S. Comparison of angled and standard abutments and their effect on clinical outcomes: a preliminary report. *Int J Oral Maxillofac Implants.* 2000; 15: 819-823.
- [19] Sethi A, Kaus T, Sochor P. The use of angulated abutments in implant dentistry: five-year clinical results of an ongoing prospective study. *Int J Oral Maxillofac Implants.* 2000; 15: 801-810.
- [20] Sethi A, Kaus T, Sochor P, Axmann-Krcmar D, Chanavaz M. Evolution of the concept of angulated abutments in implant dentistry: 14-year clinical data. *Implant Dent.* 2002; 11: 41-51.
- [21] Sorrentino R, Gherlone EF, Calesini G, Zarone F. Effect of implant angulation, connection length, and impression material on the dimensional accuracy of implant impressions: an in vitro comparative study. *Clin Implant Dent Relat Res.* 2010; 12 Suppl 1: e63-e76.
- [22] Vojdani M, Torabi K, Ansarifard E. Accuracy of different impression materials in parallel and nonparallel implants. *Dent Res J (Isfahan).* 2015; 12: 315-322.
- [23] Brown SD, Payne AG. Immediately restored single implants in the aesthetic zone of the maxilla using a novel design: 1-year report. *Clin Oral Implants Res.* 2011; 22: 445-454.
- [24] Zampelis A, Rangert B, Heijl L. Tilting of splinted implants for improved prosthodontic support: a two-dimensional finite element analysis. *J Prosthet Dent.* 2007; 97 (6 Suppl): S35-S43.
- [25] Cruz M, Wassall T, Toledo EM, da Silva Barra LP, Cruz S. Finite element stress analysis of dental prostheses supported by straight and angled implants. *Int J Oral Maxillofac Implants.* 2009; 24: 391-403.
- [26] Bellini CM, Romeo D, Galbusera F, Agliardi E, Pietrabissa R, Zampelis A, et al. A finite element analysis of tilted versus nontilted implant configurations in the edentulous maxilla. *Int J Prosthodont.* 2009; 22: 155-157.
- [27] Las Casas EB, Ferreira PC, Cimini CA Jr, Toledo EM, Barra LP, Cruz M. Comparative 3D finite element stress analysis of straight and angled wedge-shaped implant designs. *Int J Oral Maxillofac Implants.* 2008; 23: 215-225.
- [28] Markarian RA, Ueda C, Sendyk CL, Laganá DC, Souza RM. Stress distribution after installation of fixed frameworks with marginal gaps over angled and parallel implants: a photoelastic analysis. *J Prosthodont.* 2007; 16: 117-122.
- [29] Bellini CM, Romeo D, Galbusera F, Taschieri S, Raimondi MT, Zampelis A, et al. Comparison of tilted versus nontilted implant-supported prosthetic designs for the restoration of the edentulous mandible: a biomechanical study. *Int J Oral Maxillofac Implants.* 2009; 24: 511-517.
- [30] Celletti R, Pameijer CH, Bracchetti G, Donath K, Persichetti G, Visani I. Histologic evaluation of osseointegrated implants restored in nonaxial functional occlusion with preangled abutments. *Int J Periodontics Restorative Dent.* 1995; 15: 562-573.
- [31] Barbier L, Schepers E. Adaptive bone remodeling around oral implants under axial and nonaxial loading conditions in the dog mandible. *Int J Oral Maxillofac Implants.* 1997; 12: 215-223.
- [32] Francetti L, Romeo D, Corbella S, Taschieri S, Del Fabbro M. Bone level changes around axial and tilted implants in full-arch fixed immediate restorations. Interim results of a prospective study. *Clin Implant Dent Relat Res.* 2012; 14: 646-654.
- [33] Hebel KS, Gajjar RC. Cement-retained versus screw-retained implant restorations: achieving optimal occlusion and esthetics in implant dentistry. *J Prosthet Dent.* 1997; 77: 28-35.
- [34] Misch CE. *Contemporary implant dentistry.* 3th ed. St Louis: Mosby, Year Book Inc.; 1993. p. 651-685.
- [35] Kallus T, Bessing C. Loose gold screws frequently occur in full-arch fixed prostheses supported by osseointegrated implants after 5 years. *Int J Oral Maxillofac Implants.* 1994; 9: 169-178.
- [36] Jemt T, Laney WR, Harris D, Henry PJ, Krogh PH Jr, Polizzi G, et al. Osseointegrated implants for single tooth replacement: a 1-year report from a multicenter prospective study. *Int J Oral Maxillofac Implants.* 1991; 6: 29-36.
- [37] Laney WR, Jemt T, Harris D, Henry PJ, Krogh PH, Polizzi G, et al. Osseointegrated implants for single-tooth replacement: progress report from a multicenter prospective study after 3 years. *Int J Oral Maxillofac Implants.* 1994; 9: 49-54.
- [38] Jemt T, Pettersson P. A 3-year follow-up study on single implant treatment. *J Dent.* 1993; 21: 203-208.
- [39] Carlson B, Carlsson GE. Prosthodontic complications in osseointegrated dental implant treatment. *Int J Oral Maxillofac Implants.* 1994; 9: 90-94.
- [40] Hurson S. Practical clinical guidelines to prevent screw loosening. *Int J Dent Symp.* 1995; 3: 22-25.
- [41] Zarone F, Sorrentino R, Traini T, Di Iorio D, Caputi S. Fracture resistance of implant-supported screw- versus

- cement-retained porcelain fused to metal single crowns: SEM fractographic analysis. *Dent Mater.* 2007; 23: 296-301.
- [42] Agar JR, Cameron SM, Hughbanks JC, Parker MH. Cement removal from restorations luted to titanium abutments with simulated subgingival margins. *J Prosthet Dent.* 1997; 78: 43-47.
- [43] Pauletto N, Lahiffe BJ, Walton JN. Complications associated with excess cement around crowns on osseointegrated implants: a clinical report. *Int J Oral Maxillofac Implants.* 1999; 14: 865-868.
- [44] Schwedhelm ER, Lepe X, Aw TC. A crown venting technique for the cementation of implant-supported crowns. *J Prosthet Dent.* 2003; 89: 89-90.
- [45] Lee JH, Park IS, Sohn DS. A digital approach to fabricating an abutment replica to control cement volume in a cement-retained implant prosthesis. *J Prosthet Dent.* 2016;116: 25-28.
- [46] Begum Z, Sonika R, Pratik C. Effect of different cementation techniques on retained excess cement and uniaxial retention of the implant-supported prosthesis: an in vitro study. *Int J Oral Maxillofac Implants.* 2014; 29: 1333-1337.
- [47] Breeding LC, Dixon DL, Bogacki MT, Tietge JD. Use of luting agents with an implant system: Part I. *J Prosthet Dent.* 1992; 68: 737-741.
- [48] Ramp MH, Dixon DL, Ramp LC, Breeding LC, Barber LL. Tensile bond strengths of provisional luting agents used with an implant system. *J Prosthet Dent.* 1999; 81: 510-514.
- [49] Michalakis KX, Pissiotis AL, Hirayama H. Cement failure loads of 4 provisional luting agents used for the cementation of implant-supported fixed partial dentures. *Int J Oral Maxillofac Implants.* 2000; 15: 545-549.
- [50] Tarica DY, Alvarado VM, Truong ST. Survey of United States dental schools on cementation protocols for implant crown restorations. *J Prosthet Dent.* 2010; 103: 68-79.
- [51] Stuart CE, Stallard H. Oral rehabilitation and occlusion. Vol. II. 1th ed. Ventura CE Stuart Instruments: San Francisco, University of California; 1969. p. 1-6.
- [52] Pokorny PH, Wiens JP, Litvak H. Occlusion for fixed prosthodontics: a historical perspective of the gnathological influence. *J Prosthet Dent.* 2008; 99: 299-313.
- [53] D'Amico A. Canine Teeth—Normal Functional Relation of the Natural Teeth of Man. *J South California D A.* 1958; 26: 6-23.
- [54] Scaife RR Jr, Holt JE. Natural occurrence of cuspid guidance. *J Prosthet Dent.* 1969; 22: 225-229.
- [55] Manns A, Chan C, Miralles R. Influence of group function and canine guidance on electromyographic activity of elevator muscles. *J Prosthet Dent.* 1987; 57: 494-501.
- [56] Shupe RJ, Mohamed SE, Christensen LV, Finger IM, Weinberg R. Effects of occlusal guidance on jaw muscle activity. *J Prosthet Dent.* 1984; 51: 811-818.
- [57] Williamson EH, Lundquist DO. Anterior guidance: its effect on electromyographic activity of the temporal and masseter muscles. *J Prosthet Dent.* 1983; 49: 816-823.
- [58] Fitins D, Sheikholeslam A. Effect of canine guidance of maxillary occlusal splint on level of activation of masticatory muscles. *Swed Dent J.* 1993; 17: 235-241.
- [59] Bonfante G, Ramos Júnior L, Bonfante EA. Restoration of canine guidance on an occlusal splint using amalgam: a clinical report. *J Prosthet Dent.* 2003; 90: 420-423.
- [60] Rugh JD, Graham GS, Smith JC, Ohrbach RK. Effects of canine versus molar occlusal splint guidance on nocturnal bruxism and craniomandibular symptomatology. *J Craniomandib Disord.* 1989; 3: 203-210.
- [61] Antonelli J, Hottel TL, Siegel SC, Brandt R, Silva G. The occlusal guard: a simplified technique for fabrication and equilibration. *Gen Dent.* 2013; 61: 49-54.