

**Case Report****Rare and Extensive Malignant Melanoma of the Oral Cavity:  
Report of Two Cases**Parviz Deyhimi <sup>1</sup>, Sayed Mohammad Razavi <sup>2</sup>, Shirin Shahnasari <sup>3</sup>, Saeedeh Khalesi <sup>2</sup>, Solmaz Homayoni <sup>4</sup>, Payam Tavakoli <sup>5</sup><sup>1</sup> Dental Research Center, Dept. of Oral and Maxillofacial Pathology, School of Dentistry, Isfahan University of Medical Sciences, Isfahan, Iran.<sup>2</sup> Dental Implant Research Center, Dept. of Oral and Maxillofacial Pathology, School of Dentistry, Isfahan University of Medical Sciences, Isfahan, Iran.<sup>3</sup> Dental Research Center, Dept. of Oral and Maxillofacial Surgery, School of Dentistry, Isfahan University of Medical Sciences, Isfahan, Iran.<sup>4</sup> Dept. of Oral and Maxillofacial Pathology, School of Dentistry, Shahrekord University of Medical Sciences, Shahrekord, Iran.<sup>5</sup> Dept. of Oral and Maxillofacial Pathology, School of Dentistry, Islamic Azad University of Isfahan (Khorasgan), Isfahan, Iran.**KEY WORDS**

Oral manifestations;

Melanoma;

Neoplasms;

*Received August 2016;  
Received in Revised form September 2016;  
Accepted November 2016;***ABSTRACT**

Primary oral melanomas are uncommon malignant neoplasm of melanocytes origin. The most common site of oral melanoma is maxillary gingiva and hard palate. Oral mucosal melanoma exhibit a pathobiological behavior and clinical features different from cutaneous melanomas. Oral melanomas are often clinically silent which may consequently result in delayed diagnosis; thus, making the prognosis extremely poor.

This case report presents clinical, histopathological and immunohistochemical features of two cases of advanced oral melanoma, one pigmented or melanotic melanoma in a 46-year-old female and another amelanotic melanoma in a 59-year-old male patient, with chief complaint of swelling in oral mucosa.

Most oral melanomas are usually asymptomatic lesions with quick growing. Thus, the most cases are detected in late stage of diagnosis. Early diagnosis with careful examination by dentists, and early biopsy of pigmented and suspicious non-pigmented lesions would have an imperative role in more survival rate and better prognosis.

**Corresponding Author:** Khalesi S., Dental Materials Research Center, Dept. of Oral and Maxillofacial Pathology, School of Dentistry, Isfahan University of Medical Sciences, Isfahan, Iran.  
Email: [s\\_khalesi@dnt.mui.ac.ir](mailto:s_khalesi@dnt.mui.ac.ir) Tel: +98-3137922879

**Cite this article as:** Deyhimi P., Razavi SM., Shahnasari Sh., Khalesi S., Homayoni S., Tavakoli P. Rare and Extensive Malignant Melanoma of the Oral Cavity: Report of Two Cases. J Dent Shiraz Univ Med Sci., 2017 September; 18(3): 227-233.

**Introduction**

Cutaneous and mucosal melanomas are arising from malignant transformation of melanocytes. [1] Mucosal melanoma (MM) is a rare form of melanoma with an aggressive clinico-pathological behavior and poor prognosis with a 5-year survival rate of <25%. [2] Mucosal melanomas (MMs) are most often found in the upper aerodigestive tract (mouth, pharynx, larynx, nasal cavity, paranasal sinuses, and salivary glands), the genitourinary tract and the anorectal region. [3] Approximately 55% of all MMs begin in the head and neck region. [4] Furthermore, 70% of MMs of the head and neck are

located in the nasal cavity and paranasal sinuses, but only 25% occurred in oral mucosa. [5-6] The incidence of primary oral melanoma (OMs) is varying broadly between 0.2-0.8% of all melanoma and 1.3% of all cancers and 0.5% of all oral malignant neoplasms. [7-8] The mucosal melanoma of oral cavity has a higher prevalence in African-American, Japanese and Indians of Asia. There is more frequent finding of melanin pigmentation in oral mucosa of these populations. [9] Primary malignant melanoma of the oral cavity is a rare type of melanoma. [10] In contrast to cutaneous melanoma, MMs have unknown etiology, because the af-

affected sites of the lesion are not exposed to solar radiation. [6-7, 11] However, some studies presented a few causes for OMs such as ill-fitting dentures, tobacco use in any form, amalgam tattoo, nevus, and racial pigmentation. [12] Although most OMs appear *de novo*, more than one-third of these neoplasms arise from benign melanotic oral lesions. [13]

The most common location of oral melanomas is the maxillary gingiva, hard palate, and alveolar ridge; only 20% of these lesions are observed in the mandibular mucosa. [7-8] These neoplasms usually occur in the age range of 7-95. [8] In some studies, no gender distribution was observed, [7-8] but in some other studies a slight male preponderance was reported. [13-14] Oral melanomas are usually asymptomatic with irregular shape and dark brown to black color. The lesion is often detected by significant swelling, tooth mobility, ulceration, or hemorrhage of the overlying epithelium. [8, 12] However, a few cases of OM are painless, white, mucosa-colored, or red mass in clinical feature that contribute to late diagnosis, delay in starting treatment and decreasing the chance of survival. [8, 13] Only 2.3% of all MMs are amelanotic melanoma. Amelanotic melanoma is extremely rare in oral cavity. [15] Immunohistochemical staining with antibodies against certain melanocytic differentiation antigens is always required for confirmation of the diagnosis of amelanotic melanoma. [15] Based on clinical features, OMs can be divided into five types including the pigmented nodular type, the non-pigmented nodular type, the pigmented macular type, the pigmented mixed type and the non-pigmented mixed type. [15] The non-pigmented nodular type is an amelanotic nodular tumor that has not a radial growth phase, while the non-pigmented mixed type is an amelanotic nodular tumor that is surrounded by a radial growth phase. [15-16] Most OMs have aggressive biological behavior and show high incidence of metastasis, recurrence and death. However, amelanotic melanomas have a poor prognosis than pigmented melanoma. [17]

This report presents clinical, histopathological, and immunohistochemical features of two cases with an advanced oral melanoma; one pigmented melanoma in a 46-year-old female patient and another oral amelanotic melanoma in a 59-year-old male patient.

### Case 1

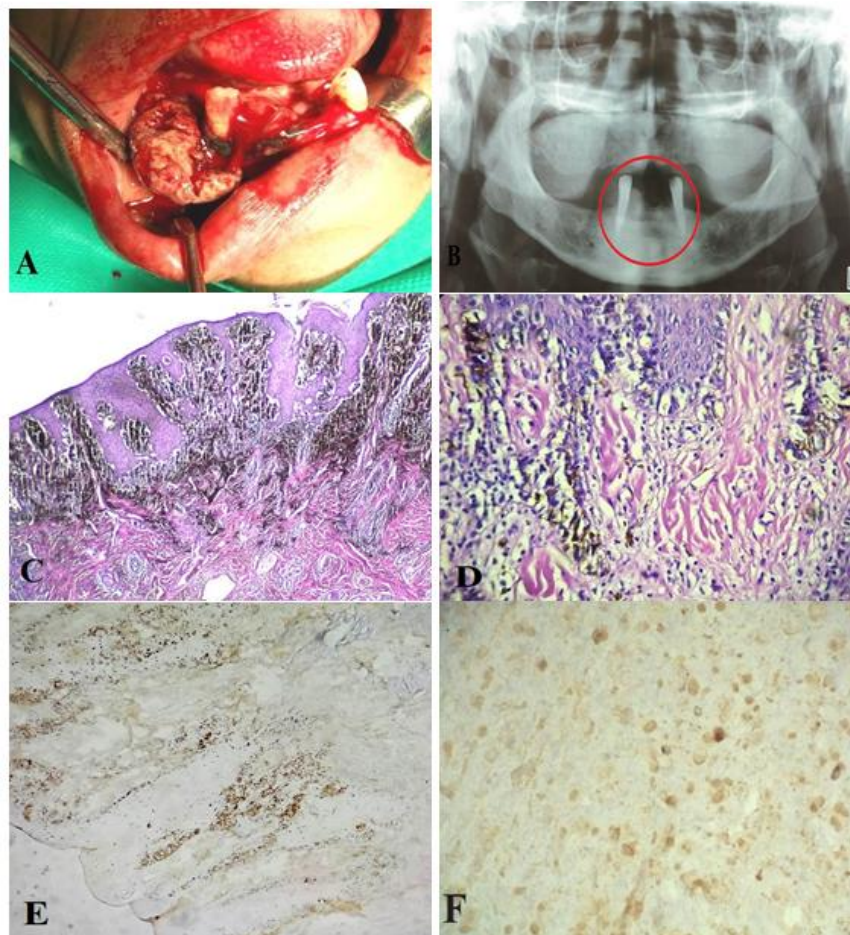
A 46-year-old female patient referred to the Department

of Oral and Maxillofacial Surgery at Dental School of Isfahan University of Medical Sciences with the complaint of swelling and bleeding in the right anterior region of mandibular mucosa. The swelling was present during last 12 months, and the lesion size was increased in this period. Patient's medical and familial history was not significant. No history of trauma and tobacco or alcohol consumption was reported. Furthermore, hematological parameters were normal. She has used dentures since 5 years ago, but now, she could not use her mandibular partial denture.

In extraoral examination, the patient had lymphadenopathy and the regional lymph nodes were palpable. In intraoral examination, we observed non-tender, painless, gray to black, broad based sessile tumor-like exophytic lesion with rough and irregular ulceration surface, with rubbery consistency, and 2×1.5×2cm dimension in anterior mandibular mucosa between right and left canine teeth. The lesion extended over the gingiva of distal part of right canine tooth to posterior mandibular region, which revealed findings of ulceration and bleeding. There was major involvement over the labial aspect of mandibular gingiva followed by anterior-posterior extension into the vestibule and oral aspect of lip mucosa (Figure 1a). The canine teeth adjacent the lesion was vital. Panoramic radiography showed the shadow of the lesion with irregular outline on mandibular bone (Figure 1b). Clinical differential diagnosis was giant cell tumor and squamous cell carcinoma.

For the patient, excisional biopsy was done. In microscope examination, hematoxylin/eosin (H&E) stained sections showed the malignant cellular proliferation of epitheloid and spindle shaped pleomorphic cells in connective tissue that was covered by stratified squamous epithelium. Junctional activity was also observed from epithelium into connective tissue (Figure 1c). The nuclei were vesicular, pleomorphic, hyperchromatic with few abnormal mitoses, and contained one or more amphophilic nucleoli. Furthermore, brown pigments were observed in some cells (Figure 1d). Immunohistochemical staining for S100, Melan-A (Mart1), and HMB45 were strongly and diffusely positive that was confirming the diagnosis of malignant melanoma (Figure 1e, 1f).

Conventional tomography (CT) of head and neck revealed the metastatic lesions in anterior and posterior



**Figure 1a:** Clinical image showing irregular lesion on mandibular alveolar mucosa in surgery procedure, **b:** Panoramic image showing the shadow of the lesion with irregular outline on mandibular bone, **c:** There is a junctional activity from epithelium into connective tissue in histopathological view (H & E staining, original magnification  $\times 100$ ), **d:** The cells and nuclei were markedly pleomorphic and amphophilic nucleoli and varied in number and size with melanin pigment (H & E staining, original magnification  $\times 400$ ), **e:** Tumor cell showing positive staining HMB-45 (Immunohistochemical staining, original magnification  $\times 100$ ), **f:** Melan-A (Immunohistochemical staining, original magnification  $\times 400$ ).

aspect of right mandibular gland (right mandibular aspect: level 1). After this result of CT, lateral and inferior tongue margins, mouth floor, submandibular salivary gland, and submandibular lymph nodes were resected under general anesthesia. The patient was referred to the Department of Oncology for further treatment. During radiotherapy and chemotherapy follow-up period, patient reported some other problems such as difficulty in eating and speech and severe trismus. The intraoral examination showed white lesions and ulcers.

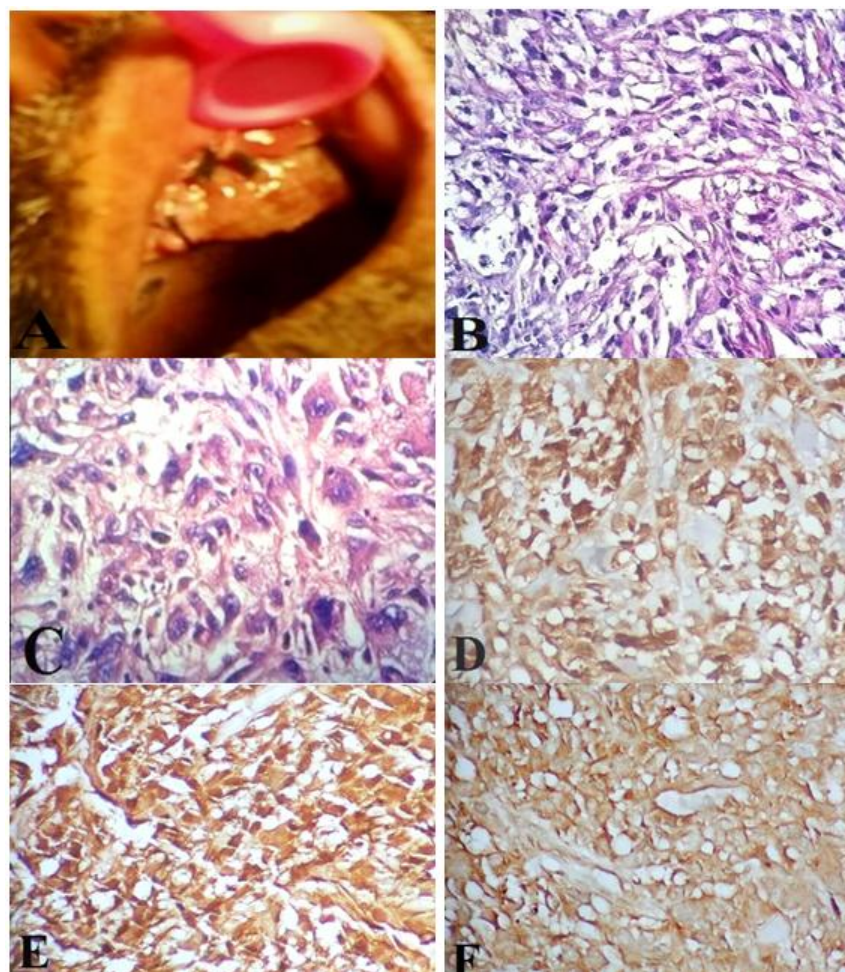
Five months after diagnosis, pulmonary metastasis has been detected. Because of headache, the patient was referred for magnetic resonance imaging (MRI). MRI showed irregular lesions in deep white matter, centrum semi-ovale and right frontal lobe and left temporal lobes that indicated brain metastasis. In addition, 9 months after diagnosis, multiple metastatic lesions were detected in liver by ultra sonographic examination. Unfortuna-

tely, the patient passed away one year after diagnosis.

## Case 2

A 59-year-old male patient was admitted to the Department of Oral and Maxillofacial Pathology at Dental School of Isfahan University of Medical Sciences with complaint of a painful mass and ulcer on the anterior maxillary gingiva. According to the patient, the mass has grown three months ago. The non-healing ulcer in this edentulous patient made him stop wearing his complete dentures last month. He had not any systemic disease or other medical problems.

In extraoral examination, the patient did not have lymphadenopathy and the regional lymph nodes were not palpable or tender. Intraoral physical examination revealed a dark purple lesion with erosive surface and irregular borders, measuring  $3 \times 2 \times 2$  cm in dimension on the left maxillary alveolar mucosa (Figure 2a). Panora-



**Figure 2a:** A tumor-like, erosive surface and amelanotic pink lesion on the left anterior buccal aspect of edentulous ridge of maxilla, **b:** Photomicrograph showing invasion of malignant spindle and polygonal cells with nuclear hyperchromatic in the connective tissue (H & E staining, original magnification  $\times 40$ ), **c:** Tumoral giant cells, **d:** Tumor cell showing positive staining Melan-A (Mart-1), **e:** S100, **f:** Vimentin (Immunohistochemical staining, original magnification  $\times 100$ ).

mic radiograph showed a slight erosion of anterior maxillary alveolar process. An incisional biopsy was performed under local anesthesia for final diagnosis. Histopathological examination showed the proliferation of polygonal, epitheloid, spindle or bizarre cells with pleomorphism and nuclear hyperchromatism and tumoral giant cells in connective tissue that was covered by surface epithelium (Figure 2b and 2c). Furthermore, excessive mitotic figures were observed. These atypical cells were arranged as large sheets rendering pseudoalveolar or storiform pattern. According to this feature, histological differential diagnoses included amelanotic melanoma, spindle cell malignancies of mesenchymal tissues, and undifferentiated carcinoma. Immunohistochemistry was used to establish the final diagnosis. The tumor cells were strongly positive for vimentin, S100, Melan-A, but were negative for pan-cytokeratin, epithelial membrane antigen (EMA), E-cadherin and desmin

(Figures 2d, 2e, 2f). Based on the histopathological and immunohistochemical findings, the lesion was diagnosed as amelanotic melanoma. The patient was referred to oral and maxillofacial surgeon and oncologist for further treatment. Chest X-ray revealed diffuse metastasis to lungs. As the patient did not keep his appointment with dental school, no additional follow-up information is available.

### Discussion

Melanocytes originate from neural crest precursor cell during development. These cells migrate into dorsolateral pathway and differentiate into mature melanocytes that are located in the basal and parabasal layers of skin and various mucous membranes. [6, 10, 18] Melanocytes can produce melatonin and serotonin. Thus, these cells have an important role in homeostasis of skin and mucosa both under physiological conditions and have a

protective function against the damage effects of sun exposure. [10, 19] However, the main functions of mature melanocytes have not been identified. [6] Melanoma cells are the malignant transformed melanocytes that are round, spindle, and polygonal cells with hyperchromatic nuclei. These cells are devoid of dendritic processes and have clonal expansion ability. [10] These features lead to the ability of deep invasion to the superficial epithelium and connective tissue, metastasis to regional lymph nodes and distant metastasis. [6]

Primary OM is usually asymptomatic, so these features lead to the delay in diagnosis. Thus, most of OMs are in advanced stage at the time of diagnosis. Frequent symptoms such as denture problem, ulceration, bleeding, growth, teeth mobility and paresthesia may be observed, similar to clinical features of our patients. [7] Clinically, most lesions are brown, black, grey, purple, red or rarely depigmented. [10] Clinical differential diagnosis of malignant melanoma consist of oral melanotic macule, smoking-associated melanosis, drug-induced melanosis (such as minocycline and antimalarial drugs), melanoacanthoma, post-inflammatory pigmentation, nevus, amalgam tattoo, physiologic pigmentation, Kaposi's sarcoma. [10] Although some of these lesions are diagnosed based on medical history and clinical research, histological examination of all focal pigmented lesions is necessary to establish a definitive and early diagnosis. [8]

The most common location of OMs is maxillary mucosa. [10] However, the current case is one of rare cases in which the lesion was located in the mandibular mucosa. The highest incidence of oral melanoma was reported to be in the fifth decade of life, ranging from 40 to 70. [10] Furthermore, in most studies, male predilection has been reported in mucosal melanomas. [10, 16] Even in some studies, men were affected 3.5 times more than women were. [10] The age of our patients was in accordance with the above-mentioned studies. The gender of first presented case of this study was different from reported predominant predilection. Most OMs appear *de novo*, although some risk factors including chronic irritation (prosthetic micro-trauma) and tobacco use have been introduced. [7, 16] In present study, use of denture may be one of the predisposing factors.

Histopathologically, MMs can show three patterns

including in *situ* pattern (15%) in which the neoplasm is limited to the epithelium and the epithelial-connective tissue interface (junctional), an invasive pattern or nodular pattern (30%) in which the neoplasm is found within the underlying connective tissue, and a combined pattern (55%) which is invasive melanoma with an *in situ* component that is typical in most advanced lesion. [6, 10] The histopathological examination of the first case showed the advanced lesion with invasive and *in situ* components. Criteria for diagnosis of primary OM were including intraepithelial (junctional) activity, evidence of malignant melanoma in the oral mucosa, and lack of any extraoral primary melanoma. [8, 19] Besides, if the melanin pigmentation is observed in histopathological examination, the diagnosis is clear. [18] In these cases, the use of immunohistochemical staining is essential for definitive diagnosis. Various expression of S100 protein, Mart1/ Melan-A, MITF, Tyrosinase and HMB45 are present in oral melanoma. [8] In one of our cases, intraepidermal (junctional) activity and melanin pigmentation in histopathological features and positive result of immunohistochemical staining for specific melanocyte antigens in tumor cells was approved primary OMs. However, when the lesion is amelanotic as it was in another presented case, many tumors can be considered in differential diagnosis. The histopathological differential diagnosis includes spindle cell malignant tumors (such as leiomyosarcomas, spindle cell carcinoma, malignant peripheral nerve sheath tumor, undifferentiated pleomorphic sarcoma, angiosarcoma, synovial sarcoma), epitheloid malignant tumors (such as epitheloid sarcoma), round cell tumors (such as lymphomas, neuroendocrine tumors, rhabdomyosarcoma, plasmacytoma), clear cell malignant tumors (such as mucoepidermoid carcinoma, renal cell carcinoma), and metastatic lesions. [8] In our second case, the diagnosis of amelanotic melanoma was confirmed by positive presence of Melan-A and S100. Furthermore, melanoma is negative for cytokeratins, EMA, desmin and positive for vimentin, consistent with our immunohistochemical findings. [20]

Most studies have reported that OMs are very aggressive neoplasm and many factors are related to its invasion including late diagnosis, poor resectability, and early metastasis. [12-15] Older age, extent of oral primary tumor, poor resectability, non-pigmented (amelan-

otic) lesions and regional lymph node involvement have direct relation with poorer prognosis. [8] Moreover, other factors associated with poor prognosis are a high mitotic rate of the atypical melanocytes, and vascular or neural invasion. [6] Determining the stage of melanoma is imperative for treatment planning as presented in Table 1. [10] Lymphatic metastasis at the time of diagnosis is the best prognostic factor for OMs. [21] The first presented case had involvement of the regional lymph nodes and metastatic lesions to lung, brain, and liver. Thus, the patient at the time of diagnosis was in stage II, after 4 months of the diagnosis was in stage III, and had poor prognosis.

**Table 1:** Melanoma staging [10]

<b>Stage I (N0M0) Primary tumor present only</b>	Level I: <i>in situ</i> melanoma without invasion or <i>in situ</i> melanoma with microinvasion Level II: invasion up to the lamina propria Level III: deep skeletal tissue invading in to the skeletal muscle, bone, or cartilage
Stage II: Tumor metastatic to regional lymph nodes (N1M0)	
Stage III: Tumor metastatic to distant locations (M1)	

The most effective treatment for MMs is surgical resection. [16] The primary lesion should be excised with 1.5 cm of surrounding healthy tissue. However, new treatment protocols for OMs consist of surgical resection, neck dissection for lymph node metastasis, cryotherapy, chemotherapy, radiotherapy and immunotherapy or combination of these modalities. [7] This topic showed that the lesions with color change and abrupt enlargement should particularly be biopsied for histopathological evaluation and early diagnosis. [22]

### Conclusion

Because the most OMs are usually asymptomatic with quick growing, they are detected in late stage of diagnosis. Careful oral examination by clinicians and early biopsy of pigmented and suspicious non-pigmented lesions, have an imperative role in more survival rate and better prognosis.

### Conflict of Interest

The authors of this manuscript certify that they have no conflict of interest considering this study.

### References

[1] Lourenço SV, Fernandes JD, Hsieh R, Coutinho-Camillo

CM, Bologna S, Sanguenza M, et al. Head and neck mucosal melanoma: a review. *Am J Dermatopathol.* 2014; 36: 578-587.

- [2] Papaspyrou G, Garbe C, Schadendorf D, Werner JA, Hauschild A, Egberts F. Mucosal melanomas of the head and neck: new aspects of the clinical outcome, molecular pathology, and treatment with c-kit inhibitors. *Melanoma Res.* 2011; 21: 475-482.
- [3] Pfister DG, Ang KK, Brizel DM, Burtness B, Cmelak AJ, Colevas AD, et al. Mucosal melanoma of the head and neck. *J Natl Compr Canc Netw.* 2012; 10: 320-338.
- [4] Wei C, Sirikanjanapong S, Lieberman S, Delacure M, Martiniuk F, Levis W, et al. Primary mucosal melanoma arising from the eustachian tube with CTLA-4, IL-17A, IL-17C, and IL-17E upregulation. *Ear Nose Throat J.* 2013; 92: 36-40.
- [5] Kottschade LA, Grotz TE, Dronca RS, Salomao DR, Pulido JS, Wasif N, et al. Rare presentations of primary melanoma and special populations: a systematic review. *Am J Clin Oncol.* 2014; 37: 635-641.
- [6] Tlholoe MM, Khammissa RA, Bouckaert M, Altini M, Lemmer J, Feller L. Oral mucosal melanoma: some pathobiological considerations and an illustrative report of a case. *Head Neck Pathol.* 2015; 9: 127-134.
- [7] Ahmadi-Motamayel F, Falsafi P, Baghaei F. Report of a rare and aggressive case of oral malignant melanoma. *Oral Maxillofac Surg.* 2013; 17: 47-51.
- [8] Smith MH, Bhattacharyya I, Cohen DM, Islam NM, Fitzpatrick SG, Montague LJ, et al. Melanoma of the Oral Cavity: an Analysis of 46 New Cases with Emphasis on Clinical and Histopathologic Characteristics. *Head Neck Pathol.* 2016; 10: 298-305.
- [9] Bhullar RP, Bhullar A, Vanaki SS, Puranik RS, Sudhakara M, Kamat MS. Primary melanoma of oral mucosa: A case report and review of literature. *Dent Res J (Isfahan).* 2012; 9: 353-356.
- [10] Munde A, Juvekar MV, Karle RR, Wankhede P. Malignant melanoma of the oral cavity: Report of two cases. *Contemp Clin Dent.* 2014; 5: 227-230.
- [11] Furney SJ, Turajlic S, Stamp G, Nohadani M, Carlisle A, Thomas JM, et al. Genome sequencing of mucosal melanomas reveals that they are driven by distinct mechanisms from cutaneous melanoma. *J Pathol.* 2013; 230: 261-269.
- [12] Vikey A, Kapoor P, Kathariya R, Vikey D, Kukreja I. Malignant melanoma of gingiva: Report of a rare case. I-

- ndian J Dent. 2015; 6: 161-164.
- [13] Lourenço SV, Bologna SB, Hsieh R, Sanguenza M, Fernandes JD, Nico MM. Establishment and characterization of an oral mucosal melanoma cell line (MEMO) derived from a longstanding primary oral melanoma. *Am J Dermatopathol.* 2013; 35: 248-251.
- [14] Hashemi Pour MS, Rad M, Zarei MR, Chamani G. Malignant mucosal melanoma of the head and neck diagnosed in an Iranian population over an 11-year period. *Am J Appl Sci.* 2009; 6: 1467-1472.
- [15] Ohnishi Y, Watanabe M, Fujii T, Sunada N, Yoshimoto H, Kubo H, et al. A rare case of amelanotic malignant melanoma in the oral region: Clinical investigation and immunohistochemical study. *Oncol Lett.* 2015; 10: 3761-3764.
- [16] Rathore RS, Phulari RG, Vasavada DG, Patel DK. A Rare and Extensive Case of Oral Malignant Melanoma involving Mandibular Gingiva. *J Clin Diagn Res.* 2016; 10: ZD11-ZD12.
- [17] Paulo LF, Servato JP, Rosa RR, Oliveira MT, Faria PR, Silva SJ, et al. Primary amelanotic mucosal melanoma of the oronasal region: report of two new cases and literature review. *Oral Maxillofac Surg.* 2015; 19: 333-339.
- [18] Mihajlovic M, Vlajkovic S, Jovanovic P, Stefanovic V. Primary mucosal melanomas: a comprehensive review. *Int J Clin Exp Pathol.* 2012; 5: 739-753.
- [19] Slominski A, Zbytek B, Slominski R. Inhibitors of melanogenesis increase toxicity of cyclophosphamide and lymphocytes against melanoma cells. *Int J Cancer.* 2009; 124: 1470-1477.
- [20] Ohsie SJ, Sarantopoulos GP, Cochran AJ, Binder SW. Immunohistochemical characteristics of melanoma. *J Cutan Pathol.* 2008; 35: 433-444.
- [21] Adisa AO, Olawole WO, Sigbeku OF. Oral amelanotic melanoma. *Ann Ib Postgrad Med.* 2012; 10: 6-8.
- [22] Razavi SM, Jafari M, Khalesi S. Clinical guidelines for early diagnosis of oral cancers in the dental office. *J Isfahan Dent Sch.* 2013; 9: 378-392.