

**Case Report****Extrafollicular Adenomatoid Odontogenic Tumor: An Unusual Case Presentation**Vinay Kumar Reddy Kundoor<sup>1</sup>, Kotya Naik Maloth<sup>1</sup>, Nagu Naik Guguloth<sup>2</sup>, Sunitha Kesidi<sup>1</sup><sup>1</sup> Dept. of Oral Medicine and Radiology, Mamata Dental College, Khammam, Telangana, India.<sup>2</sup> Post Graduate, Dept. of Oral Medicine and Radiology, Mamata Dental College, Khammam, Telangana, India.**KEY WORDS**Adenoameloblastoma;  
Extrafollicular;  
Odontogenic Tumors;

Received: April 2015;

Received in revised form: August 2015;

Accepted: October 2015;

**ABSTRACT**

Adenomatoid odontogenic tumor (AOT) is an uncommon tumor of odontogenic origin and often misdiagnosed as an odontogenic cyst. It is predominantly found in young female patients, located more often in maxilla, and in most cases associated with an unerupted permanent tooth. There are three variants of AOT namely follicular, extra follicular, and peripheral. We report an unusual case of extrafollicular AOT in maxilla of a 50-year old male patient.

**Corresponding Author:** Kotya Naik Maloth, Dept. of Oral Medicine and Radiology, India.  
Email: [dr.kotyanaik.maloth@gmail.com](mailto:dr.kotyanaik.maloth@gmail.com) Tel: +91-8742-235161

**Cite this article as:** Reddy Kundoor VK., Maloth KN., Guguloth NK., Kesidi S. Extrafollicular Adenomatoid Odontogenic Tumor: An Unusual Case Presentation. *J Dent Shiraz Univ Med Sci.*, 2016 December; 17(4): 370-374.

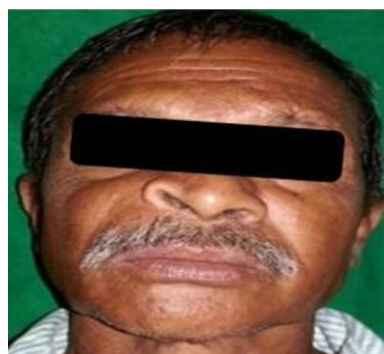**Introduction**

Adenomatoid odontogenic tumor (AOT) is an uncommon, benign and slow growing tumor, represents 3% of all odontogenic tumors. [1] Steensland first described it in 1905. [1] Dreibladdt described it as pseudo-adenameloblastoma in 1907 [2] and Harbitz in 1915 as cystic adamantoma. [3] In 1948 Stafne considered AOT as a distinct entity and others believed it to be a variant of ameloblastoma. [4] Philipson and Birn in 1969 declined this thought and suggested the name 'adenomatoid odontogenic tumor'. [5] The World Health Organization (WHO) in 1971 adopted the term 'adenomatoid odontogenic tumor'. In 2003, Max and Stern coined the name 'adenomatoid odontogenic cyst'. [6] Various other terms used to describe this tumor and Unal *et al.* listed the terms such as ameloblastic adenomatoid tumor, adamantinoma, epithelioma adamantinum, adenoameloblastoma, and teratomatous odontoma were used before the term AOT. [7] Due to the slow growing nature and symptomless behavior of the tumor, the patient tolerates the swelling for years, until it produces as obvious deformity. Here, we report a case of extrafollicular AOT in 50-years old male patient.

**Case Report**

A 50-year-old male patient reported to our department with a complaint of swelling in his right upper front

tooth region since 1 month. The swelling increased in size within a short span of time. The patient revealed no history of pain or pus discharge associated with the swelling. Extra oral examination revealed a solitary diffuse swelling present on right middle third of the face measuring approximately about 3.5×4cm in diameter, oval in shape with shiny surface extending antero-posteriorly from lateral surface of the nose to 4cm in front of the tragus of the ear and superio-inferiorly approximately 1cm below the lower eyelid to 1cm above the right corner of the mouth, causing obliteration of the nasolabial fold, lifting the ala of the nose with ill-defined borders. On palpation, it was non-tender, firm in consistency, non-compressible, non-reducible, non-fluctuant. (Figure 1)



**Figure 1:** Extra oral appearance of the patient.

Intra oral examination revealed a solitary swelling

located on the right side of palatal aspect of maxilla, measuring approximately 2.5×3 cm in diameter, roughly oval in shape with shiny surface. Swelling was extending antero-posteriorly from incisive papilla to approximately 2cm in front of fovea palatine and medio-laterally extending from mid palatine raphae till the attached gingiva of #13, #14 and extending buccally causing obliteration of buccal vestibule. On palpation, swelling was moderately tender, soft in consistency; compressible and non-reducible. (Figure 2)

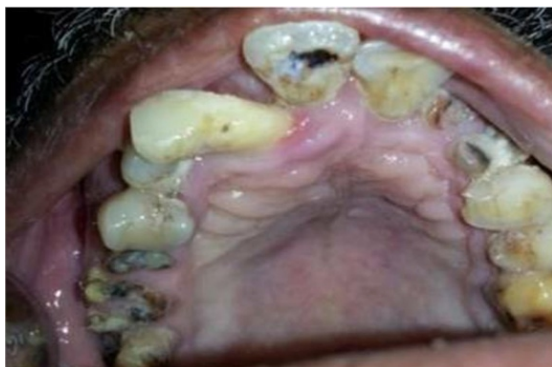

Figure 2: Intra oral appearance of the lesion.

On aspiration, a clear straw color aspirate was obtained. Based on the above findings, a provisional diagnosis of unicystic ameloblastoma was considered.

Blood investigation was non contributory. Radiographic investigations were done; panoramic radiography revealed a well-defined unilocular radiolucency with sclerotic border, measuring approx. 4x3 cm in diameter causing displacement of #12, #13 and root resorption in relation to #11, #21 and also causing obliteration of maxillary sinus. (Figure 3)

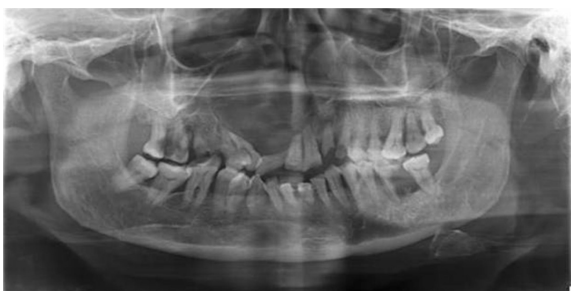

Figure 3: Panoramic radiography showing well-defined unilocular radiolucency in the anterior maxilla.

Occlusal radiograph revealed an ill-defined radiolucency measuring approximately 3×4cm in diameter showing displacement of #12 with buccal cortical expansion and multiple foci of calcifications. (Figure 4)

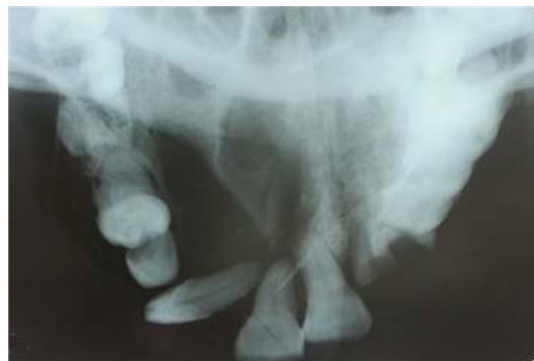

Figure 4: Maxillary occlusal radiograph showing ill-defined radiolucency with buccal cortical expansion.

Computer tomography (CT) revealed a well-defined hypodense area on right side of maxilla measuring about 4×3 cm in diameter. (Figure 5)

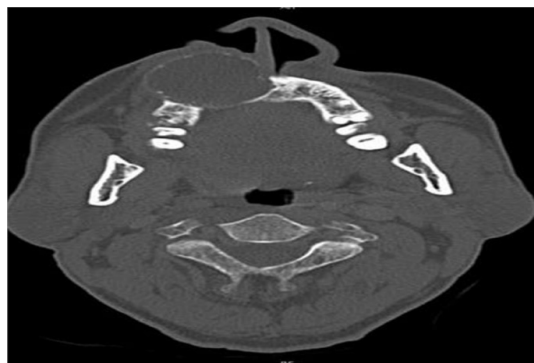

Figure 5: CT scan revealing expansion of buccal and lingual cortical plates, displacement of teeth # 12, and multiple foci of calcifications.

Based on clinical and radiographical findings with presence of fine calcifications a provisional diagnosis of calcifying epithelial odontogenic cyst (CEOC) was given, with a differential diagnosis of calcifying epithelial odontogenic tumor (CEOT) and AOT. Conservative surgical enucleation was done and the excised specimen was sent to histopathological examination. (Figure 6)

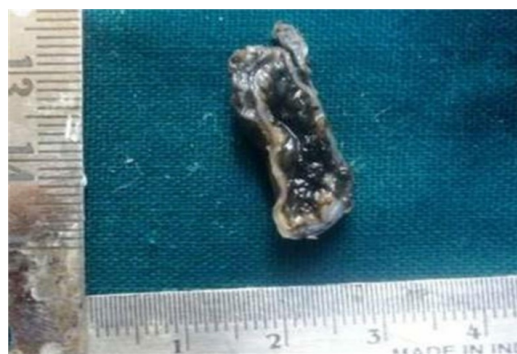
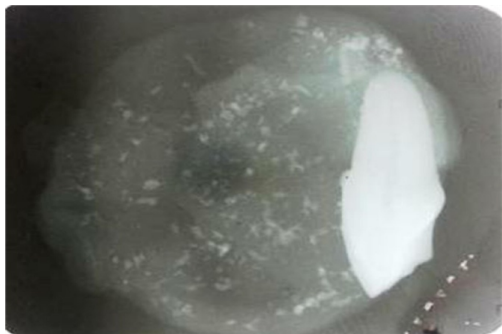
Figure 6: Excised Specimen.

Before histopathological examination, a radiogra-

phic image of excised specimen was taken which revealed multiple foci of calcifications. (Figure 7)



**Figure 7:** A radiographic image of excised specimen showing multiple calcifications.

Histopathological examination revealed sheets of polygonal cells dispersed throughout the fibrous connective tissue stroma. The odontogenic columnar epithelial cells arranged in the form of numerous rosettes, cords, duct-like structures and central lumen filled with eosinophilic material. In other places, amorphous calcifications, dentinoid-like material, and hemorrhagic-like areas were noted, which confirmed the diagnosis of AOT. (Figure 8) The patient is under follow up since 2 years without recurrence. (Figure 9)

**Discussion**

AOT is a non-invasive, benign odontogenic lesion. It is most commonly seen in young patients with female predominance with a ratio of 1.9:1. [8] But in our case, the patient was a 50 years old man. Its occurrence in maxilla is twice as frequent as that of mandible, and anterior part of jaw is more frequently involved than posterior part, [8] as in the present case. An unerupted maxillary canine is the tooth most commonly associated with AOT. [8]

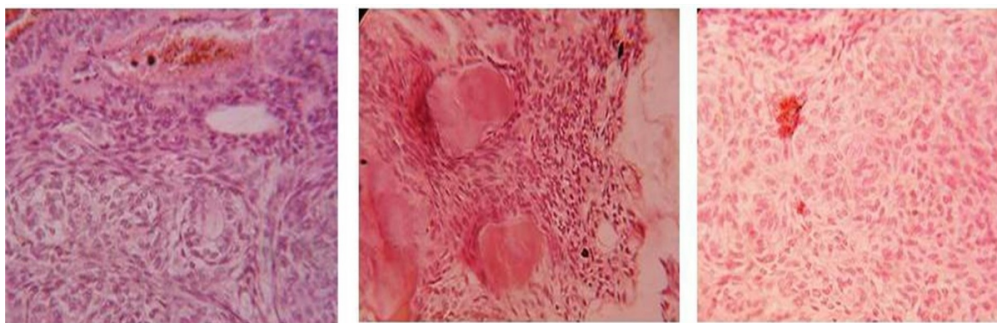
But in our case, it was not associated with any unerupted tooth. Adenomatoid odontogenic tumor is

also called ‘2/3<sup>rd</sup> tumor,’ because 2/3<sup>rd</sup> of it occur in the maxilla, 2/3<sup>rd</sup> occur in young females, 2/3<sup>rd</sup> of the cases are associated with un-erupted teeth, and 2/3<sup>rd</sup> of the affected teeth are canines. [9]

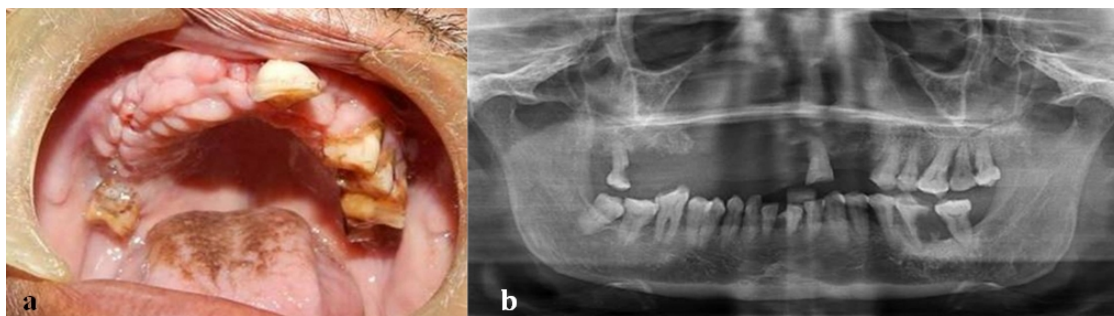
The AOT has three clinicopathologic variants, namely intraosseous follicular, intraosseous extrafollicular, and extraosseous/peripheral. The intraosseous follicular type (accounting 73% of all AOT cases) is associated with an impacted tooth whereas intraosseous extrafollicular type (accounting 24%) has no relation with an impacted tooth, as in the case we present here and the peripheral variant (accounting 3%) is attached to the gingival structures. [10-11] The tumors are usually asymptomatic and are small within the dimensions of 1.5 to 3 cm, [11] in our case the tumor was larger than that mentioned in the literature.

Radiographically, unilocular radiolucency with a distinct radiopaque border is a characteristic feature of AOT. [11-12] It is usually associated with the displacement of teeth which was evident in our case. Root resorption is seldom seen, [12] but it was reported in our case. AOT may show multiple minute variable shaped calcifications or radiopaque foci, which may appear like a cluster of small pebbles. Approximately 78% of the lesions are associated with these calcified deposits [11] which was evident in our case. Dare *et al.* [13] found that the intraoral periapical radiograph is the best radiograph to show radiopacities in AOT as discrete foci having a flocculent pattern within radiolucency even with minimal calcified deposits, when compared to a panoramic radiograph, as seen in the present case. The extra-osseous AOTs are rarely detected radiographically. All the variants of AOT show identical histological features. [11, 14]

WHO has described the histological features of the tumor as a tumor of odontogenic epithelium with duct like structures and with varying degrees of inducti-



**Figure 8:** Photomicrograph showing histologic features. (a) Duct like structures (b) Calcified masses (c) Rossete pattern.



**Figure 9a:** Post-operative intra-oral photography, **b:** Post-operative panoramic radiography.

ve change in the connective tissue. AOT is usually surrounded by a well developed connective tissue capsule. It may present as a solid mass, a single large cystic space, or as numerous small cystic spaces. The tumor is composed of spindle-shaped or polygonal cells forming sheets and whorled masses in a scant connective tissue stroma. The amorphous eosinophilic material is seen between the epithelial cells, as well as in the center of the rosette-like structure. The characteristic duct-like structures are lined by a single row of columnar epithelial cells, the nuclei of which are polarized away from the central lumen, our case was evident with these common features reported in the literature. The lumen may be empty or contain amorphous eosinophilic material. [9] Dystrophic calcification in varying amounts and in different forms is usually encountered in most AOTs within the lumina of the duct like structures, scattered among epithelial masses or in the stroma. The immunohistochemical studies report that the slow growth, benign behavior, and low tendency to recur are clearly related to the low cellular proliferation observed on performing immunostaining for the Ki67 antigen. [14]

Interestingly, our present case had some unusual clinical, radiographical and histopathological features that distinguished it from normal types of AOT. Firstly, AOTs are slow growing and relatively small in size, but in the present case showed unusual rapid growth to more than 3cm within one month, as reported by the patient. Secondly, radiographical examination reveals a unilocular radiolucency with distinct radiopaque borders with calcifications and associated with root resorption of #11, # 21, which is quite uncommon. In fact, to our knowledge, only 5 cases of AOT with root resorption have been reported. [9]

Conservative surgical enucleation or curettage is the treatment of choice. For treating periodontal intra-

bony defects caused by AOT, guided tissue regeneration with membrane technique is suggested after complete removal of the tumor. [15] Our patient is healthy without recurrence and is under follow-up after local excision.

### Conclusion

The case we discussed emphasizes extrafollicular variant of AOT which is very rare. It is commonly referred as “2/3<sup>rd</sup> tumor” with more predominance in maxilla, affecting commonly young adults i.e. second decade of life. It should also be considered in the differential diagnosis affecting the age group of older individuals, although its incidence is low.

### Conflicts of Interest

There is no conflict of interest in relation to this study.

### References

- [1] Komal K, Vibhakar A. Mural adenomatoid odontogenic tumor in the mandible: A rare case. *Int J Oral Maxillofac Pathol.* 2011; 2: 35-39.
- [2] Lucas RB. *Pathology of tumors of the oral tissues.* 4th ed. Edinburgh, Scotland: Churchill Livingstone; 1984. P. 66.
- [3] Harbitz F. On cystic tumors of the maxilla, and especially on adamantine cystadenomas (adamantomas). *Dental Cosmos.* 1915; 15: 1081-1093.
- [4] Stafne EC. Epithelial tumors associated with developmental cysts of the maxilla: report of 3 cases. *Oral Surg Oral Med Oral Pathol.* 1948; 1: 887.
- [5] Philipsen HP, Birn H. Adenomatoid odontogenic tumour, ameloblastic adenomatoid tumor or adenoameloblastoma. *Acta Pathol Microbiol Scand.* 1969; 75: 375-398.
- [6] Max RE, Stern D. *Oral and maxillofacial pathology: a rationale for diagnosis and treatment.* 2th ed. Quintessen-

- ce Publishing: Hanover Park; 2003. p. 609-612.
- [7] Unal T, Cetingul E, Gunbay T. Peripheral Adenomatoid odontogenic tumor: Birth of a term. *J Clin Pediatr Dent.* 1995; 19: 139-142.
- [8] Philipsen HP, Reichart PA. Adenomatoid odontogenic tumour: facts and figures. *Oral Oncol.* 1999; 35: 125-131.
- [9] Garg D, Palaskar S, Shetty VP, Bhushan A. Adenomatoid odontogenic tumor - hamartoma or true neoplasm: a case report. *J Oral Sci.* 2009; 51: 155-159.
- [10] Philipsen HP, Srisuwan T, Reichart PA. Adenomatoid odontogenic tumor mimicking a periapical (radicular) cyst: a case report. *Oral Surg Oral Med Oral Pathol Oral Radiol Endod.* 2002; 94: 246-248.
- [11] Yilmaz N, Acikgoz A, Celebi N, Zengin AZ, Gunhan O. Extrafollicular adenomatoid odontogenic tumor of the mandible: report of a case. *Eur J Dent.* 2009; 3: 71-74.
- [12] Panjwani S, Bagewadi A, Keluskar V. An unusual site of Adenomatoid Odontogenic Tumor: A rare case report. *J Int Oral Health.* 2010; 2: 71-76.
- [13] Dare A, Yamaguchi A, Yoshiki S, Okano T. Limitations of panoramic radiography in diagnosing Adenomatoid odontogenic tumor. *Oral Surg Oral Med Oral Pathol Oral Radiol Endod.* 1994; 77: 662-668.
- [14] Ajagbe HA, Daramola JO, Junaid TA, Ajagbe AO. Adenomatoid odontogenic tumor in a black African population: report of thirteen cases. *J Oral Maxillofac Surg.* 1985; 43: 683-687.
- [15] Blumenthal NM, Mostofi R. Repair of an intrabony defect from an adenomatoid odontogenic tumor. *J Periodontol.* 2000; 71: 1637-1640.

**Case Report****Extracystic Adenomatoid Odontogenic Tumor: An Unusual Case Presentation**Vinay Kumar Reddy Kundoor<sup>1</sup>, Kotya Naik Maloth<sup>1</sup>, Nagu Naik Guguloth<sup>2</sup>, Sunitha Kesidi<sup>1</sup><sup>1</sup> Dept. of Oral Medicine and Radiology, Mamata Dental College, Khammam, Telangana, India.<sup>2</sup> Post Graduate, Dept. of Oral Medicine and Radiology, Mamata Dental College, Khammam, Telangana, India.**KEY WORDS**Adenoameloblastoma;  
Extracystic;  
Odontogenic Tumors;

Received: April 2015;

Received in revised form: August 2015;

Accepted: October 2015;

**ABSTRACT**

Adenomatoid odontogenic tumor (AOT) is an uncommon tumor of odontogenic origin and often misdiagnosed as an odontogenic cyst. It is predominantly found in young female patients, located more often in maxilla, and in most cases associated with an unerupted permanent tooth. There are three variants of AOT namely follicular, extra follicular, and peripheral. We report an unusual case of extracystic AOT in maxilla of a 50-year old male patient.

**Corresponding Author:** Kotya Naik Maloth, Dept. of Oral Medicine and Radiology, India.  
Email: [dr.kotyanaik.maloth@gmail.com](mailto:dr.kotyanaik.maloth@gmail.com) Tel: +91-8742-235161

**Cite this article as:** Reddy Kundoor VK., Maloth KN., Guguloth NK., Kesidi S. Extracystic Adenomatoid Odontogenic Tumor: An Unusual Case Presentation. *J Dent Shiraz Univ Med Sci.*, 2016 December; 17(4): 370-374.

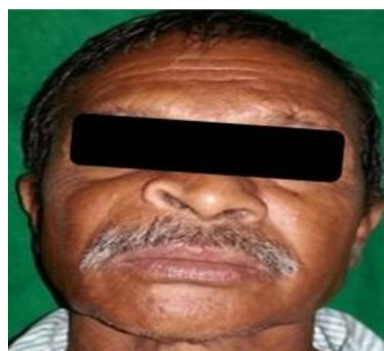**Introduction**

Adenomatoid odontogenic tumor (AOT) is an uncommon, benign and slow growing tumor, represents 3% of all odontogenic tumors. [1] Steensland first described it in 1905. [1] Dreibladdt described it as pseudo-adenoameloblastoma in 1907 [2] and Harbitz in 1915 as cystic adamantoma. [3] In 1948 Stafne considered AOT as a distinct entity and others believed it to be a variant of ameloblastoma. [4] Philipson and Birn in 1969 declined this thought and suggested the name 'adenomatoid odontogenic tumor'. [5] The World Health Organization (WHO) in 1971 adopted the term 'adenomatoid odontogenic tumor'. In 2003, Max and Stern coined the name 'adenomatoid odontogenic cyst'. [6] Various other terms used to describe this tumor and Unal *et al.* listed the terms such as ameloblastic adenomatoid tumor, adamantinoma, epithelioma adamantinum, adenoameloblastoma, and teratomatous odontoma were used before the term AOT. [7] Due to the slow growing nature and symptomless behavior of the tumor, the patient tolerates the swelling for years, until it produces as obvious deformity. Here, we report a case of extracystic AOT in 50-years old male patient.

**Case Report**

A 50-year-old male patient reported to our department with a complaint of swelling in his right upper front

tooth region since 1 month. The swelling increased in size within a short span of time. The patient revealed no history of pain or pus discharge associated with the swelling. Extra oral examination revealed a solitary diffuse swelling present on right middle third of the face measuring approximately about 3.5×4cm in diameter, oval in shape with shiny surface extending anteriorly from lateral surface of the nose to 4cm in front of the tragus of the ear and superiorly approximately 1cm below the lower eyelid to 1cm above the right corner of the mouth, causing obliteration of the nasolabial fold, lifting the ala of the nose with ill-defined borders. On palpation, it was non-tender, firm in consistency, non-compressible, non-reducible, non-fluctuant. (Figure 1)



**Figure 1:** Extra oral appearance of the patient.

Intra oral examination revealed a solitary swelling

located on the right side of palatal aspect of maxilla, measuring approximately 2.5×3 cm in diameter, roughly oval in shape with shiny surface. Swelling was extending antero-posteriorly from incisive papilla to approximately 2cm in front of fovea palatine and medio-laterally extending from mid palatine raphae till the attached gingiva of #13, #14 and extending buccally causing obliteration of buccal vestibule. On palpation, swelling was moderately tender, soft in consistency; compressible and non-reducible. (Figure 2)



Figure 2: Intra oral appearance of the lesion.

On aspiration, a clear straw color aspirate was obtained. Based on the above findings, a provisional diagnosis of unicystic ameloblastoma was considered.

Blood investigation was non contributory. Radiographic investigations were done; panoramic radiography revealed a well-defined unilocular radiolucency with sclerotic border, measuring approx. 4x3 cm in diameter causing displacement of #12, #13 and root resorption in relation to #11, #21 and also causing obliteration of maxillary sinus. (Figure 3)



Figure 3: Panoramic radiography showing well-defined unilocular radiolucency in the anterior maxilla.

Occlusal radiograph revealed an ill-defined radiolucency measuring approximately 3×4cm in diameter showing displacement of #12 with buccal cortical expansion and multiple foci of calcifications. (Figure 4)

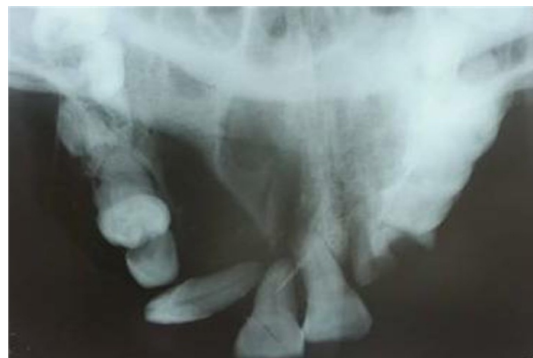

Figure 4: Maxillary occlusal radiograph showing ill-defined radiolucency with buccal cortical expansion.

Computer tomography (CT) revealed a well-defined hypodense area on right side of maxilla measuring about 4×3 cm in diameter. (Figure 5)

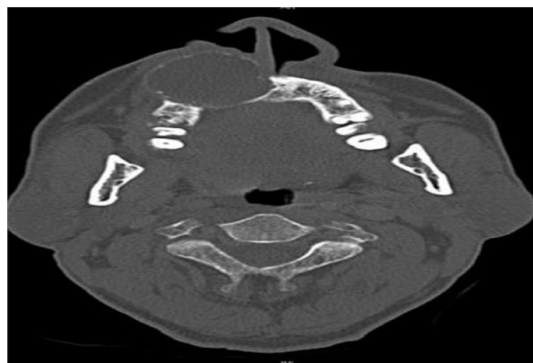

Figure 5: CT scan revealing expansion of buccal and lingual cortical plates, displacement of teeth # 12, and multiple foci of calcifications.

Based on clinical and radiographical findings with presence of fine calcifications a provisional diagnosis of calcifying epithelial odontogenic cyst (CEOC) was given, with a differential diagnosis of calcifying epithelial odontogenic tumor (CEOT) and AOT. Conservative surgical enucleation was done and the excised specimen was sent to histopathological examination. (Figure 6)

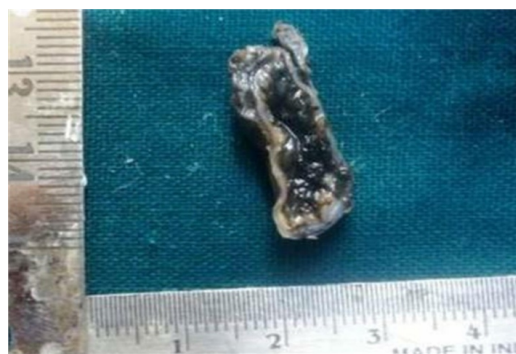
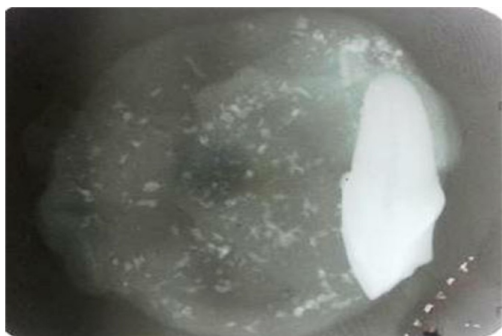
Figure 6: Excised Specimen.

Before histopathological examination, a radiogra-

phic image of excised specimen was taken which revealed multiple foci of calcifications. (Figure 7)



**Figure 7:** A radiographic image of excised specimen showing multiple calcifications.

Histopathological examination revealed sheets of polygonal cells dispersed throughout the fibrous connective tissue stroma. The odontogenic columnar epithelial cells arranged in the form of numerous rosettes, cords, duct-like structures and central lumen filled with eosinophilic material. In other places, amorphous calcifications, dentinoid-like material, and hemorrhagic-like areas were noted, which confirmed the diagnosis of AOT. (Figure 8) The patient is under follow up since 2 years without recurrence. (Figure 9)

**Discussion**

AOT is a non-invasive, benign odontogenic lesion. It is most commonly seen in young patients with female predominance with a ratio of 1.9:1. [8] But in our case, the patient was a 50 years old man. Its occurrence in maxilla is twice as frequent as that of mandible, and anterior part of jaw is more frequently involved than posterior part, [8] as in the present case. An unerupted maxillary canine is the tooth most commonly associated with AOT. [8]

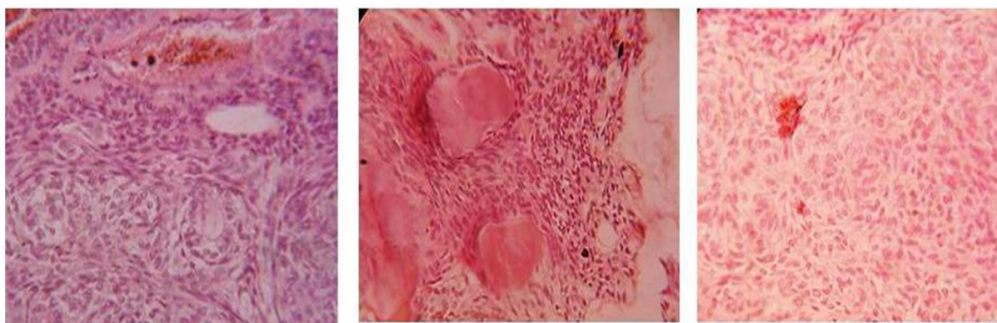
But in our case, it was not associated with any unerupted tooth. Adenomatoid odontogenic tumor is

also called ‘2/3<sup>rd</sup> tumor,’ because 2/3<sup>rd</sup> of it occur in the maxilla, 2/3<sup>rd</sup> occur in young females, 2/3<sup>rd</sup> of the cases are associated with un-erupted teeth, and 2/3<sup>rd</sup> of the affected teeth are canines. [9]

The AOT has three clinicopathologic variants, namely intraosseous follicular, intraosseous extrafollicular, and extraosseous/peripheral. The intraosseous follicular type (accounting 73% of all AOT cases) is associated with an impacted tooth whereas intraosseous extrafollicular type (accounting 24%) has no relation with an impacted tooth, as in the case we present here and the peripheral variant (accounting 3%) is attached to the gingival structures. [10-11] The tumors are usually asymptomatic and are small within the dimensions of 1.5 to 3 cm, [11] in our case the tumor was larger than that mentioned in the literature.

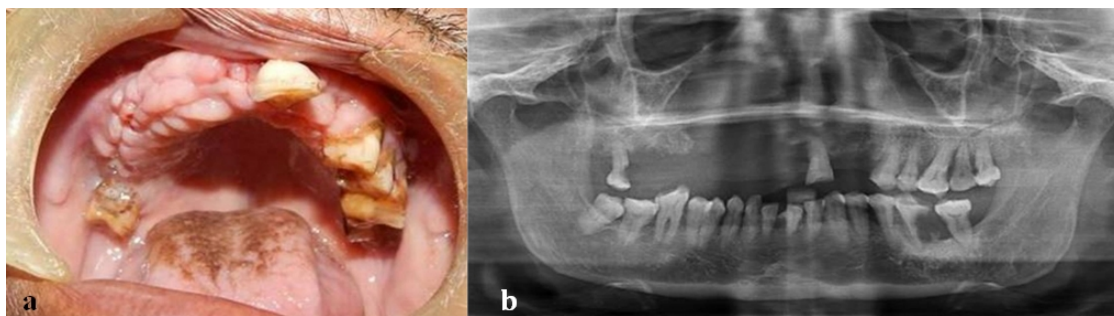
Radiographically, unilocular radiolucency with a distinct radiopaque border is a characteristic feature of AOT. [11-12] It is usually associated with the displacement of teeth which was evident in our case. Root resorption is seldom seen, [12] but it was reported in our case. AOT may show multiple minute variable shaped calcifications or radiopaque foci, which may appear like a cluster of small pebbles. Approximately 78% of the lesions are associated with these calcified deposits [11] which was evident in our case. Dare *et al.* [13] found that the intraoral periapical radiograph is the best radiograph to show radiopacities in AOT as discrete foci having a flocculent pattern within radiolucency even with minimal calcified deposits, when compared to a panoramic radiograph, as seen in the present case. The extra-osseous AOTs are rarely detected radiographically. All the variants of AOT show identical histological features. [11, 14]

WHO has described the histological features of the tumor as a tumor of odontogenic epithelium with duct like structures and with varying degrees of inducti-



**Figure 8:** Photomicrograph showing histologic features. (a) Duct like structures (b) Calcified masses (c) Rossete pattern.





**Figure 9a:** Post-operative intra-oral photography, **b:** Post-operative panoramic radiography.

ve change in the connective tissue. AOT is usually surrounded by a well developed connective tissue capsule. It may present as a solid mass, a single large cystic space, or as numerous small cystic spaces. The tumor is composed of spindle-shaped or polygonal cells forming sheets and whorled masses in a scant connective tissue stroma. The amorphous eosinophilic material is seen between the epithelial cells, as well as in the center of the rosette-like structure. The characteristic duct-like structures are lined by a single row of columnar epithelial cells, the nuclei of which are polarized away from the central lumen, our case was evident with these common features reported in the literature. The lumen may be empty or contain amorphous eosinophilic material. [9] Dystrophic calcification in varying amounts and in different forms is usually encountered in most AOTs within the lumina of the duct like structures, scattered among epithelial masses or in the stroma. The immunohistochemical studies report that the slow growth, benign behavior, and low tendency to recur are clearly related to the low cellular proliferation observed on performing immunostaining for the Ki67 antigen. [14]

Interestingly, our present case had some unusual clinical, radiographical and histopathological features that distinguished it from normal types of AOT. Firstly, AOTs are slow growing and relatively small in size, but in the present case showed unusual rapid growth to more than 3cm within one month, as reported by the patient. Secondly, radiographical examination reveals a unilocular radiolucency with distinct radiopaque borders with calcifications and associated with root resorption of #11, # 21, which is quite uncommon. In fact, to our knowledge, only 5 cases of AOT with root resorption have been reported. [9]

Conservative surgical enucleation or curettage is the treatment of choice. For treating periodontal intra-

bony defects caused by AOT, guided tissue regeneration with membrane technique is suggested after complete removal of the tumor. [15] Our patient is healthy without recurrence and is under follow-up after local excision.

### Conclusion

The case we discussed emphasizes extrafollicular variant of AOT which is very rare. It is commonly referred as “2/3<sup>rd</sup> tumor” with more predominance in maxilla, affecting commonly young adults i.e. second decade of life. It should also be considered in the differential diagnosis affecting the age group of older individuals, although its incidence is low.

### Conflicts of Interest

There is no conflict of interest in relation to this study.

### References

- [1] Komal K, Vibhakar A. Mural adenomatoid odontogenic tumor in the mandible: A rare case. *Int J Oral Maxillofac Pathol.* 2011; 2: 35-39.
- [2] Lucas RB. *Pathology of tumors of the oral tissues.* 4th ed. Edinburgh, Scotland: Churchill Livingstone; 1984. P. 66.
- [3] Harbitz F. On cystic tumors of the maxilla, and especially on adamantine cystadenomas (adamantomas). *Dental Cosmos.* 1915; 15: 1081-1093.
- [4] Stafne EC. Epithelial tumors associated with developmental cysts of the maxilla: report of 3 cases. *Oral Surg Oral Med Oral Pathol.* 1948; 1: 887.
- [5] Philipsen HP, Birn H. Adenomatoid odontogenic tumour, ameloblastic adenomatoid tumor or adenoameloblastoma. *Acta Pathol Microbiol Scand.* 1969; 75: 375-398.
- [6] Max RE, Stern D. *Oral and maxillofacial pathology: a rationale for diagnosis and treatment.* 2th ed. Quintessen-

- ce Publishing: Hanover Park; 2003. p. 609-612.
- [7] Unal T, Cetingul E, Gunbay T. Peripheral Adenomatoid odontogenic tumor: Birth of a term. *J Clin Pediatr Dent.* 1995; 19: 139-142.
- [8] Philipsen HP, Reichart PA. Adenomatoid odontogenic tumour: facts and figures. *Oral Oncol.* 1999; 35: 125-131.
- [9] Garg D, Palaskar S, Shetty VP, Bhushan A. Adenomatoid odontogenic tumor - hamartoma or true neoplasm: a case report. *J Oral Sci.* 2009; 51: 155-159.
- [10] Philipsen HP, Srisuwan T, Reichart PA. Adenomatoid odontogenic tumor mimicking a periapical (radicular) cyst: a case report. *Oral Surg Oral Med Oral Pathol Oral Radiol Endod.* 2002; 94: 246-248.
- [11] Yilmaz N, Acikgoz A, Celebi N, Zengin AZ, Gunhan O. Extrafollicular adenomatoid odontogenic tumor of the mandible: report of a case. *Eur J Dent.* 2009; 3: 71-74.
- [12] Panjwani S, Bagewadi A, Keluskar V. An unusual site of Adenomatoid Odontogenic Tumor: A rare case report. *J Int Oral Health.* 2010; 2: 71-76.
- [13] Dare A, Yamaguchi A, Yoshiki S, Okano T. Limitations of panoramic radiography in diagnosing Adenomatoid odontogenic tumor. *Oral Surg Oral Med Oral Pathol Oral Radiol Endod.* 1994; 77: 662-668.
- [14] Ajagbe HA, Daramola JO, Junaid TA, Ajagbe AO. Adenomatoid odontogenic tumor in a black African population: report of thirteen cases. *J Oral Maxillofac Surg.* 1985; 43: 683-687.
- [15] Blumenthal NM, Mostofi R. Repair of an intrabony defect from an adenomatoid odontogenic tumor. *J Periodontol.* 2000; 71: 1637-1640.

**Case Report****Extrafollicular Adenomatoid Odontogenic Tumor: An Unusual Case Presentation**Vinay Kumar Reddy Kundoor<sup>1</sup>, Kotya Naik Maloth<sup>1</sup>, Nagu Naik Guguloth<sup>2</sup>, Sunitha Kesidi<sup>1</sup><sup>1</sup> Dept. of Oral Medicine and Radiology, Mamata Dental College, Khammam, Telangana, India.<sup>2</sup> Post Graduate, Dept. of Oral Medicine and Radiology, Mamata Dental College, Khammam, Telangana, India.**KEY WORDS**Adenoameloblastoma;  
Extrafollicular;  
Odontogenic Tumors;

Received: April 2015;

Received in revised form: August 2015;

Accepted: October 2015;

**ABSTRACT**

Adenomatoid odontogenic tumor (AOT) is an uncommon tumor of odontogenic origin and often misdiagnosed as an odontogenic cyst. It is predominantly found in young female patients, located more often in maxilla, and in most cases associated with an unerupted permanent tooth. There are three variants of AOT namely follicular, extra follicular, and peripheral. We report an unusual case of extrafollicular AOT in maxilla of a 50-year old male patient.

**Corresponding Author:** Kotya Naik Maloth, Dept. of Oral Medicine and Radiology, India.  
Email: [dr.kotyanaik.maloth@gmail.com](mailto:dr.kotyanaik.maloth@gmail.com) Tel: +91-8742-235161

**Cite this article as:** Reddy Kundoor VK., Maloth KN., Guguloth NK., Kesidi S. Extrafollicular Adenomatoid Odontogenic Tumor: An Unusual Case Presentation. *J Dent Shiraz Univ Med Sci.*, 2016 December; 17(4): 370-374.

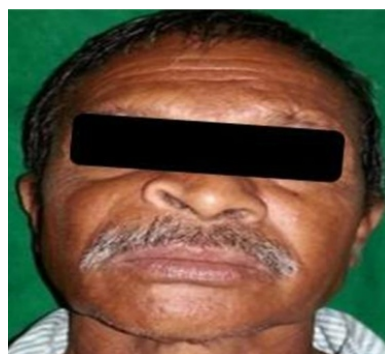**Introduction**

Adenomatoid odontogenic tumor (AOT) is an uncommon, benign and slow growing tumor, represents 3% of all odontogenic tumors. [1] Steensland first described it in 1905. [1] Dreibladdt described it as pseudo-adenameloblastoma in 1907 [2] and Harbitz in 1915 as cystic adamantoma. [3] In 1948 Stafne considered AOT as a distinct entity and others believed it to be a variant of ameloblastoma. [4] Philipson and Birn in 1969 declined this thought and suggested the name 'adenomatoid odontogenic tumor'. [5] The World Health Organization (WHO) in 1971 adopted the term 'adenomatoid odontogenic tumor'. In 2003, Max and Stern coined the name 'adenomatoid odontogenic cyst'. [6] Various other terms used to describe this tumor and Unal *et al.* listed the terms such as ameloblastic adenomatoid tumor, adamantinoma, epithelioma adamantinum, adenoameloblastoma, and teratomatous odontoma were used before the term AOT. [7] Due to the slow growing nature and symptomless behavior of the tumor, the patient tolerates the swelling for years, until it produces as obvious deformity. Here, we report a case of extrafollicular AOT in 50-years old male patient.

**Case Report**

A 50-year-old male patient reported to our department with a complaint of swelling in his right upper front

tooth region since 1 month. The swelling increased in size within a short span of time. The patient revealed no history of pain or pus discharge associated with the swelling. Extra oral examination revealed a solitary diffuse swelling present on right middle third of the face measuring approximately about 3.5×4cm in diameter, oval in shape with shiny surface extending anterior-posteriorly from lateral surface of the nose to 4cm in front of the tragus of the ear and superior-inferiorly approximately 1cm below the lower eyelid to 1cm above the right corner of the mouth, causing obliteration of the nasolabial fold, lifting the ala of the nose with ill-defined borders. On palpation, it was non-tender, firm in consistency, non-compressible, non-reducible, non-fluctuant. (Figure 1)



**Figure 1:** Extra oral appearance of the patient.

Intra oral examination revealed a solitary swelling

located on the right side of palatal aspect of maxilla, measuring approximately 2.5×3 cm in diameter, roughly oval in shape with shiny surface. Swelling was extending antero-posteriorly from incisive papilla to approximately 2cm in front of fovea palatine and medio-laterally extending from mid palatine raphae till the attached gingiva of #13, #14 and extending buccally causing obliteration of buccal vestibule. On palpation, swelling was moderately tender, soft in consistency; compressible and non-reducible. (Figure 2)



Figure 2: Intra oral appearance of the lesion.

On aspiration, a clear straw color aspirate was obtained. Based on the above findings, a provisional diagnosis of unicystic ameloblastoma was considered.

Blood investigation was non contributory. Radiographic investigations were done; panoramic radiography revealed a well-defined unilocular radiolucency with sclerotic border, measuring approx. 4x3 cm in diameter causing displacement of #12, #13 and root resorption in relation to #11, #21 and also causing obliteration of maxillary sinus. (Figure 3)



Figure 3: Panoramic radiography showing well-defined unilocular radiolucency in the anterior maxilla.

Occlusal radiograph revealed an ill-defined radiolucency measuring approximately 3×4cm in diameter showing displacement of #12 with buccal cortical expansion and multiple foci of calcifications. (Figure 4)

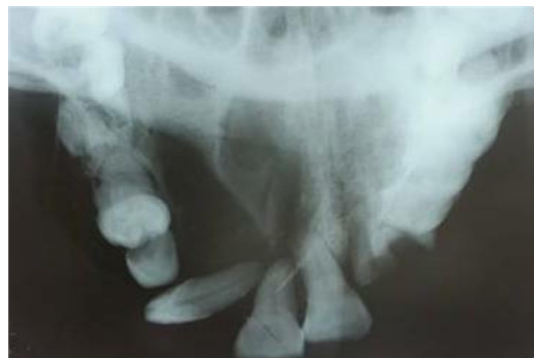

Figure 4: Maxillary occlusal radiograph showing ill-defined radiolucency with buccal cortical expansion.

Computer tomography (CT) revealed a well-defined hypodense area on right side of maxilla measuring about 4×3 cm in diameter. (Figure 5)



Figure 5: CT scan revealing expansion of buccal and lingual cortical plates, displacement of teeth # 12, and multiple foci of calcifications.

Based on clinical and radiographical findings with presence of fine calcifications a provisional diagnosis of calcifying epithelial odontogenic cyst (CEOC) was given, with a differential diagnosis of calcifying epithelial odontogenic tumor (CEOT) and AOT. Conservative surgical enucleation was done and the excised specimen was sent to histopathological examination. (Figure 6)



Figure 6: Excised Specimen.

Before histopathological examination, a radiogra-

phic image of excised specimen was taken which revealed multiple foci of calcifications. (Figure 7)



**Figure 7:** A radiographic image of excised specimen showing multiple calcifications.

Histopathological examination revealed sheets of polygonal cells dispersed throughout the fibrous connective tissue stroma. The odontogenic columnar epithelial cells arranged in the form of numerous rosettes, cords, duct-like structures and central lumen filled with eosinophilic material. In other places, amorphous calcifications, dentinoid-like material, and hemorrhagic-like areas were noted, which confirmed the diagnosis of AOT. (Figure 8) The patient is under follow up since 2 years without recurrence. (Figure 9)

**Discussion**

AOT is a non-invasive, benign odontogenic lesion. It is most commonly seen in young patients with female predominance with a ratio of 1.9:1. [8] But in our case, the patient was a 50 years old man. Its occurrence in maxilla is twice as frequent as that of mandible, and anterior part of jaw is more frequently involved than posterior part, [8] as in the present case. An unerupted maxillary canine is the tooth most commonly associated with AOT. [8]

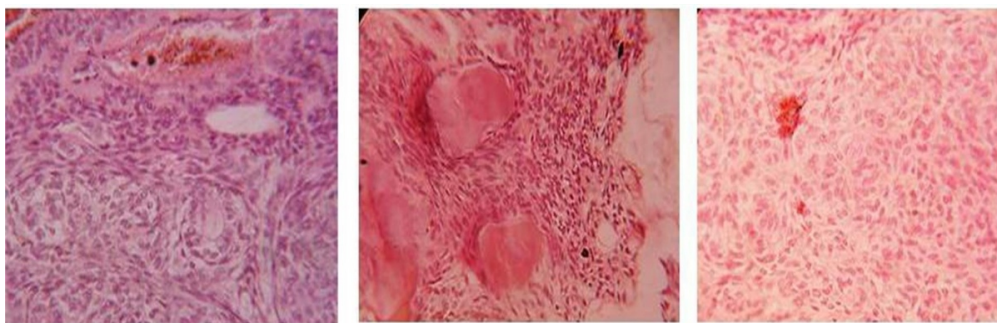
But in our case, it was not associated with any unerupted tooth. Adenomatoid odontogenic tumor is

also called ‘2/3<sup>rd</sup> tumor,’ because 2/3<sup>rd</sup> of it occur in the maxilla, 2/3<sup>rd</sup> occur in young females, 2/3<sup>rd</sup> of the cases are associated with un-erupted teeth, and 2/3<sup>rd</sup> of the affected teeth are canines. [9]

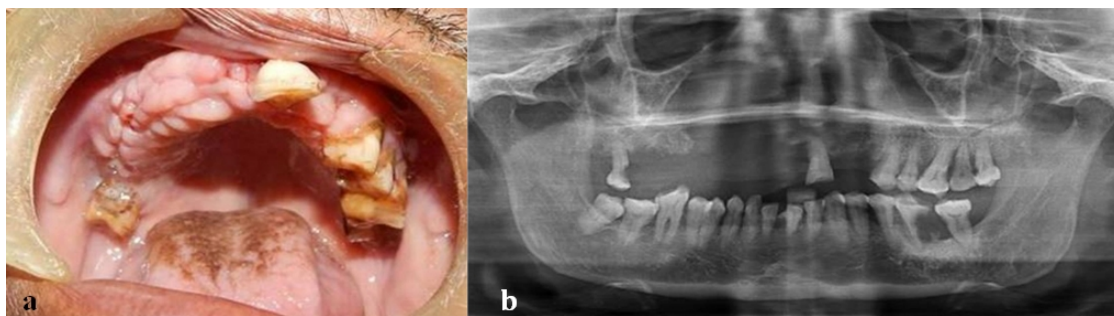
The AOT has three clinicopathologic variants, namely intraosseous follicular, intraosseous extrafollicular, and extraosseous/peripheral. The intraosseous follicular type (accounting 73% of all AOT cases) is associated with an impacted tooth whereas intraosseous extrafollicular type (accounting 24%) has no relation with an impacted tooth, as in the case we present here and the peripheral variant (accounting 3%) is attached to the gingival structures. [10-11] The tumors are usually asymptomatic and are small within the dimensions of 1.5 to 3 cm, [11] in our case the tumor was larger than that mentioned in the literature.

Radiographically, unilocular radiolucency with a distinct radiopaque border is a characteristic feature of AOT. [11-12] It is usually associated with the displacement of teeth which was evident in our case. Root resorption is seldom seen, [12] but it was reported in our case. AOT may show multiple minute variable shaped calcifications or radiopaque foci, which may appear like a cluster of small pebbles. Approximately 78% of the lesions are associated with these calcified deposits [11] which was evident in our case. Dare *et al.* [13] found that the intraoral periapical radiograph is the best radiograph to show radiopacities in AOT as discrete foci having a flocculent pattern within radiolucency even with minimal calcified deposits, when compared to a panoramic radiograph, as seen in the present case. The extra-osseous AOTs are rarely detected radiographically. All the variants of AOT show identical histological features. [11, 14]

WHO has described the histological features of the tumor as a tumor of odontogenic epithelium with duct like structures and with varying degrees of inducti-



**Figure 8:** Photomicrograph showing histologic features. (a) Duct like structures (b) Calcified masses (c) Rossete pattern.



**Figure 9a:** Post-operative intra-oral photography, **b:** Post-operative panoramic radiography.

ve change in the connective tissue. AOT is usually surrounded by a well developed connective tissue capsule. It may present as a solid mass, a single large cystic space, or as numerous small cystic spaces. The tumor is composed of spindle-shaped or polygonal cells forming sheets and whorled masses in a scant connective tissue stroma. The amorphous eosinophilic material is seen between the epithelial cells, as well as in the center of the rosette-like structure. The characteristic duct-like structures are lined by a single row of columnar epithelial cells, the nuclei of which are polarized away from the central lumen, our case was evident with these common features reported in the literature. The lumen may be empty or contain amorphous eosinophilic material. [9] Dystrophic calcification in varying amounts and in different forms is usually encountered in most AOTs within the lumina of the duct like structures, scattered among epithelial masses or in the stroma. The immunohistochemical studies report that the slow growth, benign behavior, and low tendency to recur are clearly related to the low cellular proliferation observed on performing immunostaining for the Ki67 antigen. [14]

Interestingly, our present case had some unusual clinical, radiographical and histopathological features that distinguished it from normal types of AOT. Firstly, AOTs are slow growing and relatively small in size, but in the present case showed unusual rapid growth to more than 3cm within one month, as reported by the patient. Secondly, radiographical examination reveals a unilocular radiolucency with distinct radiopaque borders with calcifications and associated with root resorption of #11, # 21, which is quite uncommon. In fact, to our knowledge, only 5 cases of AOT with root resorption have been reported. [9]

Conservative surgical enucleation or curettage is the treatment of choice. For treating periodontal intra-

bony defects caused by AOT, guided tissue regeneration with membrane technique is suggested after complete removal of the tumor. [15] Our patient is healthy without recurrence and is under follow-up after local excision.

### Conclusion

The case we discussed emphasizes extrafollicular variant of AOT which is very rare. It is commonly referred as “2/3<sup>rd</sup> tumor” with more predominance in maxilla, affecting commonly young adults i.e. second decade of life. It should also be considered in the differential diagnosis affecting the age group of older individuals, although its incidence is low.

### Conflicts of Interest

There is no conflict of interest in relation to this study.

### References

- [1] Komal K, Vibhakar A. Mural adenomatoid odontogenic tumor in the mandible: A rare case. *Int J Oral Maxillofac Pathol.* 2011; 2: 35-39.
- [2] Lucas RB. *Pathology of tumors of the oral tissues.* 4th ed. Edinburgh, Scotland: Churchill Livingstone; 1984. P. 66.
- [3] Harbitz F. On cystic tumors of the maxilla, and especially on adamantine cystadenomas (adamantomas). *Dental Cosmos.* 1915; 15: 1081-1093.
- [4] Stafne EC. Epithelial tumors associated with developmental cysts of the maxilla: report of 3 cases. *Oral Surg Oral Med Oral Pathol.* 1948; 1: 887.
- [5] Philipsen HP, Birn H. Adenomatoid odontogenic tumour, ameloblastic adenomatoid tumor or adenoameloblastoma. *Acta Pathol Microbiol Scand.* 1969; 75: 375-398.
- [6] Max RE, Stern D. *Oral and maxillofacial pathology: a rationale for diagnosis and treatment.* 2th ed. Quintessen-

- ce Publishing: Hanover Park; 2003. p. 609-612.
- [7] Unal T, Cetingul E, Gunbay T. Peripheral Adenomatoid odontogenic tumor: Birth of a term. *J Clin Pediatr Dent.* 1995; 19: 139-142.
- [8] Philipsen HP, Reichart PA. Adenomatoid odontogenic tumour: facts and figures. *Oral Oncol.* 1999; 35: 125-131.
- [9] Garg D, Palaskar S, Shetty VP, Bhushan A. Adenomatoid odontogenic tumor - hamartoma or true neoplasm: a case report. *J Oral Sci.* 2009; 51: 155-159.
- [10] Philipsen HP, Srisuwan T, Reichart PA. Adenomatoid odontogenic tumor mimicking a periapical (radicular) cyst: a case report. *Oral Surg Oral Med Oral Pathol Oral Radiol Endod.* 2002; 94: 246-248.
- [11] Yilmaz N, Acikgoz A, Celebi N, Zengin AZ, Gunhan O. Extrafollicular adenomatoid odontogenic tumor of the mandible: report of a case. *Eur J Dent.* 2009; 3: 71-74.
- [12] Panjwani S, Bagewadi A, Keluskar V. An unusual site of Adenomatoid Odontogenic Tumor: A rare case report. *J Int Oral Health.* 2010; 2: 71-76.
- [13] Dare A, Yamaguchi A, Yoshiki S, Okano T. Limitations of panoramic radiography in diagnosing Adenomatoid odontogenic tumor. *Oral Surg Oral Med Oral Pathol Oral Radiol Endod.* 1994; 77: 662-668.
- [14] Ajagbe HA, Daramola JO, Junaid TA, Ajagbe AO. Adenomatoid odontogenic tumor in a black African population: report of thirteen cases. *J Oral Maxillofac Surg.* 1985; 43: 683-687.
- [15] Blumenthal NM, Mostofi R. Repair of an intrabony defect from an adenomatoid odontogenic tumor. *J Periodontol.* 2000; 71: 1637-1640.