

**Case Report****Immune Thrombocytopenic Purpura Detected with Oral Hemorrhage:  
a Case Report**

Tsutomu Sugiura <sup>1,2</sup>, Kazuhiko Yamamoto <sup>2</sup>, Kazuhiro Murakami <sup>2</sup>, Satoshi Horita <sup>2</sup>, Yumiko Matsusue <sup>2</sup>, Chie Nakashima <sup>1,2</sup>, Tadaaki Kirita <sup>2</sup>

<sup>1</sup> Dept. of Oral and Maxillofacial Surgery, Nara Kasuga Hospital, Nara, Japan.

<sup>2</sup> Dept. of Oral and Maxillofacial Surgery, Nara Medical University, Nara, Japan.

**KEY WORDS**

Gingiva;  
Hematoma;  
Hemorrhage;  
Purpura;

Received January 2017;  
Received in Revised form May 2017;  
Accepted March 2018;

**ABSTRACT**

Immune thrombocytopenic purpura (ITP) is an immune-mediated acquired disease found in both adults and children. It is characterized by transient or persistent decreases in the platelet count. We report a case of ITP detected based on oral hemorrhagic symptoms. The patient was a 79-year-old female with no significant past medical history. She presented with sudden onset of gingival bleeding and hemorrhagic bullae on the buccal mucosa. Gingival bleeding was difficult to control. Laboratory tests revealed severe thrombocytopenia with a platelet count as low as 2000/ $\mu$ L. Under a provisional diagnosis of a hematological disorder, she was referred to a hematologist. A peripheral smear showed normal-sized platelets. A bone marrow examination revealed increased numbers of megakaryocytes without morphologic abnormalities. The patient was diagnosed with ITP and treated with a combination of pulsed steroid therapy and high-dose immunoglobulin therapy. However, her severe thrombocytopenia was refractory to these treatments. Then, a thrombopoietin receptor agonist was begun as a second-line treatment. Her platelets rapidly increased, and no bleeding complications were reported. Because oral symptoms can be one of the initial manifestations of ITP, dentists should be familiar with the clinical appearance of ITP, and attention must be paid to detect and diagnose unidentified cases.

**Corresponding Author:** Sugiura T., Dept. of Oral and Maxillofacial Surgery, Nara Medical University, 840 Shijo-cho, Kashihara City, Nara 634-8522, Japan. Tel & Fax: +81-744-29-8875  
Email: sugiurat@naramed-u.ac.jp

**Cite this article as:** Sugiura T., Yamamoto K., Murakami K., Horita S., Matsusue Y., Nakashima C., Kirita T. Immune Thrombocytopenic Purpura Detected with Oral Hemorrhage: a Case Report. *J Dent Shiraz Univ Med Sci.*, 2018 June; 19(2): 159-163.

**Introduction**

Immune thrombocytopenic purpura (ITP), also known as idiopathic thrombocytopenic purpura, is a hematologic disorder characterized by isolated thrombocytopenia without a clinically apparent cause. The prognosis of ITP is primarily determined by the risk of spontaneous hemorrhage associated with a low platelet count. The estimated risk of fatal hemorrhage events is approximately 5% throughout the lifetime of a patient with ITP. However, the incidences of major hemorrhagic complications and of ITP-related mortality are particularly high among elderly patients with ITP. [1-2]

The characteristic clinical indicators of ITP include easy bruising of the skin, mucocutaneous lesions

such as petechiae and ecchymosis, epistaxis, and gingival bleeding. [3] In clinical practice, dentists can encounter patients with oral manifestations of ITP. Therefore, dentists must be aware of the clinical appearance of ITP to recognize the condition and successfully manage their patients. However, only a few cases of ITP in adults, particularly in elderly patients, have been reported in the oral medical literature. [3-4] We report a case of an elderly patient who presented with oral hemorrhage as an early sign of newly diagnosed ITP, which was refractory to conventional treatments.

**Case Report**

A 79-year-old female was referred to the Department of

Oral and Maxillofacial Surgery at Nara Kasuga Hospital with a complaint of spontaneous gingival bleeding around the right upper molar teeth. The patient noticed continuous bleeding at the right posterior maxilla two days earlier. She was treated with photocoagulation for hemostasis by a general dental practitioner one day earlier. However, the oozing was difficult to control and persisted. She had a medical history of hypertension, which was well controlled with benidipine hydrochloride. There was no history of any bleeding problem, and her family histories were noncontributory. She was moderately nourished. Her vital signs were normal. Extraoral examination revealed petechial hemorrhage over the lower legs (Figure 1).

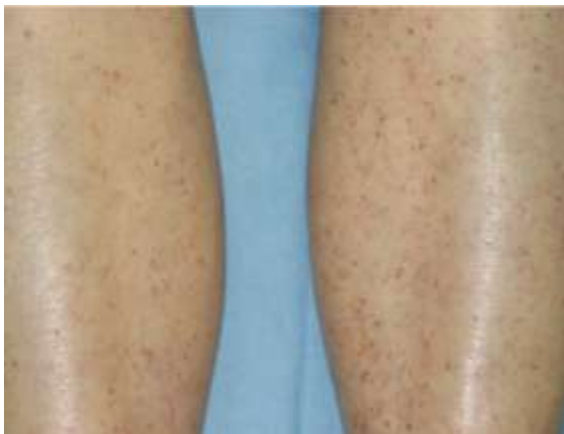

Figure 1: Petechial spots over the lower legs.

There was no obvious lymphadenopathy. Intraoral

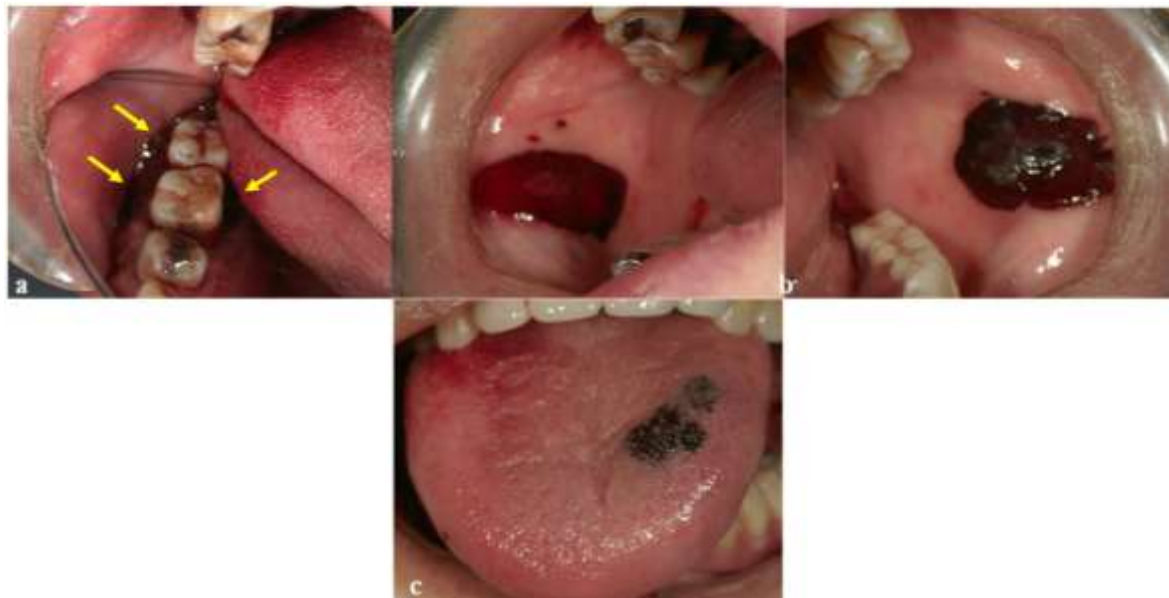

Figure 2: Intraoral findings. (a) Bleeding from the gingiva around the right upper molars (mirror image), (b) hemorrhagic bullae on both sides of the buccal mucosa, and (c) ecchymosis on the dorsum of the tongue

examination revealed bleeding from the gingiva around the right upper first and second molars, large hemorrhagic bullae on both sides of the buccal mucosa, and ecchymosis on the dorsum of the tongue (Figure 2). A complete hemogram revealed severe thrombocytopenia, with a platelet count as low as 2000/ $\mu$ L. Bleeding time, prothrombin time, and partial thromboplastin time were normal. A provisional diagnosis of a hematological disorder was made.

The patient was immediately referred to the Department of Hematology at Takanojima Central Hospital and was admitted there. A peripheral blood smear revealed no abnormalities in differential leukocyte count or erythrocytic morphology (Table 1).

Table 1: Laboratory data on admission

Hematology		Coagulation	
WBC	6800/ $\mu$ L	PT-INR	1.01
Neu	70.9%	APTT	28.5 sec
Eos	0.4%	D-dimer	2.9 $\mu$ g/mL
Baso	0.3%	Blood chemistry	
Mono	8.7%	TP	6.9 g/dL
Lym	19.7%	Alb	4.2 g/dL
RBC	$353 \times 10^4$ / $\mu$ L	ALT	16 U/L
Hb	11.8 g/dL	AST	14 U/L
Ht	34.0%	T.bil	0.8 mg/dL
PLT	$0.2 \times 10^4$ / $\mu$ L	BUN	17.6 mg/dL
Reti	15.4%	Cr	0.6 mg/dL

No findings indicative of disseminated intravascular coagulation (DIC) were detected. A bone marrow

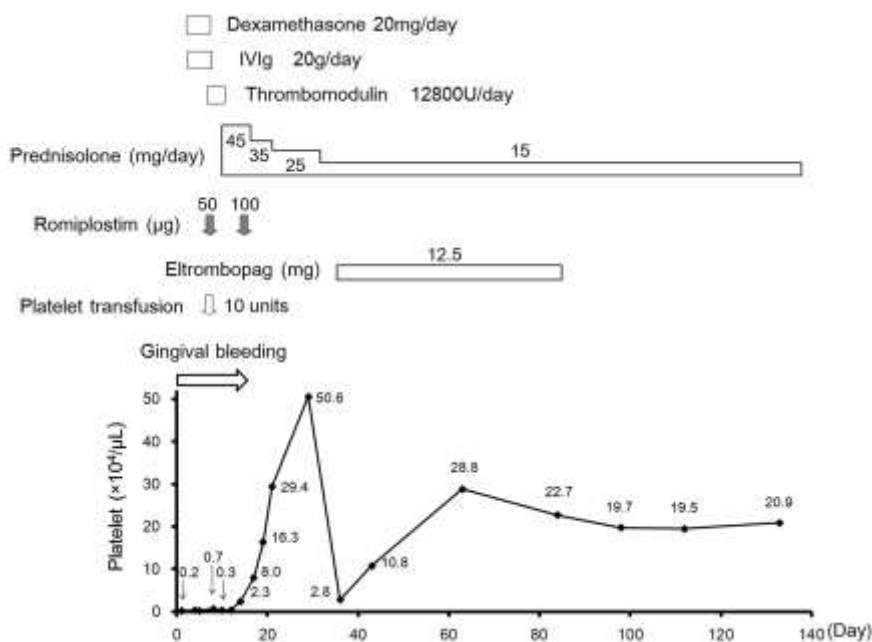


Figure 3: Clinical course of and therapy administered to the patient

examination revealed increased numbers of megakaryocytes without morphologic abnormality. A urea breath test for detection of *Helicobacter pylori* (*H. pylori*) was negative. Based on these findings, a final diagnosis of ITP was made.

On day 3, pulsed doses of dexamethasone (20 mg/day) were started for 4 days. On day 4, high-dose intravenous immunoglobulin (IVIg) therapy (20 g/day) was started for 5 days. On day 7, a 3-day course of intravenously administered thrombomodulin was begun for the prevention of DIC. Because severe thrombocytopenia was unresponsive to these treatments (the platelet count was below  $7000/\mu\text{L}$ ), on day 8, subcutaneous administration of  $1 \mu\text{g}/\text{kg}/\text{week}$  of the thrombopoietin receptor agonist romiplostim was begun as a second-line treatment, and ten units of platelets were transfused. Oral administration of steroid (prednisolone  $1 \text{ mg}/\text{kg}$ ) was started on day 11. The platelet count increased to  $23,000/\mu\text{L}$  on day 14, and bleeding from the gingiva was negligible. After the dose of romiplostim was increased to  $2 \mu\text{g}/\text{kg}$ , a complete response was achieved without any adverse events. The dose of prednisolone was gradually decreased. The patient's platelet count improved to  $163,000/\mu\text{L}$  on day 19, and she was discharged home on day 21. Because her platelet count decreased to  $28,000/\mu\text{L}$  2 weeks after discharge, oral administration of eltrombopag ( $12.5 \text{ mg}/\text{day}$ ) was started. Her platelet count returned to normal one week later

and then remained between  $195,000$  and  $288,000/\mu\text{L}$  during the four months of follow-up (Figure 3). Bleeding complications were not observed after discharge.

### Discussion

ITP has also been called idiopathic thrombocytopenic purpura. Thrombocytopenia is caused by platelet destruction via immune-mediated mechanisms and inadequate platelet production. The incidence of ITP in Japan is 21.6 new cases per million per year, with women being more commonly affected than men. [5] ITP has been classified based on duration (acute or chronic) and age (childhood or adult). In 2009, an International working group of experts defined the phases of ITP as newly diagnosed ITP (lasting within 3 months from diagnosis), persistent ITP (lasting between 3 and 12 months from diagnosis), and chronic ITP (lasting for more than 12 months), excluding the term "acute". [6] The phase of the present case was compatible with newly diagnosed ITP. Childhood ITP mostly presents as an acute form in the 2–10 year age group, with a peak incidence at 2 to 4 years of age. The disease is usually self-limiting, mostly occurring after a viral infection or immunization. Recovery is generally observed within six months. On the contrary, ITP in adults generally has no conceivable precipitating factor, displays a chronic course and rarely resolves spontaneously. [2-3]

Diagnosis of ITP requires exclusion of other etiol-

ogies for isolated thrombocytopenia. Secondary causes of thrombocytopenia include leukemia, medications, human immunodeficiency virus infection, hepatitis C, congenital causes, and others. [1] According to the American Society of Hematology, the diagnosis of ITP is based principally on history, physical examination, complete blood count, and peripheral smear examination. [7]

The symptoms and signs of ITP are highly variable and range from the fairly common presentation of an asymptomatic patient with mild bruising and mucosal bleeding (e.g., oral or gastrointestinal tract bleeding) to frank bleeding from any site. Overall, symptomatic bleeding is uncommon unless the ITP is severe (platelet count  $<30,000/\mu\text{L}$ ). Although there is a poor correlation between degree of thrombocytopenia and bleeding, severe cutaneous bleeding, prolonged epistaxis, gingival bleeding, overt hematuria, or menorrhagia may develop at platelet counts less than  $10,000/\mu\text{L}$ . [1] According to one large study [5] in which 6845 adult ITP patients were evaluated, the most common symptom was purpura (62.8%), followed by gingival bleeding (19.9%), epistaxis (10.0%), hematuria (6.6%), and melena (3.8%). Cerebral vascular bleeding was noted in 45 (0.7%) adult patients. Other oral manifestations include petechiae, ecchymosis or hematomas in easily traumatized areas such as the buccal mucosa, lateral borders of the tongue, and the border between the soft and hard palate. [3, 8]

In general, immediate therapy is not required for patients with platelet counts between 20,000 and  $50,000/\mu\text{L}$  in the absence of bleeding or predisposing comorbid conditions such as hypertension, anticoagulation, or recent surgery. [1] In patients with severe ITP, platelet count must be immediately increased above  $30,000/\mu\text{L}$  to prevent lethal bleeding symptoms because thrombocytopenia in a patient with a platelet count less than  $30,000/\mu\text{L}$  is associated with a 4.2-fold increased mortality risk compared with thrombocytopenia in a patient with a platelet count more than  $30,000/\mu\text{L}$ . [9] Therefore, especially in patients with severe ITP, rapidly increasing the platelet count is crucial. First-line therapy consists of corticosteroids, IVIg, and anti-D antibodies. High-dose IVIg therapy can quickly improve symptoms and thus represents an appropriate first-line therapy in emergencies. [2] For patients with active *H. pylori* infection, eradication of this infection should be per-

formed because a possible connection between *H. pylori* infection and ITP has been shown by some researchers. Ten to twenty percent of patients are refractory to initial treatment with corticosteroids and/or IVIg therapy. Thrombopoietin receptor agonists such as romiplostim and eltrombopag have been reported to be highly effective in patients with ITP that has relapsed after or is refractory to first-line treatment. [10]

Only a few cases of ITP have been reported in the oral medical literature [3-4, 8] because diagnosing hematologic disease merely through the symptom of oral bleeding may be difficult. A literature search of PubMed using the keywords “idiopathic (or immune) thrombocytopenic purpura”, “bleeding”, “oral”, and “case report” from 1980 to 2015 revealed 12 articles that included 12 cases of ITP detected with oral hemorrhage as the first symptom in the English literature. [4, 11-21] Eleven of the 12 patients were less than 40 years in age (3 children and 8 adults). Eight patients presented with gingival bleeding, and four patients presented with hemorrhagic bullae on the buccal mucosa or the tongue as an early sign of ITP. Gingival bleeding is one manifestation of inflammation that is commonly observed in daily clinical practice; however, uncommon bleeding of sudden onset that is difficult to control could be a sign of underlying systemic disease, such as ITP or leukemia.

In the present case, we suspected a hematologic disease based on the patient's unusual oral bleeding symptoms. Simple laboratory testing revealed severe thrombocytopenia; therefore, the patient was promptly referred to hematologists for further evaluation. She was immediately hospitalized and diagnosed as having ITP following additional examinations. Although her disease was refractory to conventional treatments, the patient was successfully managed with thrombopoietin receptor agonists and she did not develop a fatal hemorrhage event.

A case of ITP detected following the presentation of oral hemorrhage as a first symptom was reported. Dentists should be familiar with the clinical appearance of ITP, and attention must be paid to detect previously unidentified cases. When uncommon gingival bleeding, hemorrhagic bullae and hematomas in the oral cavity are observed, dentists should order appropriate hematological tests to rule out or recognize hemorrhagic dis-

ease to provide patients with immediate referrals to hematologists.

### Acknowledgments

The authors gratefully acknowledge Dr. Shoko Kobayashi of the Department of Hematology at Takanohara Central Hospital for her valuable advice.

### Conflict of Interest

The authors confirm that this article's content has no conflict of interest.

### References

- [1] Cines DB, Bussel JB. How I treat idiopathic thrombocytopenic purpura (ITP). *Blood*. 2005; 106: 2244-2251.
- [2] Uchiyama M, Hattori A, Tanaka T, Miyaji T, Matsuki Y, Fujii T, et al. Acute idiopathic thrombocytopenic purpura complicated with diffuse alveolar hemorrhage in an elderly patient. *Intern Med*. 2009; 48: 1449-1452.
- [3] Sangwan A, Tewari S, Narula SC, Sharma RK, Sangwan P. Significance of periodontal health in primary immune thrombocytopenia- a case report and review of literature. *J Dent (Tehran)*. 2013; 10: 197-202.
- [4] Themistocleous E, Ariyaratnam S, Duxbury AJ. Acute idiopathic thrombocytopenic purpura: a case report. *Dent Update*. 2004; 31: 92-96.
- [5] Kurata Y, Fujimura K, Kuwana M, Tomiyama Y, Murata M. Epidemiology of primary immune thrombocytopenia in children and adults in Japan: a population-based study and literature review. *Int J Hematol*. 2011; 93: 329-335.
- [6] Rodeghiero F, Stasi R, Gernsheimer T, Michel M, Provan D, Arnold DM, et al. Standardization of terminology, definitions and outcome criteria in immune thrombocytopenic purpura of adults and children: report from an international working group. *Blood*. 2009; 113: 2386-2393.
- [7] Neunert C, Lim W, Crowther M, Cohen A, Solberg L Jr, Crowther MA; American Society of Hematology. The American Society of Hematology 2011 evidence-based practice guideline for immune thrombocytopenia. *Blood*. 2011; 117: 4190-4207.
- [8] Vaisman B, Medina AC, Ramirez G. Dental treatment for children with chronic idiopathic thrombocytopenic purpura: a report of two cases. *Int J Paediatr Dent*. 2004; 14: 355-362.
- [9] Portielje JE, Westendorp RG, Kluin-Nelemans HC, Brand A. Morbidity and mortality in adults with idiopathic thrombocytopenic purpura. *Blood*. 2001; 97: 2549-2554.
- [10] Bussel JB, Buchanan GR, Nugent DJ, Gnarr DJ, Bomgaars LR, Blanchette VS, et al. A randomized, double-blind study of romiplostim to determine its safety and efficacy in children with immune thrombocytopenia. *Blood*. 2011; 118: 28-36.
- [11] Fotos PG, Graham WL, Bowers DC, Perfetto SP. Chronic autoimmune thrombocytopenic purpura. A 3-year study. *Oral Surg Oral Med Oral Pathol*. 1983; 55: 564-567.
- [12] James WD, Guiry CC, Grote WR. Acute idiopathic thrombocytopenic purpura. *Oral Surg Oral Med Oral Pathol*. 1984; 57: 149-151.
- [13] Benson P, Macpherson DW. Idiopathic thrombocytopenic purpura presenting with infraorbital nerve paraesthesia. *Int J Oral Maxillofac Surg*. 1990; 19: 263-265.
- [14] Ripamonti U, Petit JC, Penfold G, Lemmer J. Periodontal manifestations of acute autoimmune thrombocytopenic purpura. A case report. *J Periodontol*. 1986; 57: 429-432.
- [15] Reddy VV, Rawal YB. Childhood thrombocytopenic purpura--review and a case report. *Indian J Dent Res*. 1996; 7: 103-106.
- [16] Owais Z, Dane J, Cumming CG. Unprovoked periodontal hemorrhage, life-threatening anemia and idiopathic thrombocytopenia purpura: an unusual case report. *Spec Care Dentist*. 2003; 23: 58-62.
- [17] Hegde RJ, Parimala K, Shivaprakash. Acute idiopathic thrombocytopenic purpura in childhood: a case report. *J Indian Soc Pedod Prev Dent*. 2003; 21: 42-44.
- [18] Helms AE, Schaffer RI. Idiopathic thrombocytopenic purpura with black oral mucosal lesions. *Cutis*. 2007; 79: 456-458.
- [19] Martini MZ, Lopez JS Jr, Gendler JL, da Fonseca EV, Soares HA, Franzi SA. Idiopathic thrombocytopenic purpura presenting as post-extraction hemorrhage. *J Contemp Dent Pract*. 2007; 8: 43-49.
- [20] Namdev R, Dutta SR, Singh H. Acute immune thrombocytopenic purpura triggered by insect bite. *J Indian Soc Pedod Prev Dent*. 2009; 27: 58-61.
- [21] Kayal L, Jayachandran S, Singh K. Idiopathic thrombocytopenic purpura. *Contemp Clin Dent*. 2014; 5: 410-414.