

**Original Article****Assessing the Accuracy of Caries Diagnosis in Bitewing Radiographs Using Different Reproduction Media**Sadaf Adibi<sup>1</sup>, Anita Amrollahi<sup>2</sup>, Ali Dehghani Nazhvani<sup>3</sup>, Najmeh Movahhedian<sup>1</sup><sup>1</sup> Dept. of Oral and Maxillofacial Radiology, School of Dentistry, Shiraz University of Medical Sciences, Shiraz, Iran.<sup>2</sup> Undergraduate Student, School of Dentistry, International branch, Shiraz University of Medical Sciences, Shiraz, Iran.<sup>3</sup> Dept. of Oral and Maxillofacial Pathology, Biomaterials Research Center, School of Dentistry, Shiraz University of Medical Sciences, Shiraz, Iran.**KEY WORDS**Dental caries;  
Film;  
Paper;  
Bitewing radiography;**ABSTRACT****Statement of the Problem:** After introducing digital radiography, practitioners started reading radiographs from computer monitors; however, many still prefer hard-copy radiographs.**Purpose:** This study aimed to assess the possible superiority of either type of radiograph recording media (computer monitor, film, or paper) in diagnosis and perception of the depth of the cariogenic lesions.**Materials and Method:** Twenty digital bitewing radiographs, obtained from 200 posterior extracted teeth, were displayed on an LG monitor and printed on paper and film using Kodak printers. Two observers independently measured lesions depth on the images. Serial sections of teeth were obtained and the sections were evaluated by a stereomicroscope to determine the actual depth of cariogenic lesions. The efficacy of the each medium was assessed by determining its specificity and sensitivity in comparison with those of histological images. Weighted kappa coefficients and the ROC analysis were used for the statistical analysis.**Results:** Strong intra- and inter-observer agreements (0.818 to 0.958, 0.77 to 0.85) were found for all detection methods. The highest Az value was obtained with the monitor-displayed images (Az: 0.879); however, differences between detection methods were not statistically significant ( $p > 0.05$ ).**Conclusion:** Monitor-displayed bitewing radiographs, paper, and film prints used in our study performed similarly in the detection of proximal caries.**Corresponding Author:** Movahhedian N., Dept. of Oral and Maxillofacial Pathology, Biomaterial Research Center, School of Dentistry, Shiraz University of Medical Sciences, Shiraz, Iran.  
Tel: +98- 7136263193 Fax: +98-713270325 Email: sadafadibi@gmail.comReceived February 2017;  
Received in Revised Form August 2017;  
Accepted September 2017;

Cite this article as: Adibi S., Amrollahi A., Dehghani Nazhvani A., Movahhedian N. Assessing the Accuracy of Caries Diagnosis in Bitewing Radiographs Using Different Reproduction Media. J Dent Shiraz Univ Med Sci., 2018 September; 19(3):174-180.

**Introduction**

Among the various methods used today in the diagnosis of caries, probing, visual examination, intraoral film, and digital receptors are the most common in routine clinical practice. [1-2] Radiographs are generally recommended for detection of proximal carious lesions [3-4] and amongst them, bitewing radiographs has become the most frequently used intraoral radiographic examination. [5] Currently, conventional film radiographs are about to be replaced by digital imaging and previous

studies have shown that all digital receptors are diagnostically comparable to conventional film images for detecting proximal caries. [1, 6-9]

Different systems exist for transmitting diagnostic information between offices, including Picture Archiving and Communication System (PACS) and hard copies; however, many dentists still prefer to use hard copies of radiographs in their working environment as they are accustomed to reading radiographs and diagnosing the problem on hard copy; [10] furthermore, many of

them do not have access to monitors. [11] Besides, the patients' chair-side is not optimal for analyzing digital images due to the rather bright and non-standardized background light [12] and dentists will hardly ever adjust the window levels provided by the viewing software. This can also be true for hard copies printed on films. [13] Hard copy prints can be produced on either film or paper; although, high-quality paper prints of digital images can be produced at one-sixth to one-tenth the cost of laser film production. [14-15] Moreover, paper records are observed to be less affected by the typical working environment. [13]

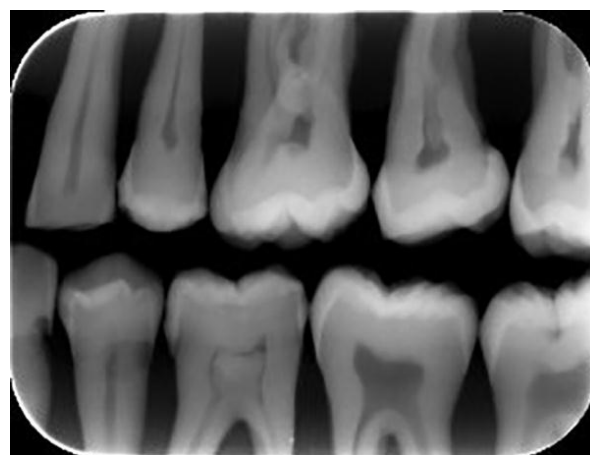
Few studies have evaluated the accuracy of different monitors [16-18] and printers [12, 19] in the diagnosis of proximal caries. A study on five flat panel monitors comparing their images with images observed from the microscopic slides concluded that they did not differ in overall accuracy for detection of proximal caries. [17] Another study evaluated the diagnostic quality of three inkjet printers for proximal caries detection. The printers were able to reproduce radiographs at an optimal quality in a dental office. [12] To the best of our knowledge, there is no report comparing these three interim recording media (monitor, printed film, or paper) for proximal caries detection. A previous study revealed few and inconsistent differences between printed images from Kodak 1200 inkjet printer on glossy paper and blue transparent film and the original monitor-displayed images for third molar assessment in panoramic images. [11] In another study, it has been shown that while the diagnostic accuracy of paper prints is similar to film prints and monitor displayed images in musculoskeletal and abdominal radiography, these paper prints are not recommended for chest radiography. [10] Studies comparing soft copy and hard copy mammograms showed controversial results. While a study showed better performance of digital images, [20] others showed no significant difference between two modalities. [21-22] Considering the controversies among previous studies which compared these three media and taking into account the need for better methods of proximal caries diagnosis, this study was designed to verify if any radiograph recording media (monitor, film, or paper) performs superiorly in diagnosing caries and perceiving the depth of cariogenic lesions.

## Materials and Method

Our study comprised 200 human canine, premolar, and molar teeth with and without caries that had been extracted within three weeks for periodontal or orthodontic reasons. Calculus and debris were removed using Cavitron and the teeth were immersed in a 5% solution of sodium hypochlorite for 20 min followed by rinsing in normal saline for 20 min in order to decontaminate. They were then stored in 10% formalin.

The teeth were randomly mounted in 40 acrylic blocks at the level of CEJ in groups of five. Approximately, 10 mm acrylic resin was around the roots in each block. The teeth were mounted so that the prominent part of the proximal surfaces were in contact as well as being at the same vertical level to simulate the normal anatomical position. The two teeth at both ends (canines, second, or third molars) were not included in the evaluations. Of the 240 proximal surfaces, 37 surfaces had obvious cavities. The clinical appearance of the remaining tooth surfaces ranged from sound to chalky or brown discolored after cleaning.

The 40 tooth blocks were then numbered and stored separately in 10% neutral buffered formalin solution. To mimic a bitewing radiograph, two tooth blocks in occlusion, using a bitewing film holder, were exposed together with a 1.0 cm thick acrylic block to simulate soft tissue (Figure 1). [23-25]



**Figure 1:** Two tooth blocks in occlusion, using a bitewing film holder, a 1.0 cm thick acrylic block, and a phosphor plate.

Digital intraoral images of the 40 block samples were obtained using size 2 phosphor plate (PP) (DigoraOptime digital imaging system; Soredex, Helsinki, Finland). The plates were stored in lightproof envelopes during the exposure and scanned immediately after ex-

posure using the DigoraOptime scanner and the manufacturer's software and the files were exported and saved in a tagged image file format (TIFF).

The x-ray unit used was a Planmeca Intra (Helsinki, Finland) with a focal spot size of 0.7mm, 2-mm Al filtration, and a constant nominal tube potential selectable at either 60 or 70 KVP. The teeth were radiographed with their long axes perpendicular to the central ray and the operating distance between PPs and focus was 35.0 cm. Visibility of the pulpal root canal, dentine, and enamel was used as an indication of optimal image quality for all images (Figure 2). [1, 26-27]



**Figure 2:** Digital bitewing radiograph obtained by photo stimulable phosphor plate.

Twenty digital bitewing images were displayed on a 19-inch LG monitor (Flatron E1960, LG, Seoul, Korea) with a resolution of 1,360×768 pixels and 32-bit color. The display ratio of the images was 1:1. This monitor had an initial luminance level of 250 cd/m<sup>2</sup>, and a contrast ratio of 5000:1. Maximum luminance was set to 170 cd/m<sup>2</sup> based on AAPM guidelines. The viewing took place in a room with dimmed lights. The analog brightness and contrast controls on the monitors were permanently fixed during the reading sessions and further adjustment of brightness and contrast was not allowed. A cardboard simulating a black mask was attached to the monitor, so that the image could be seen by the observer corresponded to the real image size, and shielding it from the light emitted by the screen. The observers were not allowed to use the enhancement tools while scoring the teeth. Viewing distance was kept constant to about 50 cm for the observers.

Twenty digital bitewing radiographs were printed on glossy paper (DMI Paper, 21.0×29.7cm, Eastman

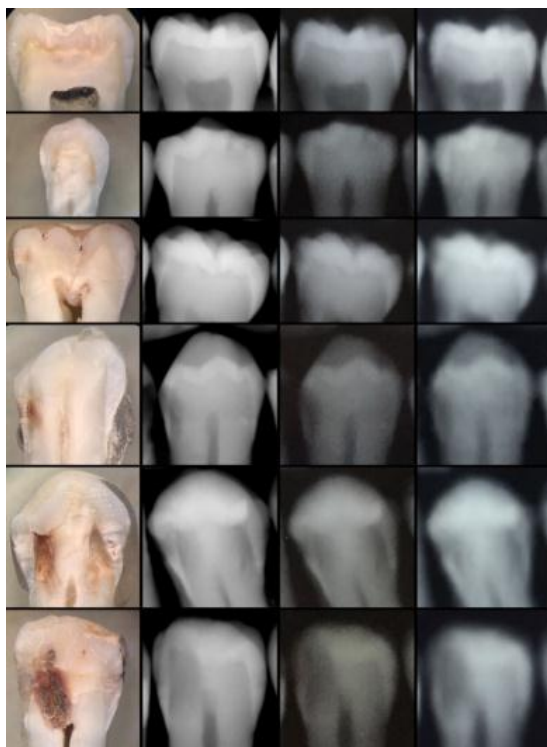
Kodak, Rochester, NY, USA) at 600 DPI using an ink jet printer (1200 Distributed Medical Imager, Eastman Kodak, Rochester, NY, USA). Moreover, film prints were obtained using 8×10inch film (Carestream dry view laser imaging film, Kodak, Rochester, NY, USA) and laser printer (Carestream dry view 6950 laser imager, Kodak, Rochester, NY, USA) at 650 PPI. Considering the design purpose of the printers, they were selected by their availability and price.

The viewing conditions for digital images and films were made as similar as possible. The films were examined on an illumination box (50×75cm) with maximum luminance of 3000 cd/m<sup>2</sup> and masked viewing but without magnification.

Two oral and maxillofacial radiologists who had at least a 5-year experience in caries interpretation on digital radiographs evaluated the images. Intra-observer agreement was assessed by having each observer view all images twice, with a 2-week interval to eliminate memory bias. The mesial and distal aspects of the three teeth located in the center of each block were assessed for caries. Each observer evaluated only one group of the test images at a time and the radiographs were selected randomly.

The observers used the following 5-point rank scale to record their level of confidence regarding the presence of proximal carious lesions as (1) for definitely no caries, (2) for probably no caries, (3) for questionable, (4) for probably caries, and (5) for definitely caries. In addition, they were asked to determine the presence or absence of proximal caries according to radiographic criteria, using a scale defined as (0) for no caries detected in the proximal surface, (1) for proximal radiolucency in enamel (enamel caries), (2) for proximal radiolucency in enamel reaching to dentine enamel junction, (3) for proximal radiolucency in outer half of dentine, (4) for proximal radiolucency in inner half of dentine, and (5) for proximal radiolucency extending to pulp (Figure 3). In order to determine the actual depth of the caries, the tooth crowns of the 120 teeth were sectioned perpendicularly to the long axis of the tooth just lower than the position of cemento-enamel junction. After cleaning and drying, the tooth crowns were individually embedded in polyacrylic resin. Each polyacrylic resin block was then sectioned (700µm thick per slice) serially and mesiodistally in parallel with the long axis of the

tooth crowns using Leitz 1600 saw microtome (Ernst. Leitz Wetzlar GmbH, Wetzlar, Germany). The tooth slices were observed with a 16× magnifying stereomicroscope BS-3060A (Changfang Optical Instrument Ltd., Shanghai, China) by two observers, both experienced in histological examination and were calibrated before evaluation. Disagreements were settled by consensus. The diagnoses were recorded based on the same radiographic 6-point scale.



**Figure 3:** Images obtained by stereomicroscope, monitor, paper, film print (from left to right), and stage 0 to 5 (top to bottom)

#### Statistical Methods

Weighted kappa coefficients were calculated to assess intra and inter-observer agreements for caries diagnosis on the three different radiographic media according to the following criteria: 0.10, no agreement; 0.10–0.40, poor agreement; 0.41–0.60, significant agreement; 0.61–0.80, strong agreement; 0.81–1.00, excellent agreement. [28] Scores were compared with the histological gold standard using receiver operating characteristic (ROC) analysis to evaluate the observer performance. The level of significance was set at 5%. The areas under the ROC curves (Az values) for each medium, observer, and reading were calculated using the MedCalc statistical software and IBM SPSS statistics 22. The efficacy of the each medium for carious lesion

detection was assessed by determining its specificity and sensitivity in comparison with those of histological images. The sensitivity interpreted a lesion as being present when its stage from the 6-point scale was determined the same as the histological assessment. On the other hand, the specificity interpreted a lesion when it was not present.

#### Results

The Intra-observer weighted kappa coefficients calculated for each observer for each medium ranged between 0.81 and 0.95 (Table 1). Considering the very high intra-observer Weighted kappa coefficients suggestive of strong and excellent intra-observer agreement, inter-observer weighted kappa coefficient and Az value calculations were based on the first readings only. Inter-observer Weighted kappa coefficients agreement ranged from 0.77 to 0.85, with strong and excellent inter-observer agreement found for all media (Table 1).

**Table 1:** Intra and inter-observer weighted kappa coefficients (SD) calculated for each medium

	Paper	Monitor	Film
Observer 1	0.958(0.055)	0.887(0.052)	0.912(0.053)
Observer 2	0.916(0.056)	0.923(0.055)	0.818(0.056)
Inter-observer	0.852(0.055)	0.847(0.052)	0.778(0.054)

SD, standard deviation

The mean areas under the ROC curves (Az values), their standard errors, and significance levels for the first readings are given in Table 2. The highest Az value was obtained with the monitor-displayed images, whereas the lowest Az value was obtained with film printed radiographs. However, there were no significant differences between any of the Az values obtained with the different methods of caries detection ( $p > 0.05$ ).

**Table 2:** Between-subjects mean Az values and significance levels for the observers' first reading

	Paper	Monitor	Film
Az (SE)	0.867(0.029)	0.879(0.026)	0.829(0.030)
p Value	<0.001	<0.001	<0.001

SE, standard error

Teeth with dentinal caries yielded the best diagnosis rates for all caries detection methods and the deeper the caries lesion, the higher the sensitivity rate. The lowest sensitivity rates were obtained from teeth with enamel caries, with no significant difference between stage 1 and 2. Table 3 shows the mean sensitivity indi-

ces of the two observers obtained from the first readings of different media.

**Table 3:** Sensitivity (Sn) and specificity (Sp) rates of each medium in different caries-depth stages

	Paper	Monitor	Film
1	0.0% (98.2%) <sup>+</sup>	9.2% (94.5%)	5.3% (98.1%)
2	2.6% (98.5%)	7.9% (98.3%)	0.0% (97.1%)
3	39.3% (98.1%)	34.5% (97.3%)	38.1% (95.7%)
4	76.6% (92.8%)	66.7% (93.0%)	60.0% (95.3%)
5	70.4% (98.0%)	75.0% (98.3%)	79.5% (98.5%)
Pooled rate*	37.7% (97.1%)	38.6% (96.3%)	36.5% (96.9%)

\*Pooled rates were calculated by averaging the values of stage 1 to 5.

<sup>+</sup> Sn (Sp)

Although the specificity rates in different stages does not differ significantly, the highest rate in each stage belongs to hard copies with the paper prints having the higher specificity rates in lower stages (1, 2, &3). Table 4 summarizes the histopathologic results of the evaluated surfaces.

**Table 4:** Histological results; total of proximal surfaces

Stage	Number of surfaces	Percentage
0	85	35.4%
1	40	16.6%
2	24	10.0%
3	43	17.9%
4	22	9.1%
5	26	10.8%

## Discussion

Although different systems exist for transmitting diagnostic information from one office to another, many dentists still prefer hard copies of radiographs in their working environment due to the non-optimal condition for analyzing digital images or film prints and the limited access to monitors at the patient's chairside. [8-9] Paper records are a common, low-cost, and environmentally friendly interim record of digital images. [10, 13] They are significantly more cost-effective than their film counterpart is and the typical working environment is less degrading to its diagnostic quality. [13] The present study compared the diagnostic accuracy of paper, film print and monitor-displayed images in proximal caries detection and no statistically significant difference was found between these modalities ( $p > 0.05$ ).

In the current study, the intra-observer and inter-observer agreements ranged from 0.81-0.95 and 0.77-0.85, respectively. Although the least intra-observer agreement of the first observer was obtained from moni-

tor-displayed images (0.88), the second observer had the weakest agreement on film images (0.81). This difference in intra-observers' agreement may be due to the type of media which they are accustomed to for caries diagnosis. Furthermore the level of inter observer agreement reported by previous studies examining the use of different radiograph recording media in the detection of caries varies (0.396-0.850). [13, 16] These differences in inter-observer agreement may be related to the observer's experience, study design, and study material.

In the present study, the high ROC values suggested that the certainty score achieved by the three methods could distinguish carious lesions from intact surfaces accurately. Although the highest Az value was obtained from monitor-displayed images, there was no statistically significant difference between the Az values of the three techniques. On the other hand, the low sensitivity rates (36.5-38.6%) shows that observers could not determine the exact stage of lesions precisely which is due to the fact that 40-60% tooth decalcification is needed to produce radiographic image. [29]

Previous studies showed that there is no significant difference between different digital receptors or different phosphor plates for the accuracy of caries diagnosis. [1, 30] Concluding that using different digital receptors does not affect our results, in the present study, we used size #2 DigoraOptime phosphor plates.

The pixel size of these plates is 60  $\mu\text{m}$  (resolution=8000 PPI). A resolution of 300 PPI retains the diagnostic information in a digital bitewing radiograph as viewed on a standard monitor. [16] Comparing five different flat panel monitors with conventional film for detection of proximal caries, Isidor *et al.* [17] found no significant differences between the sensitivity rates (13-17%). Resolution of monitors, which were used in their study, ranged 1024 $\times$ 768 to 1400 $\times$ 1024. [17] The LG monitor which we used in this study had resolution (1, 360 $\times$ 768) and showed a higher sensitivity rate (38.6%) and a similar specificity rate (96%). The lower sensitivity rate can be explained by the fact that 94% of the surfaces which Isidor *et al.* [17] assessed had enamel caries or no caries (comparing to the 52% in the current study). It has been showed that lesion depth significantly affects observer performance in diagnosis of caries on radiographs. [30] This can also explain why the sensi-

vity rates in the current study are considerably lower in the stage 1 and 2 comparing to stages 3-5.

A printer resolution of 600 DPI is the recommended printer setting for a standard, high quality printer. [13] Both printers used in this study fulfilled this requirement. Schulze *et al.* [19] compared three inkjet and two thermo-sublimation printers to the monitor (as a gold standard) for the evaluation of accuracy (interproximal caries, apical radiolucency, length of root canal fillings); In line with our study high diagnostic accuracy was found for all printers (Az value:0.725-0.884). [19]

To the best of our knowledge, there has been no study exclusively reporting the effect of viewing on the monitor-displayed images, paper or film prints on the diagnostic accuracy of proximal caries lesions in bitewing radiographs. Otis and Sherman [13] digitized 15 bitewing radiographs, printed them on photographic paper, and evaluated images for evidence of caries. Although images did not differ significantly for diagnosing dentinal caries, for caries limited to the enamel surface, a decrease in sensitivity was noted for the printed images. [13] A drawback of this study is that they scanned the conventional intraoral films and printed them on paper. This scanning and printing process inherently diminishes the details that can be seen on the radiographs. Therefore, the decreased diagnostic accuracy of papers cannot be contributed to its weakness in demonstrating enamel caries.

### Conclusion

Looking at the results of the present study in detail, it can be concluded that although there was not a significant difference between three methods, reproduction of radiographic images on hard copy is not reasonable whenever an interim soft copy record is available. However, when a hard copy is needed, a paper print will be a better option than film prints.

### Acknowledgements

The authors thank the Vice-Chancellery of Shiraz University of Medical Sciences for supporting this research (Grant#8794126). This manuscript is based on the thesis by Dr. Anita Amrollahi. The authors also thank Dr. Vosoughi of the center for Research Improvement of the School of Dentistry for the statistical analysis and Dr. Amalsaleh for improving the use of English in the

manuscript.

### Conflict of Interest

The authors of this manuscript certify that they have no conflict of interest considering this study.

### References

- [1] Senel B, Kamburoglu K, Uçok O, Yüksel SP, Ozen T, Avsever H. Diagnostic accuracy of different imaging modalities in detection of proximal caries. *Dentomaxillofac Radiol.* 2010; 39: 501-511.
- [2] Shi XQ, Li G. Detection accuracy of approximal caries by black-and-white and color-coded digitalradiographs. *Oral Surg Oral Med Oral Pathol Oral Radiol Endod.* 2009; 107: 433-436.
- [3] Goel A, Chawla HS, Gauba K, Goyal A. Comparison of validity of DIAGNOdent with conventional methods for detection of occlusal caries in primary molars using the histological gold standard: an in vivo study. *J Indian Soc Pedod Prev Dent.* 2009; 27: 227-234.
- [4] Li G, Qu XM, Chen Y, Zhang J, Zhang ZY, Ma XC. Diagnostic accuracy of proximal caries by digital radiographs: an in vivo and in vitro comparative study. *Oral Surg Oral Med Oral Pathol Oral Radiol Endod.* 2010; 109: 463-467.
- [5] Peker I, Toraman Alkurt M, Altunkaynak B. Film tomography compared with film and digital bitewing radiography for proximalcaries detection. *Dentomaxillofac Radiol.* 2007; 36: 495-499.
- [6] Anbiaee N, Mohassel AR, Imanimoghaddam M, Moazzami SM. A comparison of the accuracy of digital and conventional radiography in the diagnosis of recurrent caries. *J Contemp Dent Pract.* 2010; 11: E025-E032.
- [7] dos Anjos Pontual A, de Melo DP, Pontual ML, de Almeida SM, Haiter-Neto F. Comparative study of a wireless digital system and 2 PSP digital systems on proximalcaries detection and pixel values. *Gen Dent.* 2013; 61: 56-60.
- [8] Svanaes DB, Moystad A, Larheim TA. Approximal caries depth assessment with storage phosphor versus film radiography. Evaluation of the caries-specific Oslo enhancement procedure. *Caries Res.* 2000; 34: 448-453.
- [9] Zhang ZL, Qu XM, Li G, Zhang ZY, Ma XC. The detection accuracies for proximal caries by cone-beam computerizedtomography, film, and phosphor plates. *Oral Surg Oral Med Oral Pathol Oral Radiol Endod.* 2011;111:

- 103-108.
- [10] Maydell AT, Andronikou S, Ackermann C, Bezuidenhouut AF. Comparison of paper print and soft copy reading in plain paediatric radiographs. *J Med Imaging Radiat Oncol.* 2009; 53: 459-466.
- [11] Benediktsdóttir IS, Wenzel A. Accuracy of digital panoramic images displayed on monitor, glossy paper, and film for assessment of mandibular third molars. *Oral Surg Oral Med Oral Pathol Oral Radiol Endod.* 2004; 98: 217-222.
- [12] Schulze RK, Grimm S, Schulze D, Voss K, Keller HP, Wedel M. Diagnostic yield of inkjet prints from digital radiographs for the assessment of approximal carious lesions: ROC-analysis. *Eur J Radiol.* 2011; 79: 277-282.
- [13] Otis LL, Sherman RG. Assessing the accuracy of caries diagnosis via radiograph. Film versus print. *J Am Dent Assoc.* 2005; 136: 323-330.
- [14] Akdeniz BG, Gröndahl HG, Magnusson B. Accuracy of proximal caries depth measurements: comparison between limited cone beam computed tomography, storage phosphor and film radiography. *Caries Res.* 2006; 40: 202-207.
- [15] Rockenbach MI, Veeck EB, da Costa NP. Detection of proximal caries in conventional and digital radiographs: an in vitro study. *Stomatologija.* 2008; 10: 115-120.
- [16] Ilguy M, Dincer S, Ilguy D, Bayirli G. Detection of artificial occlusal caries in a phosphor imaging plate system with two types of LCD monitors versus three different films. *J Digit Imaging.* 2009; 22: 242-249.
- [17] Isidor S, Faaborg-Andersen M, Hintze H, Kirkevang LL, Frydenberg M, Haiter-Neto F, et al. Effect of monitor display on detection of approximal caries lesions in digital radiographs. *Dentomaxillofac Radiol.* 2009; 38: 537-541.
- [18] Hellén-Halme K, Lith A. Carious lesions: diagnostic accuracy using pre-calibrated monitor in various ambient light levels: an in vitro study. *Dentomaxillofac Radiol.* 2013; 42: 20130071.
- [19] Schulze RK, Schulze D, Voss K, Rottner M, Keller HP, Dollmann K, et al. Quality of individually calibrated customary printers for assessment of typical dental diagnoses on glossy paper prints: a multicenter pilot study. *Oral Surg Oral Med Oral Pathol Oral Radiol Endod.* 2008; 106: 578-586.
- [20] van Ravesteyn NT, van Lier L, Schechter CB, Ekwueme DU, Royalty J, Miller JW, et al. Transition from film to digital mammography: impact for breast cancer screening through the national breast and cervical cancer early detection program. *Am J Prev Med.* 2015; 48: 535-542.
- [21] Nishikawa RM, Acharyya S, Gatsonis C, Pisano ED, Cole EB, Marques HS, et al. Comparison of soft-copy and hard-copy reading for full-field digital mammography. *Radiology.* 2009; 251: 41-49.
- [22] Hendrick RE, Cole EB, Pisano ED, Acharyya S, Marques H, Cohen MA, et al. Accuracy of soft-copy digital mammography versus that of screen-film mammography—according to digital manufacturer: ACRIN DMIST retrospective multireader study. *Radiology.* 2008; 247: 38-48.
- [23] Schropp L, Alyass NS, Wenzel A, Stavropoulos A. Validity of wax and acrylic as soft-tissue simulation materials used in in vitro radiographic studies. *Dentomaxillofac Radiol.* 2012; 41: 686-690.
- [24] Caldas Mde P, Ramos-Perez FM, de Almeida SM, Haiter-Neto F. Comparative evaluation among different materials to replace soft tissue in oral radiology studies. *J Appl Oral Sci.* 2010; 18: 264-267.
- [25] Schropp L, Alyass NS, Wenzel A, Stavropoulos A. Validity of wax and acrylic as soft-tissue simulation materials used in in vitro radiographic studies. *Dentomaxillofac Radiol.* 2012; 41: 686-690.
- [26] Kamburoglu K, Kolsuz E, Murat S, Yüksel S, Ozen T. Proximal caries detection accuracy using intraoral bitewing radiography, extraoral bitewing radiography and panoramic radiography. *Dentomaxillofac Radiol.* 2012; 41: 450-459.
- [27] Sogur E, Baksı BG, Orhan K, Paksoy SC, Dogan S, Erdal YS, et al. Effect of tube potential and image receptor on the detection of natural proximal caries in primary teeth. *Clin Oral Investig.* 2011; 15: 901-907.
- [28] Davies M, Fleiss JL. Measuring agreement for multinomial data. *Bio-metrics.* 1982; 38: 1047-1051.
- [29] Maia AM, Karlsson L, Margulis W, Gomes AS. Evaluation of two imaging techniques: near-infra-red transillumination and dental radiographs for the detection of early approximal enamel caries. *Dentomaxillofac Radiol.* 2011; 40: 429-433.
- [30] Syriopoulos K, Sanderink GC, Velders XL, van der Stelt PF. Radiographic detection of approximal caries: a comparison of dental films and digital imaging systems. *Dentomaxillofac Radiol.* 2000; 29: 312-318.