

**Case Report**

## Goldenhar Syndrome in a 6-Year-Old Patient: a Case Report and Review of Literature

Fatemeh Jahanimoghadam, DMD, MScD<sup>1</sup>; Maryam Sharifi, DMD<sup>2</sup>

<sup>1</sup> Oral and Dental Diseases Research Center, Kerman Social Determinants on Oral Health Research Center, Dept. of Pediatric Dentistry, School of Dentistry, Kerman University of Medical Sciences, Kerman, Iran.

<sup>2</sup> Resident Dept. of Pediatric Dentistry, School of Dentistry, Kerman University of Medical Sciences, Kerman, Iran.

### KEY WORDS

Craniofacial Abnormalities;  
Ventricular Septal Defects;  
Mandibular Condyle;  
Oral Manifestations;  
Goldenhar Syndrome;

Received: April 2018;  
Revised: July 2018;  
Accepted: August 2018;

### ABSTRACT

Goldenhar syndrome (GHS) is a complex syndrome characterized by relation of mandibular hypoplasia, abnormality of the ear, ocular dermoid and vertebral disorders and hemi facial macrosomia. Treatment protocol depends on the patient's age and systemic clinical presentations, with a multidisciplinary method often being required. This case report describes a typical 6-year-old female patient who presented to the Department of Pediatric Dentistry, Faculty of Dentistry, University of Medical Sciences, Kerman, Iran with mandibular hypoplasia, facial asymmetry, ear tags and ocular dermoid after plastic surgery. Diagnosis was based on clinical aspects, radiology and laboratory findings. GHS is a developmental complaint that can disturb many aspects of the patient's life; therefore, immediate treatment from birth is necessary.

**Corresponding Author:** Sharifi M, Dept. of Pediatric Dentistry, School of Dentistry, Kerman University of Medical Sciences, Kerman, Iran. Postal code: 7618759689 Tel: +98-343211902  
Email: maryam2247@gmail.com

Cite this article as: Jahanimoghadam F, Sharifi M. Goldenhar Syndrome in a 6-Year-Old Patient: a Case Report and Review of Literature. *J Dent Shiraz Univ Med Sci.* December 2019; 20(4): 298-303.

### Introduction

Goldenhar syndrome (GHS), facio-auriculo-vertebral dysplasia or oculo-auriculo-vertebral syndrome, first reported in 1981 by German physician Carl Ferdinand Von Arlt [1]. In 1952, Goldenhar classified its clinical variations [1]. This is a rare growing defect. MSX homeobox genes play a central role in pathogenesis. GHS incidence is between 1:3500 and 1:5600. Male to female proportion is 3 to 2. In 85% of patients, only one side of face is affected, right side involvement is more common [1]. In 10-33% of cases, the involvement is bilateral. Most cases are infrequent. Multifactorial, autosomal dominant and autosomal recessive are the methods of heritage [2].

Precise etiology is yet unknown. First and second bronchial arches are implicated in GHS. The exposure to synthetic drugs or different viruses during pregnancy is expected as the etiology of GHS. Development of this syndrome is related to intake of some drugs, such as cocaine, thalidomide, tamoxifen, and retinoic acid by mother in gestation period. Maternal diabetes, influenza,

and rubella have also been suggested as the causative factor [3].

The diagnosis of GHS must be based on radiologic, laboratory results and the clinical findings [3]. In a classic GHS, characteristic clinical findings include eyes anomalies, ears abnormalities, facial defects, heart syndromes, kidney and gastrointestinal defects, trachea and lungs malformations, central nervous system (CNS) involvement, dental and oral problems, and skeletal alterations.

The eyes anomalies include colomas of the iris, upper eyelid, and retina. The other eye malformations are microphthalmia, astigmatism, cataracts, and blepharophimosis. Epidermoid tumors present in 35% of patients, which 50% are unilateral and 25% are bilateral. These tumors are ovoid with color of yellowish or pinkish white. Their size is different from 8-10 mm. They have commonly fine hairs and their surfaces are smooth [4]. The ears abnormalities include blind fistulas or preauricular skin tags. Other ear malformations are aplasia and atresia of the external auditory meatus. The

GHS with hereditary deafness was observed in 1 to 1000 children [5]. The facial defect includes unilateral facial hypoplasia. In few patients, mild pneumatization of the mastoid part can be observed. Hypoplasia of the mandibular ramus and condyle may cause a reduction in the size of temporal and malar bones. The heart problems include ventricular septal defects and tetralogy of Fallot with or without right aortic arch. The hypoplasia of the external carotid artery and tubular hypoplasia of the aortic arch are also reported [6].

The kidney and gastrointestinal defects include absence of kidney or kidney with double ureters, impaired blood supply to the kidney, and hydronephrosis [7].

In trachea and lungs malformations, the tracheo-esophageal fistula is predominant. Pulmonary malformations vary from incomplete lobulation, hypoplasia to complete agenesis [7]. Concerning CNS involvement, mental retardation is observed. Seventh cranial nerve is involved and unilateral aplasia of the trigeminal nuclei and trigeminal anesthesia is reported [7].

The oral manifestations of GHS include cleft lip and palate, unilateral tongue hypoplasia, hypoplasia of the maxillary and mandibular arches, micrognathia, gingival hypertrophy, micrognathia, delayed tooth development, supernumerary teeth, enamel and dentin abnormalities are the main disorders [8-9].

Considering craniofacial abnormalities, skull anomalies like microcephaly and dolichocephaly have been detected. On the affected part, facial vertical and anteroposterior dimensions are reduced. Cervical vertebral unions may happen in 60% of cases. It is reported that spina bifida, hemi vertebrae, butterfly, Klippel- Feil anomaly, occur in most of the patients [3].

Lisbôa *et al.* [10] stated when there are two or more diagnostic features in the oro-cranium facial, ocular, auricular and vertebral areas, GHS is definitive. It is reported that at least two of the following findings must be present for diagnosis of GHS including unilateral micrognathia, unilateral mandibular hypoplasia, epibulbar dermoid cysts or vertebral malformations [11-12]. The present study reports a case of GHS in a 6-year-old female, with no family history; where about some of the classic features of the syndrome were present. Early diagnosis and management of GHS by pediatric dentists can have a specific impact on the health of these children.

## Case Report

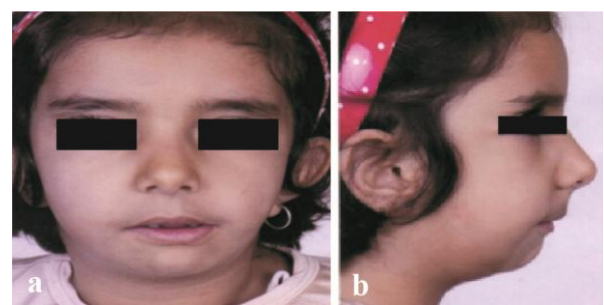A 6-year-old girl was referred to the Department of Pediatric Dentistry, Faculty of Dentistry, University of Medical Sciences, Kerman, Iran with the chief complaint of pain in tooth #51 and #61. Her mother had a full-term normal delivery and there was history of kidney stone in the third month of pregnancy and because of that, she took Rowatinex capsule for a week, 3 times a day before meal.

The age of the father and mother was respectively 26 and 28 years at pregnancy. There was no history of genetic or dental anomalies in the familial history. The parents had not the consanguineous marriage. The child had been born by natural birth and was the first child of the family. The child's height was normal but her weight was under normal curve. The patient had normal skin and hair. The girl had a younger brother with no sign of congenital anomalies.

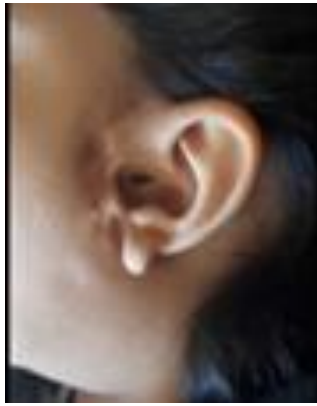On general examination, she was conscious and had normal learning skills. Vital signs were within normal limits. On extra oral examination, the patient had obvious left mandible hypoplasia with the chin slightly deflected to the affected side. Facial profile was convex (Figure 1a and b). Ear tags have been removed surgically when the child was 2 years old.

Figure 2 shows the post-surgical scars resulting from removal of ear tags and atresia of external auditory meatus after surgery. Ocular changes show dermoids in the conjunctiva of left eye; these dermoids were particularly large and interfere with vision, so they were surgically removed when she was 3 years old (Figure 3).

The results of complete blood count (CBC), alkaline phosphatase, Ca, P, ferritin and fasting blood sugar (FBS) tests were within normal range. The pre-treatment panoramic view (Figure 4a) is not obvious as the patient was very uncooperative.



**Figure 1a:** Frontal view demonstrating unilateral deviation of mandible and left eye dermoid and **b:** Front view demonstrating convexity of the face

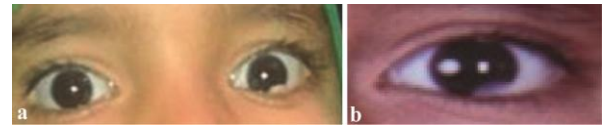


**Figure 2:** Scars resulting from surgical removal of ear tags and atresia of external auditory meatus

The post treatment view has been taken about one year later when the child was 7 years and more cooperative (Figure 4b). In post-treatment panoramic radiography, sequence of teeth eruption was normal, most of teeth germs were in developing phase, but the development of tooth bud of second premolar on the left mandible has not been started yet. Lack of development of the left ramus of mandible, imperfect development of the left coronoid process and condyle, lack of temporomandibular joint development, incomplete development and hypoplasia of zygomatic bone, maxillary zygomatic arc and ear bones on the same side were detected (Figure 4a and b).

Periapical radiographs show anterior mandibular and maxillary teeth before extraction (Figure 5a and b).

Intraoral examinations did not show any oral lesions. Examination of the teeth revealed deep caries of the deciduous teeth on the maxillary and mandibular teeth #51, #53, #61, #63, #74 and, #85. The oral hygiene was fair and periodontal tissues had a natural color and consistency (Figure 6a and b). The maxillary arch was normal, but the mandibular arch was asymmetric. The midline was off to the right side. The overjet was reverse. Canine relationship was class III on the both sides (Figure 7).



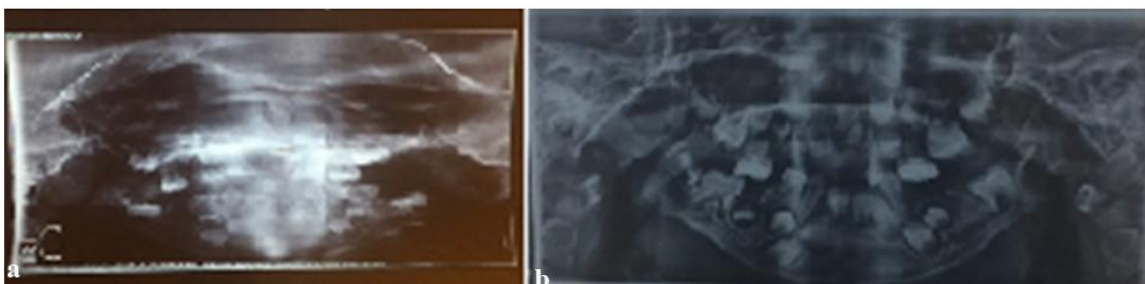
**Figure 3:** View demonstrating left eye dermoid **a:** before and **b:** after surgery

The primary teeth #51, #61, #71, #72, #81 and #82 on the maxilla and mandibular arch were extracted due to the pain and exposed roots. The teeth #52, #54, #62, #64 on the maxillary arch and #75, #84 and #85 on the mandibular arch were extracted. Pulpectomy treatment with Metapex was done for teeth #53 and #63, and then restored with composite buildup technique. The tooth #73 was veneered with composite. Pulpectomy treatment with zinc oxide eugenol (ZOE) and placement of stainless steel crown (SSC) was undertaken for the teeth #55, #65 and #74. Ultimately, a Hollywood prosthetic appliance and a removable acrylic appliance were fabricated to upper and lower arch respectively in order to provide esthetic and chewing function until adolescent stage (Figure 8).

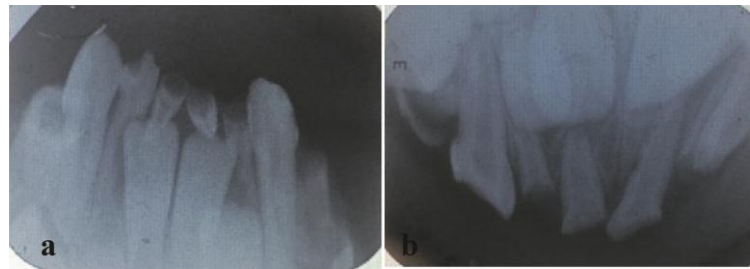
Other body organs are still under follow up. Cervical and lumbar vertebrae and kidneys show no problems in computed tomography (CT) scan imaging. Other bones are also normal in image (Figure 9). Hearing of child is normal but she is under precise monitoring of specialist. Oral hygiene instructions and dietary counseling were performed. The patient was kept under follow up visits every 6 months. A total of 5 ml whole blood from patient brachial vein in tubes containing 200µl of ethylene diamine tetra-acetic acid (EDTA) were collected, genomic DNA was isolated from leukocytes of the whole blood using salt-saturation method [13].

## Discussion

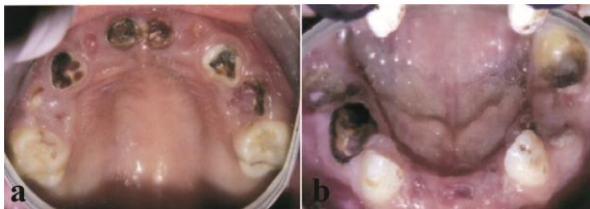
GHS is a rare hereditary disorder with unknown etiology and is described as a triad of ocular dermoids, accessory



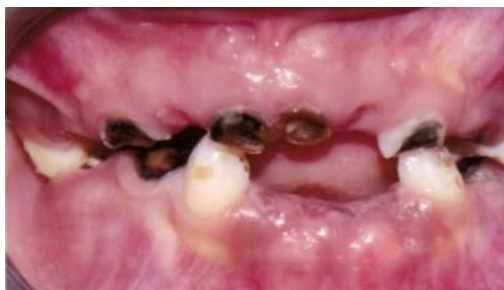**Figure 4:** Panoramic radiograph reveals lack of development of mandible, zygomatic bone, zygomatic arc **a:** Pretreatment panoramic radiograph and **b:** Post treatment radiograph revealed under developed bone ears



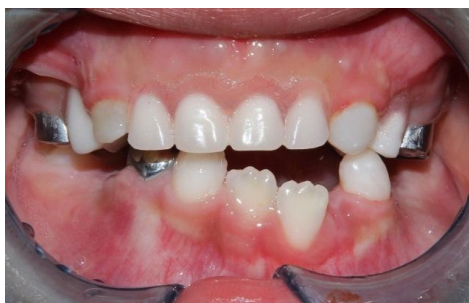**Figure 5a:** Anterior mandibular periapical radiography and **b:** Anterior maxillary periapical radiography



**Figure 6a:** Oclusal view of upper jaw showing deep caries and **b:** Oclusal view of lower jaw showing deep caries

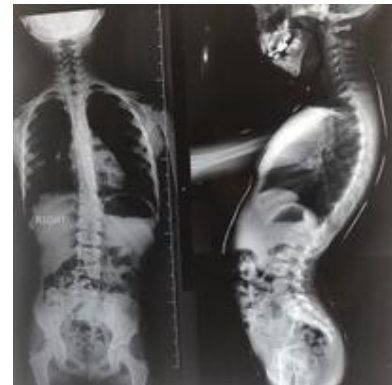

**Figure 7:** Class III relationship of canines in left and right side



**Figure 8:** A Hollywood prosthetic appliance and a removable acrylic appliance fabricate to upper and lower arch

tragic and mandibular hypoplasia. This syndrome is different in severity in each patient [14-15]. Macrostomia forms in the second month of embryonic development, which is usually related to skin tags and pits between tragus and the corner of the mouth [16]. This syndrome is characterized by various anomalies affecting the first and second bronchial arches of the first pharyngeal pouch, the primordia of the temporal bone and the first branchial cleft [8, 17]. The occurrence of this syndrome is before the end of 7th or 8th week of embryonic life [18].



**Figure 9:** Frontal and lateral view of kidneys, cervical and lumbar spines in cervicothoracodorsolumbar radiography

Numerous possibilities have been proposed to explain the etiology of this syndrome, for example, Baum and Feingold [19] and De Golovine *et al.* [20] stated that GHS might be a sporadic anomaly that occurs early in embryogenesis, which is showed reduced penetrance, somatic mosaicism or epigenetic changes. Moreover, there are familial cases in families with history of consanguineous marriage [9]. Some etiologic factors consist of maternal medication use especially in relation with smoking in the first 2.5 months of gestation, primidone, retinoic acid and thalidomide and maternal diabetes [21]. There is no chromosomal or genetic test to diagnosis GHS. A specialist makes a diagnosis by identifying the symptoms of GHS [22]. When it is identified, the child usually needs to have further tests, such as hearing and vision tests and the examination of heart or kidney. A clinician may order ultrasound imaging for these checkups or X-ray of the spine to check for problems with vertebrae [22]. A total of 80 to 99% of patients with GHS have facial asymmetry, hearing impairment, hypoplasia of the maxilla, malar flattening, preauricular skin tag, which are diagnostic for GHS [23]. These features were observed in our presented case. In the present case, the mother took Rowatinex capsule for a week, 3 times a day in the third month of

pregnancy for her kidney stone. This drug may be the cause of this syndrome; however, it has not been mentioned in the literatures up to now.

The great prevalence of hereditary heart syndromes in GHS was reported by Friedman and Saraclar [24]. Abe *et al.* [25] described a case of GHS related to cardiac disorders such as single ventricle and patent ductus arteriosus. Mahore *et al.* [26] reported a patient of GHS with crossed ectopic kidneys in relation with other clinical findings. Our patient did not have a history of kidney and heart disease. The effect of GHS on developing of the patient is clear. Breathing problems are due to lack of development of the jaws, which need multidisciplinary approach in these patients [27].

Damage of differentiating tissue in the region of the jaw and ear by hematoma will produce arch disorder. Severity of the dysplasia is related to the extent of local damage. GHS is associated with sensorineural loss of hearing, vertebral anomalies, central nervous system, and renal malformations. Other syndromes related to multiple preauricular tragi are Treacher-Collins syndrome, Wildervanck syndrome, and Townes-Brocks anomaly [28]. Hypoplasia of maxilla and mandible are associated with Treacher Collins anomaly [15].

The treatment for GHS depends on age and systemic relations. Timing of the reconstruction has a major role in the treatment. In uncomplicated cases, cosmetic is a basic concern. Cleft repair, corrections of colobomas, ear anomalies at the age of 6 to 8 years and removal of dermoids and preauricular tags at the age of 5 are principal reconstructions [29]. In our case, preauricular tags of left ear were surgically reconstructed at age of five. In patients with mandibular hypoplasia, rib grafts can be used and a bone distraction device can extend an underdeveloped maxilla. Jaw reconstruction surgeries can be done in the early teens, in patients with milder involvement, epibulbar dermoids should be excised by surgery. Structural abnormalities of the eyes and ears are correctable by plastic surgery; in our patient helix, plastic surgery was done when she was 6 months as her mother was concerned about beauty of her ears. In uncomplicated cases, without any systemic complications, the disease prognosis is good [14, 30-31]. The complex treatment is focused on dental care, talking, hearing, prevention, and treatment of the psychosocial problems of the syndrome. In our case, due to providing esthetic

and masticatory function, prosthetic devices were fabricated for upper and lower jaw until adolescent stage. Treatment needs constant follow-up and subsequently, we put our patient in 6-month follow-ups. Informed consent was obtained from the patient for publishing her clinical photography and radiography.

### Conclusion

GHS is a developmental syndrome that can disturb many aspects of the patient's life. This syndrome does not have exact treatment. It needs multidisciplinary approach. In this patient, consultation with surgeon and orthodontist was performed. Distraction osteogenesis along with functional orthodontics was supposed to be used at older age. A long-term follow-up is necessary to observe the child growth.

### Acknowledgment

The authors wish to thank the patient and her mother for the assistance in all periods of study.

### Conflict of Interest

The authors of this manuscript certify that they have no financial or other competing interest concerning this article.

### References

- [1] Harris T, Bashith MA, Shanbhag MM, Faheem M. Goldenhar syndrome: a rare entity. *International Journal of Contemporary Pediatrics*. 2017; 4: 1897-1899.
- [2] Patil NA, Patil AB. Goldenhar syndrome: Case report. *IJSS Journal of Surgery*. 2015; 1: 18-20.
- [3] Derbent M, Orün UA, Varan B, Mercan S, Yilmaz Z, Sahin FI, et al. A new syndrome within the oculoauriculo-vertebral spectrum: microtia, atresia of the external auditory canal, vertebral anomaly, and complex cardiac defects. *Clin Dysmorphol*. 2005; 14: 27-30.
- [4] Al Kaissi A, Ben Chehida F, Ganger R, Klaushofer K, Grill F. Distinctive spine abnormalities in patients with Goldenhar syndrome: tomographic assessment. *Eur Spine J*. 2015; 24: 594-599.
- [5] Román Corona-Rivera J, López-Marure E, Gómez-Ruiz L, del Carmen Abreu-Fernández M, Quezada-López C, Pérez-Molina J, Santibañez-Escobar LP. Airway anomalies in the oculoauriculofrontonasal syndrome. *Clin Dysmorphol*. 2007; 16: 43-45.

- [6] Al-Droos M, Almomani B, Aljaouni M. Ocular Manifestations of Marfan syndrome In Seven Members of One Family from Libya. *Middle East Journal of Age & Ageing*. 2013; 10: 2.
- [7] Gorlin RJ, Cohen Jr MM, Hennekam RC. *Syndromes of the head and neck*. 4th ed. Oxford University Press: Oxford; 2001. p. 1-1283.
- [8] Kokavec R. Goldenhar syndrome with various clinical manifestations. *Cleft Palate Craniofac J*. 2006; 43: 628-634.
- [9] Tuna EB, Orino D, Ogawa K, Yildirim M, Seymen F, Gencay K, et al. Craniofacial and dental characteristics of Goldenhar syndrome: a report of two cases. *J Oral Sci*. 2011; 53: 121-124.
- [10] Lisbôa RC, Mendez HM, Paskulin GA. Síndrome de Goldenhar e variantes: relato de sete pacientes. *Rev AM RIGS*. 1987; 31: 265-269.
- [11] Bustamante LNP, Guerra IVd, Iwahashi ER, Ebaid M. Síndrome de Goldenhar: relato de cinco casos em associação com malformações cardíacas. *Arq Bras Cardiol*. 1989; 53: 287-290.
- [12] Ferreira JM, Gonzaga J. Goldenhar syndrome. *Rev Bras Oftalmol*. 2016; 75: 401-404.
- [13] Miller SA, Dykes DD, Polesky HF. A simple salting out procedure for extracting DNA from human nucleated cells. *Nucleic Acids Res*. 1988; 16: 1215.
- [14] Kulkarni V, Shah MD, Parikh A. Goldenhar syndrome (a case report). *J Postgrad Med*. 1985; 31: 177-179.
- [15] Bhuyan R, Pati AR, Bhuyan SK, Nayak BB. Goldenhar Syndrome: A rare case report. *J Oral Maxillofac Pathol*. 2016; 20: 328.
- [16] Larsen W. *Development of the eyes*. Human embryology. 2nd ed. New York: Churchill Livingstone; 1993. p.1-479.
- [17] Tasse C, Majewski F, Böhringer S, Fischer S, Lüdecke HJ, Gillessen-Kaesbach G, et al. A family with autosomal dominant oculo-auriculo-vertebral spectrum. *Clin Dysmorphol*. 2007; 16: 1-7.
- [18] Bekibele CO, Ademola SA, Amanor-Boadu SD, Akang EE, Ojemakinde KO. Goldenhar syndrome: a case report and literature review. *West Afr J Med*. 2005; 24: 77-80.
- [19] Baum JL, Feingold M. Ocular aspects of Goldenhar's syndrome. *Am J Ophthalmol*. 1973; 75: 250-257.
- [20] De Golovine S, Wu S, Hunter JV, Shearer WT. Goldenhar syndrome: a cause of secondary immunodeficiency? *Allergy Asthma Clin Immunol*. 2012; 8: 10.
- [21] Hartsfield JK. Review of the etiologic heterogeneity of the oculo-auriculo-vertebral spectrum (Hemifacial Microsomia). *Orthod Craniofac Res*. 2007; 10: 121-128.
- [22] Chen H. *Atlas of genetic diagnosis and counseling*. 10th ed. Humana Press Inc.: Totowa New Jersey; 2006. p. 1075.
- [23] Limwongse C. *Developmental Syndromes and Malformations of the Urinary Tract*. Available at: [https://link.springer.com/reference/workentry/10.1007/978-3-662-43596-0\\_5](https://link.springer.com/reference/workentry/10.1007/978-3-662-43596-0_5)
- [24] Friedman S, Saraclar M. The high frequency of congenital heart disease in oculo-auriculo-vertebral dysplasia (Goldenhar's syndrome). *J Pediatr*. 1974; 85: 873-4.
- [25] Abe K, Ishikawa N, Murakami Y. Goldenhar's syndrome associated with cardiac malformations. *Helvetica Paediatrica Acta*. 1975; 30: 57-60.
- [26] Mahore A, Dange N, Nama S, Goel A. Facio-auriculo-vertebro-cephalic spectrum of Goldenhar syndrome. *Neurol India*. 2010; 58: 141-144.
- [27] Bielicka B, Necka A, Andrych M. Interdisciplinary treatment of patients with Goldenhar syndrome—clinical reports. *Dent Med Probl*. 2006; 43: 458-462.
- [28] Mehta B, Nayak C, Savant S, Amladi S. Goldenhar syndrome with unusual features. *Indian J Dermatol Venereol Leprol*. 2008; 74: 254-256.
- [29] Volpe P, Gentile M. Three-dimensional diagnosis of Goldenhar syndrome. *Ultrasound Obstet Gynecol*. 2004; 24: 798-800.
- [30] Emtiaz S, Noroozi S, Caramês J, Fonseca L. Alveolar vertical distraction osteogenesis: historical and biologic review and case presentation. *Int J Periodontics Restorative Dent*. 2006; 26: 529-541.
- [31] Sharma JK, Pippal SK, Raghuvanshi SK, Shitij A. Goldenhar-Gorlin's syndrome: A case report. *Indian J Otolaryngol Head Neck Surg*. 2006; 58: 97-101.