

Comparison of Dental Arch Changes and Patients' Discomforts between Newly Designed Maxillary Expansion Screw and Slow Expansion Procedures

Oshagh M.^a, Momeni Danaei Sh.^b, Hematiyan MR.^c, Hajian Kh.^d, Shokoohi Z.^d

^a Orthodontic Research Center, Dept. of Orthodontics, School of Dentistry, Shiraz University of Medical Sciences, Shiraz, Iran

^b Orthodontic Research Center, Professor, Dept. of Orthodontics, School of Dentistry, Shiraz University of Medical Sciences, Shiraz, Iran

^c Dept. of Mechanical Engineering, Shiraz University, Shiraz, Iran

^d Student Research Committee, Shiraz University of Medical Sciences, Shiraz, Iran, Dentist

KEY WORDS

Orthodontic Expansion;
Palatal expansion screws;
Arch size

Received Jan. 2012;
Received in revised form July 2012;
Accepted June 2012.

ABSTRACT

Statement of Problem: One fourth of orthodontic patients can benefit from maxillary expansion but traditional expansion screws produce unfavorable heavy interrupted forces. A new spring- loaded expansion screw was designed which created light and continuous forces.

Purpose: The purpose of this study was to compare the treatment effects and patients' discomfort with removable slow maxillary expansion and newly designed spring-loaded expansion screw.

Materials and Method: 35 healthy Iranian children were divided randomly to two groups: group I (25 patients) treated by removable expansion appliance and group II (10 patients) treated by spring- loaded expansion appliance. The active phase of expansion was monitored and arch sizes of the upper dental arches (inter- canine, inter- premolar, inter- molar and arch perimeter) were measured with a caliper on casts monthly. The patients requested to mark the intensity estimation of their discomforts during wearing of appliance on questionnaires which comprised 12 statements. The scores of individual question were added up to obtain a total score. The independent t- test and Mann- Whitney U- test were applied to analyze the data.

Results: There were no significant differences in both groups in the mean of arch size changes in each appointment ($p > 0.05$). There was no significant difference in both groups in terms of the mean of scores of questionnaires ($p = 0.352$).

Conclusion: There was no significant difference in terms of patients' discomfort and arch size changes in spring- loaded and removable expansion appliances. Since the newly designed expansion appliance does not need to be activated by patients, it might be assumed a proper substitute for traditional expansion appliances.

Corresponding Author: Oshagh M. Orthodontic Research Center, Dept. of Orthodontics, School of Dentistry, Shiraz University of Medical Sciences, Shiraz, Iran Tel: 0098-0711-6263193-4 Fax: 0098-0711-6270325 Email: morteza_oshagh@yahoo.com

Introduction

Posterior crossbite is defined as the transversal discrepancy of teeth relationships, because of the narrowing of the upper dental arch compared with the lower dental arch [1]. The prevalence of this malocclusion is between 8% and 16% in different studies [1]. The maxillary expansion will not only restore the proper dental arch range in the mixed dentition, but it will also increase available arch length and provide additional space for subsequent

alignment [2]. An estimated 25-30% of all orthodontic patients can benefit from maxillary expansion [1, 3].

Clinical and histological studies have shown that relapse, micro-trauma of the temporomandibular joint, micro-fractures at the mid-palatal sutures and especially root resorption are observed in rapid maxillary expansion treatment [4]. Also painful experiences occur during the initial phase of rapid palatal expansion [5-7]. To eliminate these disadvantages and obtain increased

physiological tissue reaction, slow maxillary expansion has become more popular [8-9]. Increased fibroblastic, osteoclastic and osteoblastic activity seems to occur when the maxilla is widened slowly [10]. Ohshima concluded that responses to slow maxillary expansion during early mixed dentition period were more favorable than the responses to rapid maxillary expansion [11]. It has been reported that slow maxillary expansion procedures produce less tissue resistance in the circum-maxillary structures and improved bone formation in the inter-maxillary sutures, and that both factors increase post-treatment stability [12]. Zimring and Isaacson and also Isaacson, Wood and Ingram have suggested that slower rates of expansion would allow for a physiologic adjustment at the maxillary articulations and would prevent the accumulation of large residual loads within the maxillary complex [13-14]. The application of light, continuous forces in areas of periosteal growth allows normal arch dimensions to develop at any age without undue tipping of the abutment teeth [10].

There are numerous appliances for the palatal expansion by changing the rate of expansion and form of the appliance with the aim of placing the maxillary dental arch in a stable lateral position [15-16]. Expansion screws like Hyrax, Haas and other types, produce heavy interrupted forces which are unfavorable for dental movement and could be harmful to the tooth and periodontium. The other disadvantage of these screws is the need for patient cooperation for their regular activation. A new spring-loaded expansion screw was designed and fabricated in the same dimension, with conventional types. In comparison with heavy and interrupted forces of other screws, the newly designed screw created light and continuous forces. The other advantage of this expansion appliance is elimination of the need for activation by the patient [17]. The main aim of this study was to investigate the effects of the designed spring-loaded expansion screw on dental arch dimensions.

Insertion of an upper removable appliance changes the oral environment and adaptation difficulties have been reported [18-20]. Speech disturbances are known to be among the major concerns of upper removable appliance wearers [19]. The only existing evidence of a possible effect of a removable appliance on taste sensation originates from adult patients using full maxillary dentures who often complain about disturbed taste

sensation [21]. The purpose of this study was to compare the effects of removable slow maxillary expansion and newly designed spring-loaded expansion screw on dental arch dimensions. Further objective of this study was comparison of the discomforts reported by patients who were treated by traditional and designed expansion appliances.

Materials and Method

Sample

The sample included Iranian children with maxillary bilateral crossbites caused by basal apical narrowness referred to the Orthodontic Department of Shiraz Dental School concurrently showing a class I or II molar relationship. The sample for this study consisted of 35 healthy Iranian children, 11 boys and 24 girls, ranging in ages from 8 to 14 years. Since the optimal age for expansion is before 13 to 15 years old [22] the children were in the first transitional period with the first permanent upper molars erupted [23].

To evaluate growth potential, hand-wrist radiographs were obtained from all of the patients and if radiologist's report confirmed the growth potential, the patient was included in the study. Including criteria were existence of posterior cross bite and growth potential. All subjects were free of systemic diseases, and had not had previous orthodontic treatment. Patients requiring headgear or an auxiliary component or patients with cleft palate, anterior crossbite and extractions were excluded from the study.

Treatment procedures were fully explained and parental informed written consent forms for the study were gained. Ethical approval for this study was obtained from the ethical committee at the Shiraz University of Medical Sciences.

Therapy

Of the original group of patients, one individual failed to complete all the scheduled examination sessions. Therefore the final number of participants was 35.

Two groups were constructed randomly: group I with 25 patients (19 girls, 6 boys. Mean skeletal age: 9.85 ± 1.87 years) treated by a removable expansion appliance (Expansion screw (Dentaurum, Ispringen, Germany) (Figure 1a) and group II with 10 patients (5 girls, 5 boys. Mean skeletal age: 11.20 ± 2.46 years) treated by

a spring- loaded expansion appliance (Figure 1b). Appliances were randomly assigned and randomization was accomplished by a randomization table. The patients were selected without considering their skeletal properties or sex and were divided into two groups. The patient and the operator who performed statistical analysis were blinded to which group each patient belonged.

In both groups screws were embedded in the acrylic base which had a thickness of at least 1mm. The expansion screw in both groups was placed in the acrylic plate parallel to the occlusal plane of the upper teeth and also parallel to the second primary molars. The resin on the palate extended to the first permanent molars. For patient comfort and for mechanical advantage, the screws were positioned as superiorly as possible in the palatal vault without impinging on the maxillary soft tissue [22]. The split acrylic removable plates in both groups had a midline screw, Adams clasps on the first permanent molars and labial arch between the canines. All of the removable appliances used were constructed at the same orthodontic laboratory utilizing self- curing acrylic and stainless steel wires. The appliances were prepared approximately 24-48 hours before delivery to the patient, rinsed in water, dried and stored in sealed nylon bags. No other device was simultaneously used during treatment time. However, each patient received orthodontic treatment according to their individual needs after the expansion period.

The patients in both groups were advised regarding what they were likely to experience in the first days of appliance therapy. The plate was worn 24 hours a day, except during meals, brushing and contact sports. Appliances were not activated for the first 2 weeks but were activated as appropriate at 1 and 2 months following insertion.

Group I

The expansion screw used in this group was a usual non-spring-loaded jackscrew. The parents were instructed to activate the jackscrew a quarter turn (90° rotation of the screw) two times a week. Each activation opens the appliance 0.25 millimeter [22]. At regular intervals, the distance between the two halves of the expansion screw was measured to determine how much the screw had been turned. If discrepancy existed between that measurement and the turn schedule, it was discussed

with the parents (Figure 1a).

Group II

The expansion screw used in this group was a designed spring- loaded screw. This screw, has a metallic cylinder with 3.3 mm outer diameter and a piston, both of which are made of stainless steel, and a stainless steel spring is positioned inside the cylinder (Free wire length: 12 mm, initial compression: 4.5 mm, spring wire diameter: 0.4 mm, spring diameter: 3 mm, number of the coils: 9, material: Stainless steel). Some grooves are positioned on the free portion of the piston, and the other part can move within the cylinder. A bead is also placed on the piston, which can rotate and move on the grooves. The screws in group II were activated by the orthodontist every month. The other advantage of the spring- loaded expansion screw is elimination of the need for activation by the patient. In screw fabrication, the spring within the screw gets compressed. Keeping the screw compressed, a ligature wire is soldered to both screw ends. After screw insertion within the acrylic base, cutting the soldered ligature wire by the orthodontist would free the compressed spring and the piston is pushed out of cylinder and the expansion began. This designed screw is re-activated by turning a nut by the clinician to compress a coil [17] (Figure 1b).

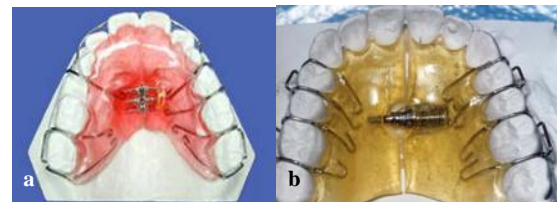


Figure 1a Removable expansion appliance **b** Newly designed maxillary expansion screw

The patients were treated by one orthodontist (M.O), following the same protocol. The active phase of expansion was monitored monthly until the buccal segments were overcorrected by a half cusp. The activation was discontinued after sufficient expansion was achieved and the palatal cusp of the upper molar was in a similar plane to the buccal cusp of lower molar. All examinations were performed in a dental chair.

Dental cast analysis

The patients were monitored monthly. At each month the appliance was removed in order to facilitate

impressions, then replaced and used. Arch size changes were determined from maxillary casts made monthly by means of measurements on dental casts at the following time points: before treatment, every month during active treatment. The arch sizes of the upper dental arches were measured at the following reference points which were marked with 0.3 mm pencil on casts:

- a) Tips of the canines.
- b) Maxillary premolars at the central fossa or maxillary primary molars at the posterior groove of the transverse fissure.
- c) Maxillary first permanent molars at the point of intersection of the transverse fissure with the buccal fissure.
- d) Maxillary incisors at the mesial edges of maxillary central incisors.
- e) Arch perimeter was also measured from mesial contact point of upper first molars along the line of occlusion [16].

Measurements and location of landmarks were manually conducted by a single investigator for all two groups. The measurements were made to the nearest 0.01 millimeter with a digital caliper (Mitutoyo corp.-Tokyo- Japan- Digimatic caliper, No 50 -652). For precise measurement, the digital caliper was hold in the direction of lines and the investigator avoided inclined direction of caliper during measurements.

Error of the method

The measurements of the dental casts were repeated twice and the mean of two measurements was recorded. If the two measurements differed by more than 0.1 millimeter, a third measurement was made and averaged with the first two.

Questionnaire for discomforts

Data collection about patients' discomfort was accomplished by a questionnaire which was prepared with simple sentences and words by two expert orthodontists. It comprised 12 statements which were used to assess the patients' discomforts during wearing of appliances: these statements were about tissue irritation, metal taste, poor fitness of appliance, loose appliance, pain, gingival irritation, salivary overflow, palatal erythema and irritation, discomfort in insertion and removal of appliance and discomfort in speech. Reliability of the

questionnaire was measured by Cronbach's alpha test (Cronbach's $\alpha = 0.682$).

Validity of the questionnaire was also verified by two expert orthodontists. It comprised questions with a closed response format that allowed subjects to choose from a fixed number of alternatives, thus providing greater uniformity of responses. Each question was assigned a score based on a 4 point Likert scale in which 0 represented "no discomfort", 1 and 2 represented "a moderate discomfort", 3 represented "definite discomfort" and 4 represented "severe discomfort". Each choice was assigned a different numerical score for subsequent analysis and the scores of individual question were added up to obtain a total score.

The questionnaires were given to the parents with instructions to be filled out at home at every month which they were visited by the orthodontist. They were instructed to start to answer the questions from the third day after appliance delivery. The patients or their parent requested to mark the intensity estimation of their discomforts on questionnaires and returned the completed questionnaires to the practitioner at the next session. The entire testing procedure was repeated in every session. The subjects were instructed to make a single and decisive, clearly visible mark on each of the scales, according to their best subjective judgment. They also instructed to answer as many of the questions as they could and to leave blank any that they were unable to complete.

Statistical analysis

The independent t-test for paired data was applied to evaluate the treated group. For evaluation of data from questionnaires the Mann-Whitney U-test was used. The statistical package for social science (SPSS Inc., 10.0 Chicago, Illinois, USA) was used for statistical analysis. The results were considered to be significant at values below $p < 0.05$.

Results

The mean duration of treatment was 5.3 months. There were no statistically significant differences between the treatment groups at baseline. There was no significant difference in mean of skeletal age from hand-wrist radiographs between group I (removable expansion appliance group: 9.85 ± 1.87 years) and group II (spring-

Table 1 The mean and standard deviation and p.value of parameters (inter- molar, inter- premolar width, inter- canine width, inter- incisal distance and arch perimeter) during treatment in new appliance and traditional appliance groups (in millimeters).

	Spring- loaded expansion appliance group (Mean \pm SD) (in mm)	Removable expansion appliance group (Mean \pm SD) (in mm)	p.value
Inter- molar width	46.958 \pm 1.851	45.319 \pm 2.892	0.002
Inter- second premolar width	42.002 \pm 2.542	40.087 \pm 3.472	0.003
Inter- first premolar width	37.137 \pm 2.911	34.962 \pm 3.14	\leq 0.001
Inter- canine width	35.444 \pm 3.805	32.871 \pm 3.561	\leq 0.001
Inter- incisal distance	1.308 \pm 1.181	1.219 \pm 1.034	0.682
Arch perimeter	84.177 \pm 8.156	76.103 \pm 5.437	\leq 0.001

loaded expansion appliance: 11.20 \pm 2.46 years) at the initiation of treatment ($p = 0.089$). All of the data had a normal distribution according to Kulmogrove- Smirnov test ($p > 0.05$). There was no significant difference before treatment between two groups in terms of inter- second premolar width ($p = 0.154$), inter- canine width ($p = 0.078$) and inter- incisal distance ($p = 0.403$). Inter- molar width ($p = 0.042$), inter- first premolar width ($p = 0.038$) and arch perimeter ($p = 0.006$) were significantly higher in group II (spring- loaded expansion appliance) before treatment.

Mean of parameters during treatment

The mean of inter- molar width ($p = 0.002$), inter- premolar width ($p \leq 0.003$), inter- canine width ($p \leq 0.001$) and arch perimeter ($p \leq 0.001$) were significantly higher in spring- loaded appliance group than the removable expansion group during treatment. The mean inter- incisal distance was not significantly different in both groups during treatment ($p = 0.682$) (Table 1).

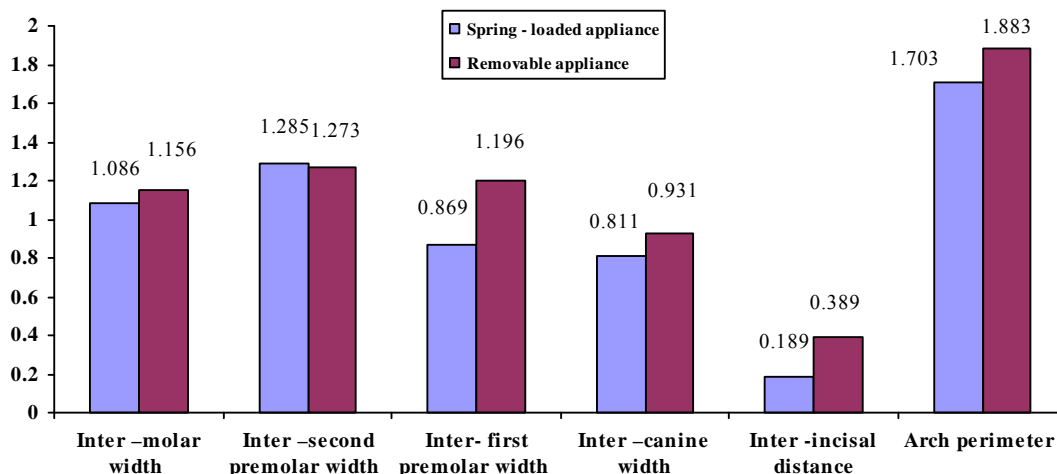
Difference between pre- and post- treatment

The increase of inter- molar width in group I (remov-

able expansion appliance group) was 1.26- 5.85 mm was 1.09 \pm 1.156mm and in group II was 1.022 \pm 1.86mm. There were no significant differences in both groups in the mean of changes in each appointment in inter- molar width ($p = 0.778$), inter- premolar width ($p = 0.356$), inter- canine width ($p = 0.542$), inter- incisal distance ($p = 0.071$) and arch perimeter ($p = 0.745$) (Figure 2) and in group II (spring- loaded expansion appliance) was 0.69- 5.05 mm. The increase of inter- first premolar width in group I (removable expansion appliance group) was 0.13- 5.87 mm and in group II (spring- loaded expansion appliance) was 0.35- 3.99 mm. The differences between the means of most of the parameters before and after treatment were not significantly different in both groups ($p > 0.05$). Only the change of inter- incisal distance was significantly higher in group I (removable expansion appliance group) than group II (spring- loaded expansion appliance) ($p = 0.005$).

Comparison between the groups

Group I (removable expansion appliance group) showed an increase for both inter- canine width (0.931 \pm 0.869

**Figure 2** The mean on change in parameters (inter- molar width, inter- premolar width, inter- canine width, inter- incisal distance and arch perimeter) in each appointment during treatment by new appliance and traditional appliance.

mm) and inter- molar width (1.156 ± 1.09 mm) in each appointment. Group II (spring- loaded expansion appliance) showed an increase for inter- canine width (0.811 ± 0.794 mm) and inter- molar width (1.086 ± 1.022 mm) in each appointment ($p > 0.05$). The ratio of expansion in inter- molar to inter- canine width was 1.28 in group I and 1.3 in group II in each appointment.

The monthly increase of inter- molar width in group I. appliance) showed an increase for inter- canine width (0.811 ± 0.794 mm) and inter- molar width (1.086 ± 1.022 mm) in each appointment ($p > 0.05$). The ratio of expansion in inter- molar to inter- canine width was 1.28 in group I and 1.3 in group II in each appointment. The mean change of inter- molar width during each appointment was not significantly different in boys and girls in both groups ($p > 0.05$).

Discomforts of patients during treatment period

There was no significant difference in both groups in terms of the mean of scores of questionnaires ($p = 0.352$) None of the patients had tissue irritation, discomfort in insertion and removal of the appliance, gingival pain irritation and palatal irritation. The most common discomforts of both groups were moderate speech discomfort (in 5.7 % of the patients) and severe salivary overflow (in 2.9% of the patients). In spring- loaded appliance group, girls had significantly more discomforts than boys ($p = 0.028$) but in another group, there was no significant difference between boys and girls in terms of discomforts ($p = 0.203$)

The duration of treatment was divided to two halves and it was found that the discomforts of patients in both groups were significantly more in the first half of treatment duration ($p = 0.029$). Therefore, all aspects of appliances were more tolerable with the passage of time.

Discussion

This study assessed patients with mixed dentitions, as it is known that orthopedic results are more effective within this time span [2]. The optimal age for expansion is before 13 to 15 years of age. Although it may be possible to accomplish expansion in older patients, the results are not predictable and stable [22]. The studies have shown a relation between the complexity increase of the mid-palatal suture with age and it has been

suggested that the preferred treatment time is in the late mixed dentition period [2, 24].

In this study the mean change of inter- molar width during each appointment was not significantly different in boys and girls in both groups. It is in agreement to the results of other studies which showed that sexual differences in frontal cephalometric variables are noticed only after puberty [25-26].

In several studies changes in maxillary inter- canine and inter- molar widths have recorded through maxillary expansion [27-28]. In the present study the mean changes of arch sizes in each appointment was not different in both groups. Also the expansion of the inter- canine width was less than that in the inter- molar area. As the appliances used in this study were not anchored to canine teeth, this result is not a surprise. The longer treatment time in slow maxillary expansion permits the pre oral muscles to be more effective on upper canines [16]. But Mossaz-Joelson and Mossaz noted that inter- canine width showed a smaller increase than inter- molar width in the maxillary arch, both in bonded and banded Minne expander groups [29]. This is in agreement with the findings of Akkaya et al. [16]. Contrary to these findings, it has been reported that opening of the mid- palatal suture is greater in the anterior than posterior region [30]. The different findings might be attributed to the differences in the landmarks evaluated between studies [31]. It is also important to consider how much of the increase in inter- canine width is due to growth and how much to maxillary expansion. Many authors reported a significant increase in inter- canine width during the eruption of the permanent incisors and a further small increase as the permanent canine erupts [23, 32-33]. Sillman [34], Knott [35] and Bishara et al. [36] noted an increase in the inter- canine width until 13 years. The increase found in the present investigation in younger patients may be due to the appliance producing earlier growth in the inter- canine area. Further, long-term studies are necessary to evaluate the "real" amount of inter- canine growth during expansion.

In this study the increase of inter- molar width in group I (removable expansion appliance group) was 1.26-5.85 mm and in group II (spring- loaded expansion appliance) was 0.69-5.05 mm. this great range of changes might be attributed to the fact that duration of

treatment was different in different patients.

The monthly increase of inter- molar width in group I was 1.09 ± 1.156 mm and in group II was 1.022 ± 1.86 mm. Aspects such as the age of the patient at the beginning of treatment and the patient's compliance may have contributed to the differences of studies [1,37].

In this study there was no significant difference in both groups in terms of the discomforts reported by the patients during treatment but the tissues beneath the appliance were erythematous, and sharply demarcated depressions were noted. These are usual reversible findings in usage of removable appliances. All acrylic appliances have the potential for palatal mucosal ulcerations [1]. Acrylic allergy, which is a "burning" sensation of the mucosa underlying in the base plate, would have been reported early after insertion of the first upper removable appliance and there would be erythema of all of the soft tissues adjacent to the acrylic. Drouk et al. did not report any unusual symptoms such as pain or dizziness in any of the patients [38]. They noticed hyperemia on the palatal mucosa and gums in all patients however it disappeared spontaneously in few days soon after appliance removal [38]. It must be stated that they did not evaluate patients' discomfort objectively. Oliver and Knapmann found no difference in the level of discomfort produced by fixed or removable appliances [39]. Maxillary expansion appliances utilize mechanical forces which when applied are absorbed and transmitted to the craniofacial complex. These forces will produce a series of reactions characterized by tissue displacement, deformation and development of internal stress [40-41]. As part of the inflammatory process, the patient perceives a painful sensation, which is often expressed in the whole craniofacial region [42].

In this study the patients were instructed to start to answer the questions from the third day after appliance delivery because Erdinc and Dincer stated that there was a decrease in the severity of discomfort and the number of patients experiencing it from day 3 onwards [43]. Most discomforts relating to discomfort and pain resolved within 4-7 days [18]. Orthodontic treatment may be an uncomfortable process and orthodontic appliances represent foreign objects inserted in a physically and psychologically sensitive area of the body [18].

This study showed that the discomforts of patients

in both groups were significantly more in the first half of treatment duration. It is comparable to Stewart et al.'s study which showed that most aspects of appliance wear became more tolerable with the passage of time. As exception was "salivary flow" which was permanently affected in fixed and removable groups. They also stated that even after 3 months, there is still a perceived influence upon speech [18].

In this study none of the patients had tissue irritation, discomfort in insertion and removal of the appliance, gingival pain and palatal irritation. The most common discomfort of both groups was moderate speech discomfort and severe salivary overflow. It is comparable to Stewart et al.'s study which showed that removable appliances cause salivary overflow and disturb speech and swallowing [18]. The bulk of the appliance may interfere with the usual mobility of the tongue and cheeks. This might cause moderate discomfort in speech [20]. Based on prosthetic clinical reports, it can be assumed that the mere presence of a removable appliance covering the palate could disturb normal oral functions [44, 45]. In Sandikcioglu et al.'s study the patients in hyrax group had difficulties in swallowing and talking during the first few days [1] but in their study the discomforts were not asked from patients separately and by questionnaires.

In this study, the patients did not have their previous responses available to them when answering the next questionnaires, and it is possible that this may have had an influence in that the element of self-calibration may have been lost, making some of the later responses less reliable [18]. The advantage of the spring- loaded expansion screw is elimination of the need for activation by the patient.

In this study every parameter was measured twice and the mean of them was recorded. Knowledge of the measurement error is essential in judging the clinical significance of any reported statistically significant findings [31]. With this two times measurements, the error was reduced.

Most of the works, including the present one, have been done with a relatively small number of subjects due to the inclusion criteria (age group, presence of specific teeth) and the few available designed appliances. Because of this, the employment of meta- analysis in future studies will be very helpful to the scientific

community by increasing sample size, testing statistical power, dealing with the uncertainties of controversial studies and finally responding to questions poorly clarified in individual tests [2].

Most of the studies evaluated crossbite correction on study casts mostly by measuring the inter-canine and inter- molar distances [34, 46-47]. Although our study also evaluated in this way but this method could not exclude bias in assessing the success of crossbite correction due to tipping of the buccal teeth. To overcome this discomfort, palatal volume measurement is recommended [48].

Slow expanders can separate the maxilla, particularly in the deciduous and mixed dentitions [22]. Skeletal changes are estimated to be 16% to 30% of the total change and vary with age [12]. The ratio of skeletal to dental changes was not measured in this study since this bony change might have necessitated the use of implants or extra radiographs. The manner in which expansion occurred was unpredictable and with asymmetry the rule rather than the exception [49]. Brossman et al. attributed this phenomenon to variation in the rigidity of skeletal articulations between maxillary segments, which may also account for the asymmetrical changes [50]. The symmetric or asymmetric changes were not considered in this study.

After expansion, a tendency exists for the teeth to tip back toward their pretreatment values [49]. Although this relapse tendency was not considered in this study, but this relapse tendency has been attributed to a number of factors: accumulated forces in the circum-maxillary articulations [50], occlusal forces, the surrounding buccal musculature [51] and the stretched fibers of the palatal mucosa as theorized by Maguerza [52]. To decrease this tendency, palatal retainers, trans-palatal bars or fixed appliances with expanded wires should be considered [49]. Due to this anticipated post-expansion relapse, overcorrection of the transverse discomfort is widely recommended [27] which was accomplished in this study.

Depending on the desired treatment objectives, the orthodontist must consider the design of each expansion device in choosing the appropriate appliance [49] and scientific evidence alone does not automatically dictate the selection of an appliance. A combination of values from the patient and professional (clinical, personal and

social) should determine whether the designed appliance benefits are worth the costs. Therefore, the application of evidence into clinical practice has to be related to professional expertise and patient value needs [33].

Conclusion

There was no significant difference in terms of patients' discomforts and arch size changes in spring- loaded and traditional removable expansion appliances. Since the newly designed expansion appliance does not need to be activated by patients, it might be assumed a proper substitute for traditional expansion appliances.

Acknowledgment

This manuscript has been derived from undergraduate thesis, No. 1201, Shiraz University of Medical Sciences, Dental Faculty.

References

- [1] Sandikçiöglu M, Hazar S. Skeletal and dental changes after maxillary expansion in the mixed dentition. *Am J Orthod Dentofacial Orthop* 1997; 111: 321-327.
- [2] Claro CA, Abrão J, Reis SA, de Fantini SM. Correlation between transverse expansion and increase in the upper arch perimeter after rapid maxillary expansion. *Braz Oral Res* 2006; 20: 76-81.
- [3] Ten Hoeve A. Palatal bar and lip bumper in nonextraction treatment. *J Clin Orthod* 1985; 19: 272-291.
- [4] Langford SR. Root resorption extremes resulting from clinical RME. *Am J Orthod* 1982; 81: 371-377.
- [5] Handelman CS. Nonsurgical rapid maxillary alveolar expansion in adults: a clinical evaluation. *Angle Orthod* 1997; 67: 291-305.
- [6] Needleman HL, Hoang CD, Allred E, Hertzberg J, Berde C. Reports of pain by children undergoing rapid palatal expansion. *Pediatr Dent* 2000; 22: 221- 226.
- [7] Schuster G, Borel-Scherf I, Schopf PM. Frequency of and complications in the use of RPE appliances--results of a survey in the Federal State of Hesse, Germany. *J Orofac Orthop* 2005; 66: 148- 161.
- [8] Mew J. Relapse following maxillary expansion. A study of twenty-five consecutive cases. *Am J Orthod* 1983; 83: 56-61.
- [9] Vardimon AD, Graber TM, Voss LR, Lenke J. Determinants controlling iatrogenic external root resorption and repair during and after palatal expansion. *Angle Orthod*

- 1991; 61: 113-122.
- [10] Corbett MC. Slow and continuous maxillary expansion, molar rotation, and molar distalization. *J Clin Orthod* 1997; 31: 253-263.
- [11] Ohshima O. Effect of lateral expansion force on the maxillary structure in cynomolgus monkey. *Osaka Dent Univ* 1972; 6: 11-50.
- [12] Bell RA. A review of maxillary expansion in relation to rate of expansion and patient's age. *Am J Orthod* 1982; 81: 32-37.
- [13] Zimring JF, Isaacson RJ. Forces produced by rapid maxillary expansion.3. Forces present during retention. *Angle Orthod* 1965; 35: 178-186.
- [14] Isaacson RJ, Wood JL, Ingram AH. Forces produced by rapid maxillary expansion. *Angle Orthod* 1964; 34: 256-270.
- [15] Akkaya S, Lorenzon S, Uçem TT. A comparison of sagittal and vertical effects between bonded rapid and slow maxillary expansion procedures. *Eur J Orthod* 1999; 21: 175-180.
- [16] Akkaya S, Lorenzon S, Uçem TT. Comparison of dental arch and arch perimeter changes between bonded rapid and slow maxillary expansion procedures. *Eur J Orthod* 1998; 20: 255-261.
- [17] Oshagh M, Momeni Danaei SH, Hematian MR, Oshagh MR, Zade AH, Saboori AA. In vitro evaluation of force-expansion characteristics in a newly designed orthodontic expansion screw compared to conventional screws. *Indian J Dent Res* 2009; 20: 437-441.
- [18] Stewart FN, Kerr WJ, Taylor PJ. Appliance wear: the patient's point of view. *Eur J Orthod* 1997; 19: 377-382.
- [19] Sergl HG, Zentner A. A comparative assessment of acceptance of different types of functional appliances. *Eur J Orthod* 1998; 20: 517-524.
- [20] Har-Zion G, Brin I, Steiner J. Psychophysical testing of taste and flavour reactivity in young patients undergoing treatment with removable orthodontic appliances. *Eur J Orthod* 2004; 26: 73-78.
- [21] Bates JF, Murphy WM. A survey of an edentulous population. *Br Dent J* 1968; 124: 116-121.
- [22] Bishara SE, Staley RN. Maxillary expansion: clinical implications. *Am J Orthod Dentofacial Orthop* 1987; 91: 3-14.
- [23] Van der Linden FPGM, Duterloo HS. Development of the human dentition. Medical Dept., Harper & Row, 1976. p. 77.
- [24] Viazis AD. Efficient orthodontic treatment timing. *Am J Orthod Dentofacial Orthop* 1995; 108: 560-561.
- [25] Athanasiou AE, Droschl H, Bosch C. Data and patterns of transverse dentofacial structure of 6- to 15-year-old children: a posteroanterior cephalometric study. *Am J Orthod Dentofacial Orthop* 1992; 101: 465-471.
- [26] Bartzela T, Jonas I. Long-term stability of unilateral posterior crossbite correction. *Angle Orthod* 2007; 77: 237-343.
- [27] Haas AJ. Palatal expansion: just the beginning of dentofacial orthopedics. *Am J Orthod* 1970; 57: 219-255.
- [28] Haas AJ. The treatment of maxillary deficiency by opening the midpalatal suture. *Angle Orthod* 1965; 35: 200-217.
- [29] Mossaz-Joëls K, Mossaz CF. Slow maxillary expansion: a comparison between banded and bonded appliances. *Eur J Orthod* 1989; 11: 67-76.
- [30] Ekström C, Henrikson CO, Jensen R. Mineralization in the midpalatal suture after orthodontic expansion. *Am J Orthod* 1977; 71: 449-455.
- [31] Lagravere MO, Major PW, Flores-Mir C. Long-term skeletal changes with rapid maxillary expansion: a systematic review. *Angle Orthod* 2005; 75: 1046-1052.
- [32] Cozzani M, Guiducci A, Mirengi S, Mutinelli S, Siciliani G. Arch width changes with a rapid maxillary expansion appliance anchored to the primary teeth. *Angle Orthod* 2007; 77: 296-302.
- [33] Moorrees CF, Gron AM, Le Bret LM, Yen PK, Fröhlich FJ. Growth studies of the dentition: a review. *Am J Orthod* 1969; 55: 600-616.
- [34] Sillman JH. Dimensional changes of dental arches. Longitudinal study from birth to 25 years. *Am J Orthod* 1964; 50: 824-831.
- [35] Knott VB. Longitudinal study of dental arch widths at four stages of dentition. *Angle Orthod* 1972; 42: 387-394.
- [36] Bishara SE, Jakobsen JR, Treder J, Nowak A. Arch width changes from 6 weeks to 45 years of age. *Am J Orthod Dentofacial Orthop* 1997; 111: 401-409.
- [37] Lima Filho RM, Ruellas AC. Long-term anteroposterior and vertical maxillary changes in skeletal class II patients treated with slow and rapid maxillary expansion. *Angle Orthod* 2007; 77: 870-874.
- [38] Doruk C, Bicakci AA, Basciftci FA, Agar U, Babacan H. A comparison of the effects of rapid maxillary expansion and fan-type rapid maxillary expansion on dentofacial structures. *Angle Orthod* 2004; 74: 184-194.

- [39] Oliver RG, Knapman YM. Attitudes to orthodontic treatment. *Br J Orthod* 1985; 12: 179-188.
- [40] Mao JJ. Mechanobiology of craniofacial sutures. *J Dent Res* 2002; 81: 810-816.
- [41] Mao JJ, Wang X, Kopher RA. Biomechanics of craniofacial sutures: orthopedic implications. *Angle Orthod* 2003; 73: 128-135.
- [42] Krishnan V. Orthodontic pain: from causes to management--a review. *Eur J Orthod* 2007; 29: 170-179.
- [43] Erdinç AM, Dinçer B. Perception of pain during orthodontic treatment with fixed appliances. *Eur J Orthod* 2004; 26: 79-85.
- [44] McHenry KR. Oral prosthesis and chemosensory taste function. A review of the literature. *N Y State Dent J* 1992; 58: 36-38.
- [45] Steas AD. Overcoming altered taste sensation in complete denture wearers. *J Prosthet Dent* 1997; 77: 453.
- [46] Thilander B, Lennartsson B. A study of children with unilateral posterior crossbite, treated and untreated, in the deciduous dentition--occlusal and skeletal characteristics of significance in predicting the long-term outcome. *J Orofac Orthop* 2002; 63: 371- 383.
- [47] Petré S, Bondemark L. Correction of unilateral posterior crossbite in the mixed dentition: a randomized controlled trial. *Am J Orthod Dentofacial Orthop* 2008; 133: 790.e7- 13.
- [48] Primožic J, Ovsenik M, Richmond S, Kau CH, Zhurov A. Early crossbite correction: a three-dimensional evaluation. *Eur J Orthod* 2009; 31: 352- 356.
- [49] Asanza S, Cisneros GJ, Nieberg LG. Comparison of Hyrax and bonded expansion appliances. *Angle Orthod* 1997; 67: 15-22.
- [50] Brossman RE, Bennett CG, Merow WW. Facioskeletal remodelling resulting from rapid palatal expansion in the monkey (*Macaca cynomolgus*). *Arch Oral Biol* 1973; 18: 987-994.
- [51] Bishara SE, Staley RN. Maxillary expansion: clinical implications. *Am J Orthod Dentofacial Orthop* 1987; 91: 3-14.
- [52] Muguierza OE, Shapiro PA. Palatal mucoperiostomy: an attempt to reduce relapse after slow maxillary expansion. *Am J Orthod* 1980; 78: 548-558.