

## Original Article

## Effect of Beta-Blockers on Number of Osteoblasts and Osteoclasts in Alveolar Socket Following Tooth Extraction in Wistar Rats

Katayoun Sadr<sup>1</sup>, Amirala Aghbali<sup>2</sup>, Makan Sadr<sup>3</sup>, Hamed Abachizadeh<sup>1</sup>, Maryam Azizi<sup>4</sup>, Mehran Mesgari Abbasi<sup>5</sup>

<sup>1</sup> Dept. of Prosthodontics, Faculty of Dentistry, Tabriz University of Medical Sciences, Tabriz, Iran.

<sup>2</sup> Dept. of Oral and Maxillofacial Pathology, Faculty of Dentistry, Tabriz University of Medical Sciences, Tabriz, Iran.

<sup>3</sup> MD, PhD of Anatomy, Tracheal Diseases Research Center, National Research Institute of Tuberculosis and Lung Disease, Shahid Beheshti University of Medical Sciences, Tehran, Iran.

<sup>4</sup> PhD Student of Anatomy, Dept. of Anatomy, School of Medicine, Tehran University of Medical Sciences, Tehran, Iran.

<sup>5</sup> Doctor of Veterinary Medicine, Drug Applied Research Center, Tabriz University of Medical Sciences, Tabriz, Iran.

### KEY WORDS

Osteoclast;  
Osteoblast;  
Propranolol;  
Alveolar bone;  
Rat;

Received February 2016;  
Received in Revised form June 2016;  
Accepted July 2016;

### ABSTRACT

**Statement of the Problem:** Various researchers have suggested the use of  $\beta_2$ -adrenergic receptor antagonists in prevention or treatment of bone resorption.

**Purpose:** This study aimed to evaluate the effect of  $\beta_2$ -adrenergic receptor antagonists on number of osteoclasts and osteoblasts involved in the healing of extraction socket of maxillary first molar in rats.

**Materials and Method:** Maxillary first molars of 40 rats were extracted and divided into two groups. The test group received 0.1 mg/kg propranolol intraperitoneally daily. The controls received normal saline. At days 7, 14, 21 and 28 post-extraction, 5 rats were euthanized from each group. Maxillary bone was resected and the mean number of osteoblasts and osteoclasts in tooth socket was measured.

**Results:** After 1 week, the number of osteoclasts in the controls was significantly higher than the test group. A significant increase in the number of osteoclasts in both groups at week 1 was observed compared to the following weeks ( $p < 0.05$ ). The number of osteoblasts in the controls at second week reached its maximum rate but stayed constant in the 3<sup>rd</sup> and 4<sup>th</sup> weeks. Osteoblasts in the test group increased similar to the controls but reached its maximum at 3<sup>rd</sup> week and showed a significant increase compared to the controls ( $p < 0.05$ ).

**Conclusion:**  $\beta_2$  adrenergic receptor antagonists decrease the number of osteoclasts and increase the number of osteoblasts during extraction socket healing.

**Corresponding Author:** Sadr M., Tracheal Diseases Research Center, National Research Institute of Tuberculosis and Lung Disease, Shahid Beheshti University of Medical Sciences, Tehran, Iran.  
Tel: +98-9123018277 Fax: +98-21-26109848 Email: [sadr.makan@gmail.com](mailto:sadr.makan@gmail.com)

Cite this article as: Sadr K., Aghbali A., Sadr M., Abachizadeh H., Azizi M., Mesgari Abbasi M. Effect of Beta-Blockers on Number of Osteoblasts and Osteoclasts in Alveolar Socket Following Tooth Extraction in Wistar Rats. *J Dent Shiraz Univ Med Sci.*, 2017 March; 18(1): 37-42.

### Introduction

After tooth extraction, the healing process initiates however, alveolar socket never reaches its previous dimensions either buccolingually or apicocoronally. [1] Additionally, the remaining bone structure after healing undergoes a progressive resorption (catabolic remodeling). Resorption in the first 6 months after extraction is very fast; however, it slows down and mildly continues for the rest of the person's life. Successful replacement of lost teeth through conventional prosthodontic treatments

or implant placement is challenging in an atrophic alveolar ridge. [1-2] Bone loss compromises the support, retention, stability, and esthetics of dental prosthetics along with the health of the remaining tissues. [3]

Bone mass is regulated through the process of remodeling which includes two phases including bone formation by osteoblasts and bone resorption by osteoclasts. Besides, osteoblasts play a role in differentiation of osteoclasts. [4] Recent investigations have demonstrated that central and peripheral nervous sys-

tems play a significant role in regulation of bone mass. [5] Leptin stimulates the sympathetic nervous system [6-7] and this system intrinsically results in increased expression of RANKL (Receptor activator of nuclear factor kappa-B ligand) receptor on their surface by stimulating the  $\beta$ 2-adrenergic receptors on the surface of osteoblasts. The interaction between RANKL and RANK (Receptor activator of nuclear factor kappa-B) on the surface of osteoclasts precursors, transforms them into osteoclasts. [4, 8]

Considering the above mentioned findings, various researchers have suggested the use of  $\beta$ 2-adrenergic receptor antagonists in prevention or treatment of bone resorption. [7-18] Several reports discuss the decreased risk of fracture in those using propranolol which is a non-specific  $\beta$ 2-adrenergic receptor antagonist. [7-18] Takeda *et al.* [7] and Bonnet *et al.* [19] demonstrated that a non-specific  $\beta$ 2-adrenergic receptor antagonist like propranolol can enhance bone formation in female rats that had undergone ovariectomy.

If beta-blockers are truly capable of preventing bone resorption in humans, the above mentioned findings can be successfully implemented in oral cavity for extraction socket healing or prevention of progressive alveolar bone resorption following teeth loss. Therefore, the present study was conducted to evaluate the effect of  $\beta$ 2-adrenergic receptor antagonists on number of osteoblasts and osteoclasts in alveolar socket following tooth extraction in animal models.

### Materials and Method

A total of 40, eight-week old Wistar rats with a mean weight of  $270 \pm 50$  g were selected from an inbred colony. During the study period, the rats were divided into 10 groups of 4 each and kept in a standard cage in a room under controlled conditions with a temperature of  $21 \pm 2^\circ\text{C}$  and  $50\% \pm 7\%$  moisture in 12 hours dark and 12 hours light cycle and free access to standard food and water. The rats were brought to the lab one week before the initiation of study to make them acquainted to the environment. The samples were then randomly divided into 2 equal groups of test and control. Color coding system was used for identification of animals to blind the study.

It should be mentioned that the present study was conducted regarding the ethical guidelines of animal

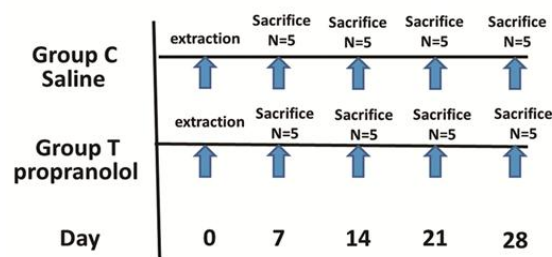
model studies designed by the Research Deputy of the Ministry of Health and was approved by the Ethics Committee of Animal Studies, Tabriz University of Medical Sciences.

### Tooth extraction

Maxillary right first molars of rats in both test and control groups were extracted with an excavator (No.55, SMIC, China) under general anesthesia with IM ketamine hydrochloric acid 44 mg/kg (Rotexmedica, Germany). Hemostasis occurred approximately 5 minutes after tooth extraction and antibiotics or other medications were not administered.

### Drug administration

First, injectable propranolol (Tolidaroo, Iran), a non-specific beta-adrenergic receptor antagonist, was dissolved in sterile saline solution right before injection. It was then injected using an insulin syringe at a dosage of 0.1 mg/kg/day intraperitoneally during the whole study period and at a specific time (11.00 A.M) for all samples in the test group (n=20). The mentioned dosage has been proposed by Bonnet *et al.* [19] as the lowest dosage capable of preventing bone loss without any cardiovascular effect. The same amount of saline solution was injected to the control group (n=20) with the same method. Injections continued in both groups until their sacrifice (Figure 1).



**Figure 1:** The best protocol between control groups (group C) and test groups (group T).

### Histological evaluation of extraction socket

At days 7, 14, 21 and 28 post-extraction, 5 samples of any of the case and control groups were randomly selected and sacrificed using diethyl ether (Pars Chemie, Iran). Maxillary bone was resected and immediately stored and fixed in 10% formalin for 48 hours. Then it was preserved in ethylene diamine tetra acetic (EDTA) 10% at  $4^\circ\text{C}$  and  $\text{pH}=7.2$  for 21 days in order to become decalcified and embedded in paraffin. Tissue blocks were cut serially into 5- $\mu\text{m}$  sections parallel to the sagittal plane using a microtome. We selected sections

**Table 1:** Mean and standard deviation (SD) of osteoblasts (ob) and osteoclasts (oc) in the control (C) and test (T) groups at weeks 1 to 4 post-extraction

	Week 1 Mean (SD)	Week 2 Mean (SD)	Week 3 Mean (SD)	Week 4 Mean (SD)
C-ob	6.35 (3.685)	18.80 (7.88)	16.80 (7.10)*	13.50 (3.23)
T-ob	10.55 (2.906)	23.80 (3.56)	30.00 (9.354)*	20.50 (7.53)
C-oc	12.95 (2.858)*	1.00 (1.62)	2.30 (1.57)*	1.35 (1.57)
T-oc	4.85 (3.29)*	0.00	0.00*	0.40 (0.65)

\* $p \leq 0.05$ 

which contained tooth socket and its surrounding bone structure and were stained with Hematoxylin-Eosin. Osteoclasts and osteoblasts were counted twice by one blinded researcher at 4 random areas in the alveolar socket wall.

#### Statistical analysis

Collected data were analyzed using SPSS version 13 software and included descriptive statistics (mean and standard deviation), unpaired t-test and one-way ANOVA using Fisher's protected least significant difference method.  $p < 0.05$  was considered statistically significant.

#### Results

In the first week following tooth extraction, number of osteoclasts in the control group was significantly higher than the test group receiving propranolol (Table 1 and Figure 2a and 2b).

In the control group, accumulation of osteoclasts was observed not only in the interdental septum but also on the socket floor (Figure 2a and 2b). Also, a significant increase in number of osteoclasts in both groups was observed in the first week compared to the following weeks ( $p < 0.05$ ) (Figures 3a and 3b and Figure 4a and 4b).

The number of osteoblasts in the control group reached its maximum rate in the second week and re-

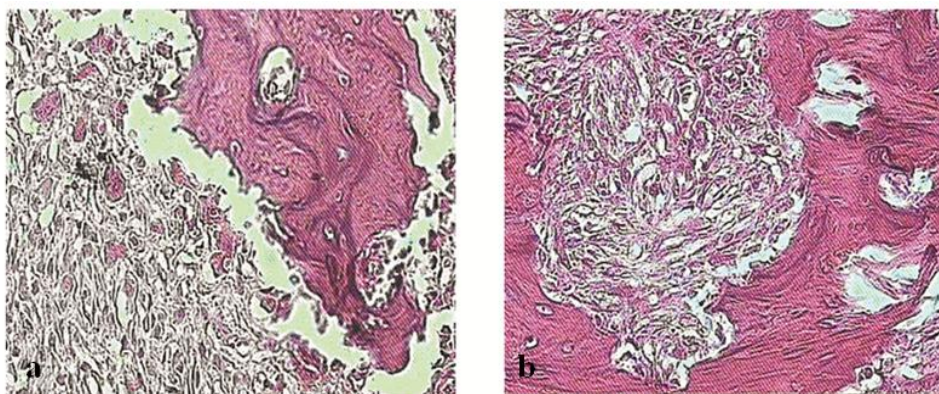
mained constant in the 3<sup>rd</sup> and 4<sup>th</sup> weeks. The number of osteoblasts in the test group receiving propranolol increased similar to the control group but reached its maximum rate at week 3 and demonstrated a significant increase compared to the control group ( $p < 0.05$ ) (Figure 4a and 4b and Figure 5a and 5b). However, a significant reduction in osteoblast number was observed in week 4 (Figure 5a and 5b). Figure 6 demonstrates the difference in trabecular thickness and number and also the width of bone marrow space in the bone covering alveolar socket floor in test and control rats.

#### Discussion

In the present experimental study, we found that  $\beta_2$  adrenergic receptor antagonists could decrease the number of osteoclast and increase the number of osteoblast during extraction socket healing.

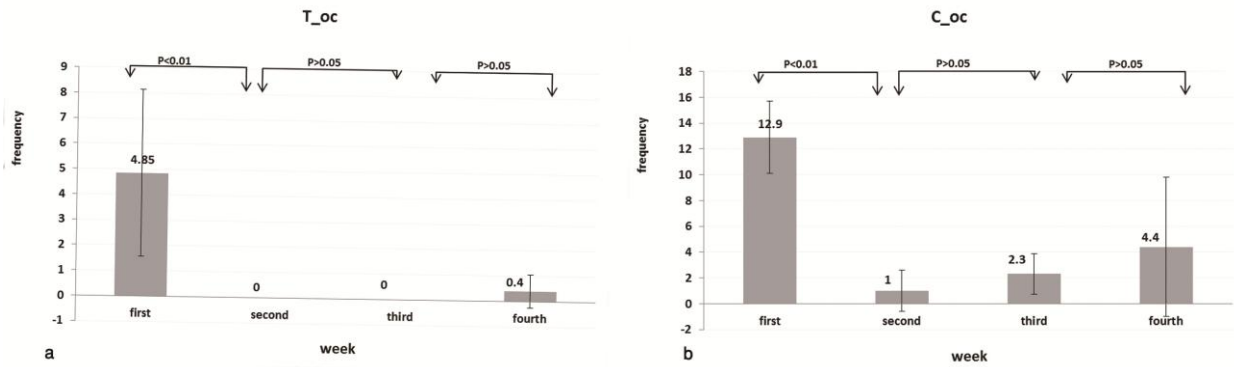
Our study results revealed that in the first week following tooth extraction, when bone resorption is the dominant process, a significant increase was detected in the number of osteoclasts in both groups compared to the following weeks and the number of osteoclasts in the control group was significantly higher than the test group receiving propranolol ( $p < 0.05$ ).

The mechanism of action of beta-blockers in regulating bone mass is through the stimulation of ost-



**Figure 2a:** Accumulation of osteoclasts on the socket wall in the control group. **b:** Socket wall in the test group at week one following tooth extraction (10X magnification).





**Figure 3a:** Comparison of the number of osteoclasts in the test group (T-oc) during the 4 weeks. **b:** Comparison of the number of osteoclasts in the control group (C-oc) during the 4 weeks.

eogenesis and decreasing bone resorption by preventing the differentiation of osteoclasts through RANK-RANKL system. [7, 19] Since beta-blockers are widely used for treatment of cardiovascular diseases, [13] epidemiologic studies in this respect are feasible. Studies have demonstrated that use of beta-blockers has been associated with lower risk of fractures. Considering the association of sympathetic nervous system with bone metabolism, medical researchers have seriously focused on the application of beta-blockers for prevention and treatment of osteoporosis. [9-18]

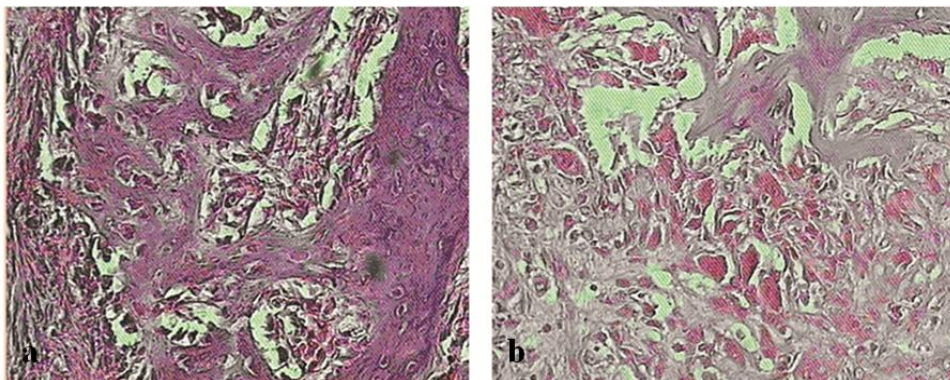
In dentistry, the relationship between beta-blockers and bone loss has been the focus of attention for some time now. Kim *et al.* [20] induced alveolar bone loss by superior cervical ganglionectomy and oral challenge with *P. gingivalis*.

We found that the number of osteoclasts in the control group was significantly higher than the test group receiving propranolol which our results are in agreement of Okada *et al.* [21] study. They assessed the effects of a beta-blocker on alveolar bone loss induced by *P. gingivalis* infection in rats to examine the involvement of sympathetic nervous system in perio-

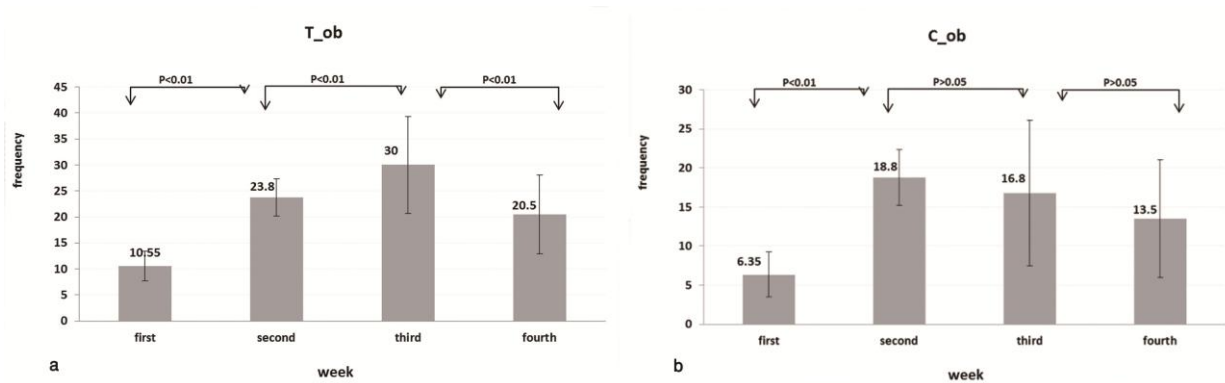
dontal breakdown and indicated that beta-blockers inhibited osteoclast differentiation and prevented alveolar bone loss by controlling the alveolar bone mass metabolism. Shimizu *et al.* [22] also demonstrated that sympathetic nervous activity can affect bone loss induced by occlusal hypo-function in rats.

Decreased number of osteoclasts following beta-blocker administration that has been reported by other researchers as well [20-21] is indicative of the role of sympathetic nervous system in regulating bone mass and confirms the hypothesis of beta-blocker use for prevention of alveolar bone resorption following tooth extraction.

The number of osteoblasts reached its maximum rate in week 2 in the control and in week 3 in the propranolol group and showed a significant increase in the test group compared to the control group. Number of osteoblasts decreased afterwards and osteoclasts reappeared. The above mentioned findings are in accord with animal model studies on extraction socket healing in rats indicating that osteogenesis initiated in the middle of the 2<sup>nd</sup> week post-extraction and slowed down at the end of the 3<sup>rd</sup> week when the tooth socket is mostly



**Figure 4a:** Accumulation of osteoclasts in the socket in the control group. **b:** Accumulation of osteoblasts in the socket in the test group at week 3 post-extraction (40X magnification).



**Figure 5a:** Comparison of the number of osteoblasts in the test group (T-ob) during the 4 weeks. **b:** Comparison of the number of osteoblasts in the control group (C-ob) during the 4 weeks.

filled with newly formed bone. [23-24] However, in rats receiving propranolol although the number of osteoblasts at week 2 increased similar to the control group, in contrast to the controls, this increase continued until week 3 and number of osteoblasts revealed a significant difference with that of the controls (Figure 4). In fact, duration of osteogenesis phase in the propranolol group was longer than that in the control group which is in agreement with other studies reporting increased osteogenesis in rats receiving propranolol. [7-19] Our results clearly demonstrate the difference in trabecular number and thickness and also the width of bone marrow space in the bone covering alveolar socket floor in test and control rats.

The present study results need to be confirmed by further laboratory and clinical studies. Investigation of bone density in the repaired socket is suggested for further studies. However, considering our obtained results, a hypothesis can be proposed regarding the prevention of alveolar bone resorption following tooth extraction by using beta-blockers.

**Conclusion**

In a conclusion,  $\beta_2$  adrenergic receptor antagonists decrease the number of osteoclasts and increase the number of osteoblasts during extraction socket healing.

**Acknowledgement**

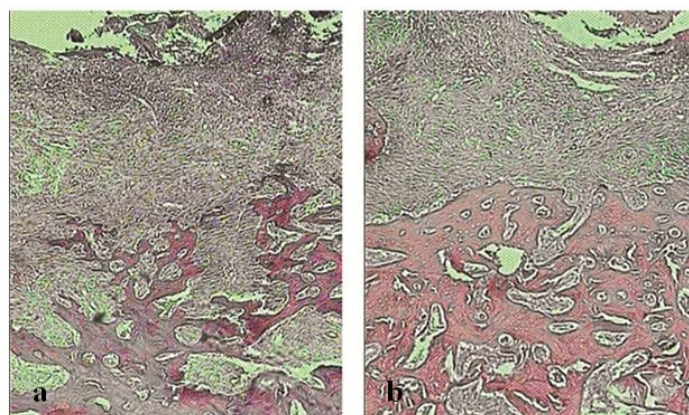
This study was supported by a grant from faculty of Dentistry of Tabriz University of Medical Science.

**Conflict of Interest**

Authors declare no conflict of interest.

**References**

- [1] Chen ST, Wilson TG Jr, Hämmerle CH. Immediate or early placement of implants following tooth extraction: review of biologic basis, clinical procedures, and outcomes. *Int J Oral Maxillofac Implants.* 2004; 19 Suppl: 12-25.
- [2] Jahangiri L, Devlin H, Ting K, Nishimura I. Current perspectives in residual ridge remodeling and its clinical implications: a review. *J Prosthet Dent.* 1998; 80: 224-237.
- [3] Zarb GA, Hobkirk JA, Eckert SE, Jacob RF. Prosthodontics treatment for edentulous patients: complete



**Figure 6a:** New bone formation in tooth socket in the control group. **b:** New bone formation in tooth socket in the test group at week 4 following the tooth extraction (10X magnification).

- dentures and implant- supported prostheses. 13th ed. St Louis: Mosby, 2013. p. 49.
- [4] Elefteriou F, Ahn JD, Takeda S, Starbuck M, Yang X, Liu X, et al. Leptin regulation of bone resorption by the sympathetic nervous system and CART. *Nature*. 2005; 434: 514-520.
- [5] Chenu C. Role of innervation in the control of bone remodeling. *J Musculoskelet Neuronal Interact*. 2004; 4: 132-134.
- [6] Ducy P, Amling M, Takeda S, Priemel M, Schilling AF, Beil FT, et al. Leptin inhibits bone formation through a hypothalamic relay: a central control of bone mass. *Cell*. 2000; 100: 197-207.
- [7] Takeda S, Elefteriou F, Levasseur R, Liu X, Zhao L, Parker KL, et al. Leptin regulates bone formation via the sympathetic nervous system. *Cell*. 2002; 111: 305-317.
- [8] Patel MS, Elefteriou F. The new field of neuroskeletal biology. *Calcif Tissue Int*. 2007; 80: 337-347.
- [9] Schlienger RG, Kraenzlin ME, Jick SS, Meier CR. Use of beta-blockers and risk of fractures. *JAMA*. 2004; 292: 1326-1332.
- [10] Pasco JA, Henry MJ, Nicholson GC, Schneider HG, Kotowicz MA. Beta-blockers reduce bone resorption marker in early postmenopausal women. *Ann Hum Biol*. 2005; 32: 738-745.
- [11] Turker S, Karatosun V, Gunal I. Beta-blockers increase bone mineral density. *Clin Orthop Relat Res*. 2006; 443: 73-74.
- [12] Rejnmark L, Vestergaard P, Mosekilde L. Treatment with beta-blockers, ACE inhibitors, and calcium-channel blockers is associated with a reduced fracture risk: a nationwide case-control study. *J Hypertens*. 2006; 24: 581-589.
- [13] Wiens M, Etminan M, Gill SS, Takkouche B. Effects of antihypertensive drug treatments on fracture outcomes: a meta-analysis of observational studies. *J Intern Med*. 2006; 260: 350-362.
- [14] de Vries F, Souverein PC, Cooper C, Leufkens HG, van Staa TP. Use of beta-blockers and the risk of hip/femur fracture in the United Kingdom and The Netherlands. *Calcif Tissue Int*. 2007; 80: 69-75.
- [15] de Vries F, Pouwels S, Bracke M, Leufkens HG, Cooper C, Lammers JW, et al. Use of beta-2 agonists and risk of hip/femur fracture: a population-based case-control study. *Pharmacoepidemiol Drug Saf*. 2007; 16: 612-619.
- [16] Meisinger C, Heier M, Lang O, Döring A. Beta-blocker use and risk of fractures in men and women from the general population: the MONICA/KORA Augsburg cohort study. *Osteoporos Int*. 2007; 18: 1189-1195.
- [17] Bonnet N, Gadois C, McCloskey E, Lemineur G, Lespessailles E, Courteix D, et al. Protective effect of beta blockers in postmenopausal women: influence on fractures, bone density, micro and macroarchitecture. *Bone*. 2007; 40: 1209-1216.
- [18] Sosa M, Saavedra P, Gómez de Tejada MJ, Mosquera J, Pérez-Cano R, Olmos JM, et al. Beta-blocker use is associated with fragility fractures in postmenopausal women with coronary heart disease. *Aging Clin Exp Res*. 2011; 23: 112-117.
- [19] Bonnet N, Benhamou CL, Malaval L, Goncalves C, Vico L, Eder V, et al. Low dose beta-blocker prevents ovariectomy-induced bone loss in rats without affecting heart functions. *J Cell Physiol*. 2008; 217: 819-827.
- [20] Kim Y, Hamada N, Takahashi Y, Sasaguri K, Tsukinoki K, Onozuka M, et al. Cervical sympathectomy causes alveolar bone loss in an experimental rat model. *J Periodontol Res*. 2009; 44: 695-703.
- [21] Okada Y, Hamada N, Kim Y, Takahashi Y, Sasaguri K, Ozono S, et al. Blockade of sympathetic b-receptors inhibits Porphyromonas gingivalis-induced alveolar bone loss in an experimental rat periodontitis model. *Arch Oral Biol*. 2010; 55: 502-508.
- [22] Shimizu Y, Hosomichi J, Kaneko S, Shibutani N, Ono T. Effect of sympathetic nervous activity on alveolar bone loss induced by occlusal hypofunction in rats. *Arch Oral Biol*. 2011; 56: 1404-1411.
- [23] Cintra PA, Castro AL, Castro JC, Melhado RM. Histological survey of the healing process on tooth extraction wounds in rats after hypothalamic median eminence lesion. *Rev odontol. UNESP*. 1982; 11: 81-89.
- [24] Pietrokovski J, Massler M. Ridge remodeling after tooth extraction in rats. *J Dent Res*. 1967; 46: 222-231.