

Chronic Mucocutaneous Candidiasis Associated with Osteogenesis Imperfecta: A Case Report

Pakfetrat A.^a, Sanatkhani M.^a, Bidram F.^{a*}, Baghaee B.^b

^aDept. of Oral Medicine, School of Dentistry, Dental Research Center, Mashhad University of Medical Science, Mashhad, Iran

^bDept. of Pediatrics, School of Dentistry, Dental Research Center, Mashhad University of Medical Science, Mashhad, Iran

KEY WORDS

Candidiasis;
Osteogenesis Imperfecta.

Received Nov. 2008;
Received in revised form Jan. 2008;
Accepted Nov. 2008

ABSTRACT

A male patient aged 6.5 years (patient No.1) is reported with chief complaint of white lesions in his mouth from birth, which was finally diagnosed as chronic mucocutaneous candidiasis (CMC). Clinical, radiographical and histopathological examinations revealed dentinogenesis imperfecta associated with osteogenesis imperfecta in both the patient and his sister (patient No.2). The importance of early diagnosis and treatment of both diseases is discussed in this report.

* **Corresponding author.** Bidram F., Address: Dept. of Oral Medicine, School of Dentistry, Dental Research Center, Mashhad University of Medical Science, Mashhad, Iran; Tel: 0511-8829501; fax: 0511-8829500; E-mail: farnazbidram@yahoo.com

Introduction

Chronic mucocutaneous candidiasis (CMC) is a term used to describe a heterogeneous group of clinical syndromes characterized by chronic, treatment resistant, superficial candidiasis infection of the skin, nails and oropharynx. The oral lesions appear, followed by perleche, lip fissures, nail and cutaneous involvement. When presenting in childhood, the lesions are detected before the age of 3 years [1, 2].

There are many conditions associated with CMC, which should be considered and referred for proper treatment. The dentist's early diagnosis of CMC is of great importance as prompt treatment of CMC can prevent the spread of candida and oral severe lesions [3, 4].

We have studied a case who suffered from CMC for several years and another untreated hereditary disorder, osteogenesis imperfecta (OI) type IV, whose dental sign, dentinogenesis imperfecta (DI), was ignored while it should have been considered.

According to Shields *et al.*'s classification, DI that occurs with OI is type II, resulting from a variety of mutations in collagen type I gene [4, 5]. Although in comparison to normal teeth, the teeth of DI cases deteriorate more easily and excessively, they do not appear to be more susceptible to dental caries than

the normal teeth [6]. Patients with OI and DI should be examined as soon as their deciduous teeth erupt. Immediate dental involvement and oral hygiene instruction can reduce the necessity of extensive dental treatment.

The purpose of this report is to present a patient who was referred to the Oral Medicine Department for his white lesions in oral mucosa diagnosed as CMC (patient No1). Through clinical features and histopathologic analysis, the association of DI with his osteogenesis imperfecta, diagnosed earlier in patient No1 and his sister (patient No2), was detected.

Case Report

An Iranian 6.5-year-old boy (patient No.1) referred to the Oral Medicine Department of Mashhad Dental School with the chief complaint of diffused white plaques on his oral mucosa for the past six years. (Fig. 1-a, 1-b) He also had a past history of recurrent bone fracture. His sibling (patient No.2), who was 3.5 years old, also presented with similar skeletal recurrent fractures. Both of them have been under professional care for the past three years. Diagnosis was osteogenesis imperfecta. Hand examination showed nail dystrophy on almost all the fingers of the

patient No.1. (Fig 1-c). Family history revealed that their parents were relatives, but neither of them had a history of any dental and skeletal abnormality. Intraoral examination revealed removable white plaques diffused all over the oral mucosa of patient No.1. The removal of the plaques by gentle rubbing

revealed an area of erythema. In the clinical examination, both patients' teeth showed grayish discoloration without normal translucency, while panoramic and periapical radiographs revealed obliteration canals and pulp chambers, short root, and pulp stone in some of their teeth. (Figs. 1-d, 2-a, 2-b, 3-a)

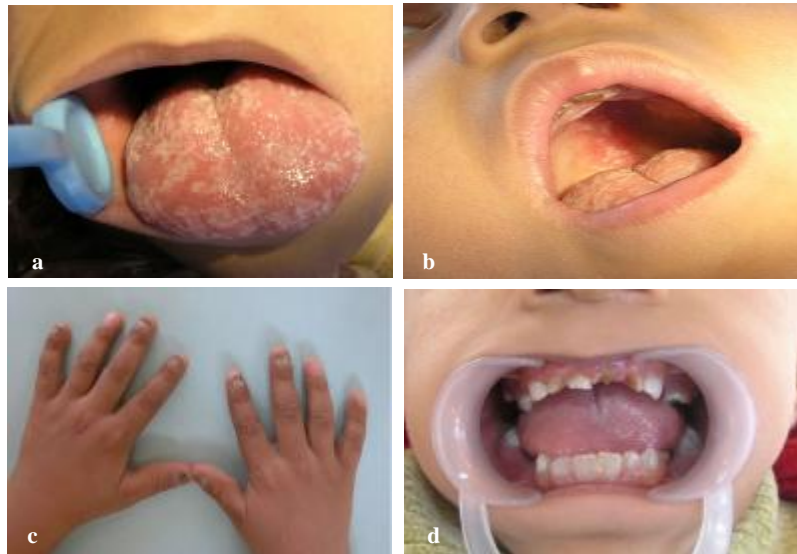


Figure 1 Patient's signs, a: White plaque like lesions on the tongue, b: White plaque like lesions on the palate, c: Nail dystrophy d: The patient's dentition (note the color of the teeth)

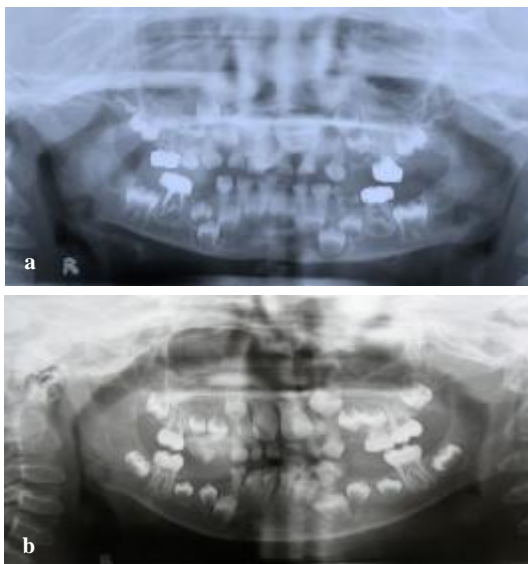


Figure 2 Panoramic radiography image, a: The patient's, b: His sibling's

Our clinical and radiographical diagnosis led to the suspicion of DI, which was confirmed by a histopathological examination. With regard to the

presence of recurrent removable white plaques in patient No.1's oral cavity and nails dystrophy in the form of thickened, brittle and discolored nails with an erythematous, swollen and tender paronychia area, he was diagnosed with "chronic mucocutaneous candidiasis" (CMC). The direct smear from the nail and mouth, in which spore and hyphae were seen, confirmed our diagnosis of CMC. Then, with the exception of CMC involvement, both patients (No.1 and 2) were in a similar condition of OI and DI. Once in approximately the past 3 years, patient No. 1's nail lesions were diagnosed as a fungal infection; however, he did not receive any suitable antifungal treatment. The results of a full blood count as well as liver and kidney function tests were normal. The endocrinologist did not find endocrinopathy or any associated conditions with CMC in these patients. A systemic antifungal drug (Fluconazol) was used to treat the oral lesions, using the primary dosage of 50mg/day. After a week, complete remission of the oral lesions was clearly observed (Figs 4-a, 4-b).

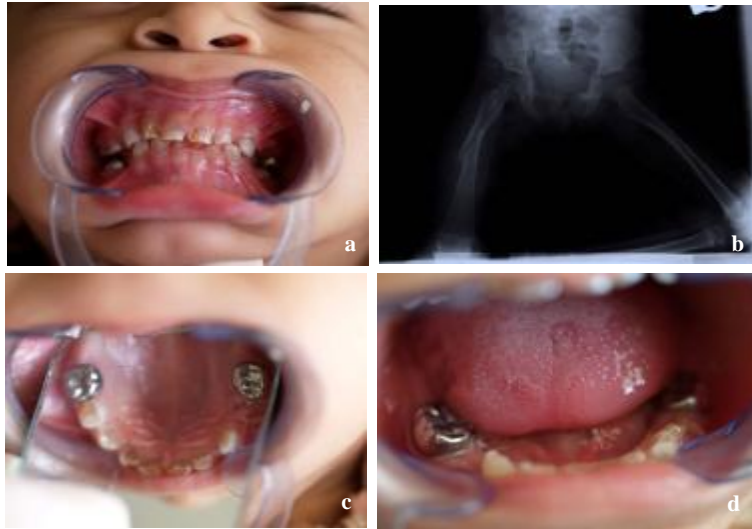

Figure 3 His sibling's sign and treatment a: Dentition (note the color of the teeth), b: X-ray of the sibling's legs (note the fracture in her leg), c: SS Crown on his sibling's posterior upper teeth, d: SSC on his sibling's posterior lower teeth

We also observed healing of nail dystrophy in our weekly visit, and after dermatologist's consultation, to achieve complete remission of nail lesions, it was decided to use pulse therapy (100mg/week of fluconazole) as maintenance therapy for up to 9 months (Fig 4-c). In addition, both siblings were referred to the Pedodontic Department for professional prophylactic care (Figs 4-d, 4-e, 3-c, 3-d). Their six month follow up showed no recurrence of oral

and nail lesions in patient No.1; however, the patients were requested to have monthly check up.

Discussion

An interesting feature in this case was the appearance of CMC with dentino and osteogenesis imperfecta in the two siblings, which has never been reported together so far.

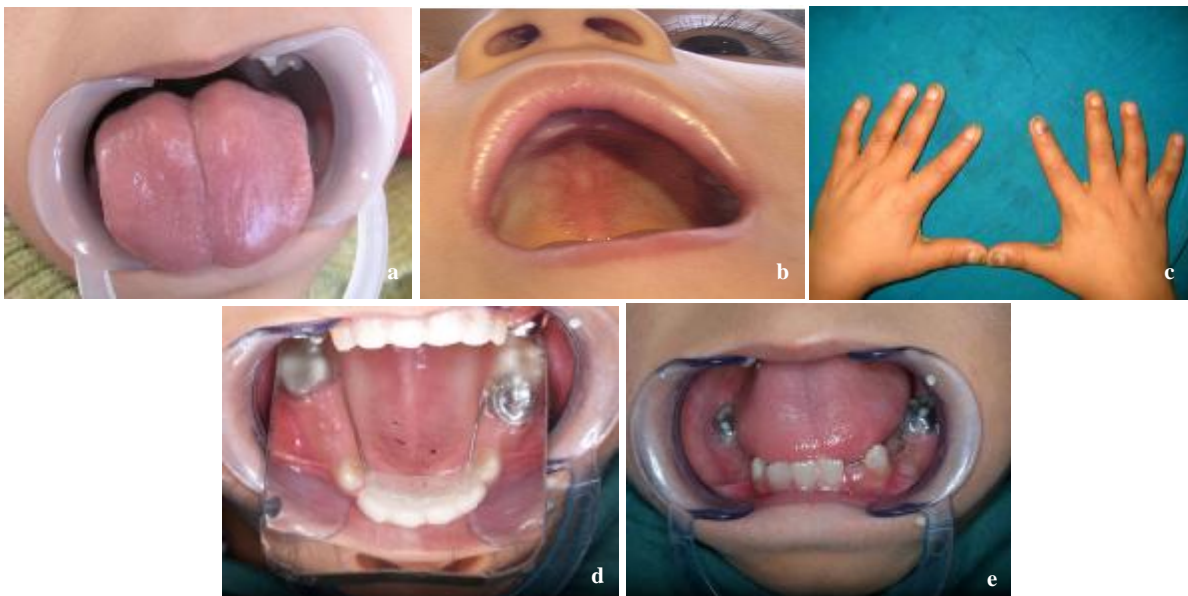


Fig 4 The patient's treatment a: Tongue a week after taking Fluconazol, b: Palate a week after taking Fluconazol, c: Nails' healing one week later, d: Upper fixed space maintainer in the patient's mouth, e: SS Crown on posterior the patient's teeth

The main purpose was to report a case in whom both CMC and OI occurred together (patient No.1); however, these two rare diseases are of different distinct etiopathogenesis that has not been reported in a single syndrome till now. The emphasis of the present report is on early diagnosis of oral manifestations in the mentioned diseases. Dentists should recognize CMC as a T lymphocyte disorder of childhood, in which oral mucosa is the most frequent site of mucosal alteration [2]. Many patients have candidiasis endocrinopathy syndrome (CES) or severe conditions such as active hepatitis, diabetes, vitiligo, iron deficiency, and pernicious anemia, requiring immediate evaluation. Moreover, dentists may be the first health care professional that are referred to for treatment.

Although candidiasis could appear in the form of white plaque, erythema and pseudomembrane, all of which may be very similar to symptoms of other diagnosis of common white lesions in children, as listed in Table 1, chronic behavior, distribution, and association with nail abnormalities as well as its onset in early childhood in our patient led us to the diagnosis of CMC.

Table 1 Common oral white lesions in children^[7]

1.	Frictional keratosis
2.	Leukoedema
3.	Contact stomatitis
4.	Linea alba
5.	Genodermatosis (especially White Sponge Nevus)
6.	CMC
7.	Burn
8.	Coated tongue
9.	Scar formation
10.	Fordyce granule
11.	Epstein pearl

Systemic antifungal therapy is needed to treat oral thrush and nail dystrophy, to control the spread of candida, and to prevent nail deformity as well as oral severe lesions. But dentists should prescribe the antifungal drugs with caution, taking their side effects into consideration [2, 6].

In both of the patients, although conservative treatment began years ago to control osteogenesis imperfecta, DI had been left untreated and their parents were unaware of dental abnormalities. Early

diagnosis and treatment of DI is also essential as it leads to the rehabilitation of the stomatognathic imperfect, DI had been left untreated and their parents were unaware of dental abnormalities.

Early diagnosis and treatment of DI is also essential as it leads to the rehabilitation of the stomatognathic system and helps children regain their lost confidence. Therefore, dentists should be capable of correct diagnosis and knowledgeable enough to treat DI [8].

Conclusion

This report emphasizes the importance of dentists' early diagnosis of mucosal lesions and dental abnormalities especially in children to achieve the best treatment plan and prognosis.

Acknowledgment

Mashhad University of Medical Sciences has financially supported this work. The author would like to thank the vice chancellor for research of Mashhad University of Medical Sciences.

References

- [1] Burn T, Stephen N, Cox N, Griffiths Ch. Rook's. Text book of dermatology. 7th ed. Massachusetts: Black well Inc; 2004. p. 70-72.
- [2] Fitzpatrick's S. Dermatology in General Medicine. 5th ed. New York: Mc Grpw-Hill; 2003. p.1401-1402.
- [3] Greenberg MS, Glick M. Burket's Oral Medicine. 10th ed. New York: BC Decker Inc; 2008: p.82.
- [4] Neville BW, Damm DD. Oral and maxillofacial. 1th ed. WB Saunders Com: USA; 2002. p.190-194, p. 106-8 .
- [5] Pettiette MT, Wright JT, Trope M. Dentinogenesis imperfecta: endodontic implications. Case report. Oral Surg Oral Med Oral Pathol Oral Radiol Endod 1998; 86: 733-737.
- [6] Engelbert RH, Pruijs HE, Beemer FA, Helden PJ. Osteogenesis imperfecta in childhood: treatment strategies. Arch Phys Med Rehabil 1998; 79: 1590-1594.
- [7] Pinkham JR. Pediatric dentistry. 3rd ed. Philadelphia: Mosby; 2000. p. 15-18.
- [8] Singh M, Singh S. Hereditary opalescent dentin--a case report. J Indian Soc Pedod Prev Dent 2004; 22: 144-147.