

**Original Article****Diagnostic Efficacy of Deeper Sections in Routine Oral Histopathology Practice: a Retrospective Study**Achla Bharti Yadav<sup>1</sup>, Mala Kamboj<sup>1</sup>, Anjali Narwal<sup>1</sup>, Anju Devi<sup>1</sup><sup>1</sup> Dept. of Oral Pathology & Microbiology, Post Graduate Institute of Dental Sciences, Rohtak, Haryana, India.**KEY WORDS**Diagnosis;  
Histopathology;  
Retrospective study;Received December 2016;  
Received in Revised form June 2017;  
Accepted July 2017;**ABSTRACT****Statement of the Problem:** Histopathology is a gold standard diagnostic tool for oral lesions. Nonspecific and overlapping microscopic features often pose diagnostic challenges in routine practice. In such conditions, deeper sections have utility to enhance the sensitivity and accuracy of the diagnosis.**Purpose:** To analyze the percentage of deeper sections requested and to evaluate the diagnostic efficacy of these deeper sections in routine oral histopathology practice. Additionally, the utility of deeper sections in specific oral lesions have also been evaluated.**Materials and Method:** A total of 850 cases from the archives of Department of Oral Pathology and Microbiology, were analyzed, and 106 cases with deeper sections were selected. Out of 106, 82 cases were accepted for our analysis and 24 were rejected as deeper sections were done due to staining errors or folding of tissue. The present retrospective study involves comparison of initial histological findings with those seen in deeper sections of same specimen.**Results:** Deeper sections improved the diagnosis of 48 cases (58.54%). Remaining 31 cases (38%) showed the same histological features, whereas in 3 cases (3.66%), initial sections were good as compared to deeper sections. Out of 22 cases of provisional hyperkeratotic/ dysplastic lesion, 16 (72.72%) showed change in diagnosis, i.e. from mild to severe dysplasia or from dysplasia to carcinoma. A total 12 out of 17 (70.59%) cases of odontogenic lesions were non- diagnostic or showed minimal characteristic features on initial sections, but their deeper sections revealed clearly identifiable features and some of them also showed cystic lesion turning into tumor pathology.**Conclusion:** This study highlights the diagnostic efficacy of deeper sections and their contribution towards providing accurate and more descriptive features.**Corresponding Author:** Achla Bharti Yadav. Demonstrator, Department of Oral Pathology & Microbiology, Post Graduate Institute of Dental Sciences, Rohtak, Haryana, India. Tel: +8570984309  
Email: drachlabharti@gmail.comCite this article as: Yadav AB, Kamboj M., Narwal A., Devi A. Diagnostic Efficacy of Deeper Sections in Routine Oral Histopathology Practice: a Retrospective Study. *J Dent Shiraz Univ Med Sci.*, 2018 March; 19(1): 63-67.**Introduction**

Histopathology is a gold standard diagnostic tool for pathologies involving the oral cavity. The received biopsies go through processes like grossing, embedding, sectioning, and staining before the tissue architecture depicts the diagnosis. Sometimes, the pathologist demands for sections at different levels to arrive at final diagnosis and such situations necessitate the need for

deeper sectioning. [1-2]

Non- specific and overlapping microscopic features often pose diagnostic challenges in routine histopathology practice. [3] Historically, retrospective step sections are prescribed where deeper levels are obtained, at the request of the oral pathologist, after the original slides have been reviewed. Currently, few laboratories promote prospective step sections, where step

sections are prepared prior to receipt of the slides by the oral pathologist. [2] Deeper levels provide increased diagnostic accuracy in about one third of skin biopsies and they are more helpful in diagnosis of skin cancer. [4-7] But studies pertaining to the importance of deeper sections in relation to routine oral histopathology practice are sparse. Thus, the present retrospective study was undertaken to appreciate the percentage of deeper sections requested and to evaluate the diagnostic efficacy of these deeper sections in routine oral histopathology practice. Additionally, the utility of deeper sections in specific oral lesions have been evaluated.

### Materials and Method

A total of 850 cases from the archives of Department of Oral Pathology and Microbiology were retrieved and reviewed, and 106 cases that were reported with deeper sections were selected. Out of 106, 82 cases were accepted for our analysis and 24 were rejected as deeper sections were done due to staining errors or tissue folding. Initial slide was labeled as 1 and deeper section was labeled as 2, and subjected for re-evaluation by the two independent reporting oral pathologists. This retrospective study involved noting of each valuable histopathological feature and comparison of initial reported microscopic findings with those seen in deeper tissue levels of same specimen. Any other additional findings and hidden malignancies in deeper sections were also noted.

### Results

The 82 cases included in our study for which retrospective step sections were done are summarized in Table 1. Diagnosis was revised in 42 cases (51.22%); additional diagnostic findings were present in six cases (7.32%).

In total, deeper sections improved the diagnosis of 48 cases (58.54%). Remaining 31 (38%) cases showed the same histological features, whereas in three cases (3.66%) initial sections were good as compared to deeper sections (Table 2).

Out of 22 cases of provisional hyperkeratotic/dysplastic lesion, 16 (72.72%) showed change in diagnosis, i.e. from mild to severe dysplasia or from dysplasia to carcinoma (Figure 1). One case (4.55%) showed additional diagnostic finding, whereas remaining five (22.73%) cases depicted the same diagnosis (Table 3).

**Table 1:** Cases included in the study

S. No.	Cases	Numbers (Total 82)
1.	Squamous cell carcinoma	12
2.	Early invasive squamous cell carcinoma	01
3.	Verrucous carcinoma	03
4.	Carcinoma in situ	02
5.	Dysplasia	04
6.	Hyperkeratosis	02
7.	Hyperplastic epithelium/ gingival hyperplasia	02
8.	Lichen planus	01
9.	Oral submucous fibrosis (OSMF)	01
10.	Oral myiasis	01
11.	Dentigerous cyst	03
12.	Keratocystic odontogenic tumor/ OKC	02
13.	Inflammatory /radicular/ residual cyst	04
14.	Calcifying odontogenic cyst with cholesterol granuloma	01
15.	Developmental cyst with heterotopic gastric epithelium	01
16.	Dermoid cyst	01
17.	Unicystic ameloblastoma	03
18.	Calcifying epithelial odontogenic tumor (CEOT)	01
19.	Adenomatoid odontogenic tumor (AOT)	01
20.	Pleomorphic adenoma	02
21.	Adenoid cystic carcinoma	01
22.	Attempt of giant cell (multinucleated) formation	01
23.	Central giant cell granuloma (CGCG)	01
24.	Ossifying fibroma (central/ peripheral)	03
25.	Chronic necrotizing osteomyelitis	01
26.	Granulomatous inflammation	01
27.	Inflammatory lesion	10
28.	Pyogenic granuloma	02
29.	Fibro epithelial hyperplasia	01
30.	Fibrous hyperplasia	01
31.	Fibrous hyperplasia with ossification	01
32.	Fibrous dysplasia	01
33.	Melanin incontinence	01
34.	Hypertrophied muscle with hyperplasia of collagen bundles	01
35.	Condylar hyperplasia (endochondral ossification)	01
36.	Malignancy (epithelial/ connective tissue)	02
37.	Myxofibroma	01
38.	Neurilemmoma	02
39.	Arterio- venous malformation	01
40.	Cysticercosis	01

**Table 2:** Percentage of cases with change and without change of diagnosis

Cases (Total=82)	Number	Percentage
With change in diagnosis	42/82	51.22%
With same diagnosis but additional findings	6/82	7.32%
Total (where deep cut provides exact diagnosis)	48/82	58.54%
With no change in diagnosis	31/82	37.80%
With first cut was better than deeper	3/82	3.66%
Total (where first cut was sufficient for diagnosis)	34/82	41.46%

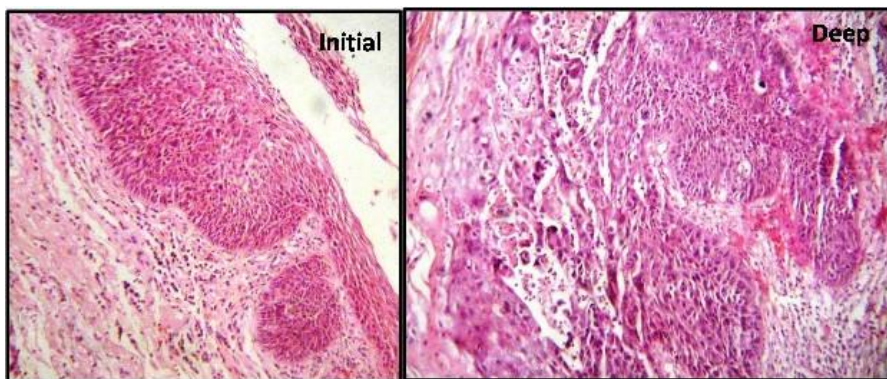


Figure 1: Initial versus deeper section of Squamous cell carcinoma

Table 3: Percentage of dysplastic and carcinoma cases with change and without change of diagnosis

Cases (Total=22) (SCC, Early invasive carcinoma, Carcinoma in situ, Verrucous carcinoma, Dysplasia)	Number	Percentage
With change in diagnosis	16/22	72.72%
With same diagnosis but additional findings	01/22	4.55%
Total (where deep cut provides exact diagnosis)	17/22	77.27%
With no change in diagnosis	05/22	22.73%
With first cut was better than deeper	00	00
Total (where first cut was sufficient for diagnosis)	05/22	22.73%

Table 4: Percentage of cyst and tumors with change and without change of diagnosis

Cases (Total=17) (Developmental & Odontogenic cyst, Odontogenic tumors)	Number	Percentage
With change in diagnosis	12/17	70.59%
With same diagnosis but additional findings	00	00
Total (where deep cut provides exact diagnosis)	12/17	70.59%
With no change in diagnosis	04/17	23.53%
With first cut was better than deeper	01/17	5.88%
Total (where first cut was sufficient for diagnosis)	05/17	29.42%

Twelve (70.59%) out of 17 cases of odontogenic lesions were unidentified or showed minimal characteristic features on initial sections, whereas deeper sections revealed clearly identifiable features with few showing cystic lesion turning into tumor pathology (Figure 2 & 3). Remaining five (29.42%) cases illustrated the same diagnosis as initial (Table 4).

**Discussion**

Routine biopsy reports may be ready at the earliest within 2-3 days after the sample is received in the laboratory. Surgeons eagerly wait for the histopathology report as any delay in diagnosis will have a direct impact on treatment plan and further on the patient care. [1-2]

False negative diagnosis in pathology is most common consequence of sampling error caused by incomplete sectioning through the tissue block. [6] No standardized approach for sectioning of oral biopsy specimens has been discovered so far. There are differences of opinion about the deeper sectioning methods to obtain optimal diagnostic information. As histopathologic assessment is subject to sampling error, many institutions and laboratories 'preorder' deeper sections for

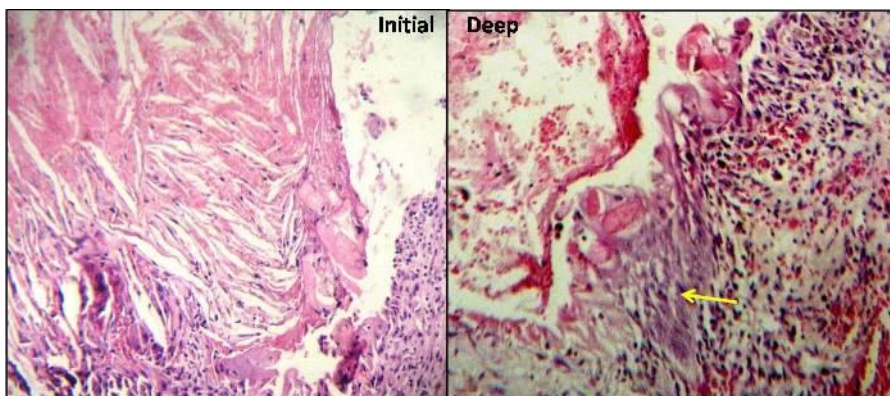
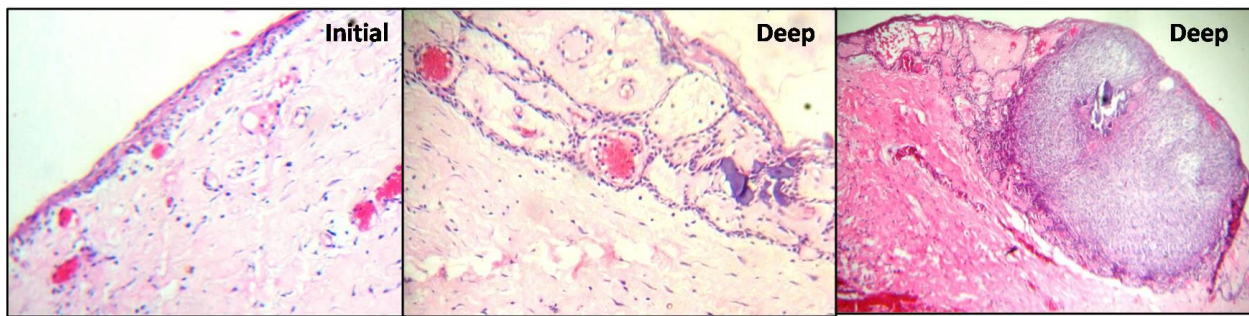

Figure 2: Initial versus deeper section of calcifying odontogenic cyst



**Figure 3:** Initial section depicting dentigerous cyst versus deeper section representing Adenomatoid odontogenic tumor

selected cases (referred to as prospective deeper sections), while others request additional deeper sections if the pathologist is unable to diagnose from the initial section (referred to as retrospective deeper sections). [8] Though this practice provides enough evidence for better diagnosis for oral biopsies, but preparing and examining more sections can increase cost and cause delay in dispatching of report (particularly in case of retrospective deeper sections). Therefore, the question that comes to mind of every oral pathologist is what should be the standard protocol for prospective deeper sections so that the time and money could be saved with diagnosis that is more appropriate?

During reviewing the literature, we have come across many studies regarding utility of deeper sections in dermatopathology. A study on deeper sections for skin histopathology revealed their use in assessing the presence or absence of cutaneous malignancy rather than redefining the diagnosis. [4] Another practice on examining additional levels of skin biopsies that received an initial diagnosis of actinic keratosis resulted in new diagnosis in 33% of cases and more importantly, among which 50% of cases were found to be malignant. [5] One more research on the utility of taking additional deeper sections for dermatopathology found modified diagnosis in 9% of cases, which changed clinical management in 56% of these cases. [8] Bruecks *et al.* [6] proved utility of prospective step sections in improving diagnostic accuracy and turnaround time for small skin biopsies, with minimal cost increase.

Even in colorectal biopsies, deeper sections are routinely in use. One study looked at colorectal biopsies found that additional step-sections were more likely to yield diagnostic abnormality which was not revealed on initial sections. However, there was a statistically non-significant trend for specimens with a clinical diagnosis

of polyp to display tubular adenoma in the deeper sections. [9]

Two studies have been done so far related to oral biopsies where the authors Manyam *et al.* [1] and Patil *et al.* [2] concluded that the deeper sections improved diagnostic accuracy from 37-58% respectively. Similarly, in the present study, deeper sections were requested in 12.5% of total cases, out of which 77% cases were selected for the study purpose and others were discarded as multiple sections were done due to folding of tissues or staining error. A total of 42 (51%) cases manifested non-diagnostic representation or misled the diagnosis on initial cut and further on requisition for deeper section change in diagnosis was made. Incidentally, six (7%) of the enlisted cases also revealed additional features although initial sections were diagnostic and in remaining 34 (41%) cases initial sections were diagnostic enough.

Interestingly, few cases of verrucous carcinoma showed cross sections of epithelium embedded in connective tissue with or without keratin on initial sections, but on deeper one, clear keratin plugging within epithelium showing minimal dysplasia was identifiable. Even for squamous cell carcinoma cases, initial picture of cross sectional cut epithelium or dysplastic islands in the stroma without superficial epithelium was seen, but in deeper sections, superficial epithelium with break and dysplastic islands in the stroma were clearly visible. Few cases with pseudo-epitheliomatous hyperplasia on initial diagnosis came out to be dysplastic lesion on the deeper section analysis.

One case of unicystic ameloblastoma showed no cystic lining on initial section but the proliferative cystic lining with stellate reticulum and odontogenic islands in stroma were visible on deeper section. Similarly, 2-3 layered cystic lining giving an impression of dentiger-

ous cyst, on deeper section suggested a diagnosis of adenomatoid odontogenic tumor with proliferating cystic lining forming rosette/ ductal pattern with calcifications. Proliferating cystic lining with surrounding inflamed stroma suggested the diagnosis of inflammatory cyst initially, but on subsequent sectioning 6-8 layered lining, basal columnar and superficial keratin along with area of proliferating cystic lining and surrounding inflamed stroma was seen projecting a picture of inflamed odontogenic keratocyst. Even many ossifying fibroma cases with cellular stroma and focal osteoid formation, on deeper analysis produced increase in osteoid and mature bone formation.

Thus, the present study suggests the usage of prospective deeper sections for odontogenic lesions as biopsies originally diagnosed as non-specific cyst, yielded new diagnostic information such as additional representative cystic lining/ tumor pathology or odontogenic islands/ calcifications in deeper sections. Even in epithelial dysplastic lesions, deeper sections revealed hidden malignancies that completely changed the treatment plan.

### Conclusion

The present paper highlights the relevance of deeper sections not only to improve the diagnostic accuracy but also for the wellbeing of patients. Therefore, we recommend the utility of prospective deeper sections particularly for odontogenic and epithelial dysplastic lesions where the hidden malignancies affirm the potential benefits of deep section analysis.

### Conflict of Interest

None Declared.

### References

- [1] Manyam R, Reena K, Saraswathi TR. Role of deeper sections in diagnostic oral histopathology: a retrospective study. *Indian J Dent Res.* 2011; 22: 62-65.
- [2] Patil S, Rao R, Nagaraja A. Deep Sections, a Guiding Path for Accurate Diagnosis in Histopathology - A Retrospective Study. *Journal of Advanced Oral Research.* 2013; 4: 15-20.
- [3] Sangeetha RS, Hemalatha AN, Manjunatha YA. Step Section Analysis in Routine Dermatopathology practiceA study. *IOSR Journal of Dental and Medical Sciences (IOSR-JDMS).* 2013; 4: 41-47.
- [4] Maingi CP, Helm KF. Utility of deeper sections and special stains for dermatopathology specimens. *J Cutan Pathol.* 1998; 25: 171-175.
- [5] Carag HR, Prieto VG, Yballe LS, Shea CR. Utility of step sections: demonstration of additional pathological findings in biopsy samples initially diagnosed as actinickeratosis. *Arch Dermatol.* 2000; 136: 471-475.
- [6] Bruecks AK, Shupe JM, Trotter MJ. Prospective step sections for small skin biopsies. *Arch Pathol Lab Med.* 2007; 131: 107-111.
- [7] Kattel G, Sinha AK, Agrawal S. Utility of prospective step sections in diagnostic skin histopathology for small biopsies. *J Pathol Nepal.* 2014; 4: 552-559.
- [8] Stuart LN, Rodriguez AS, Gardner JM, Foster TE, MacKelfresh J, Parker DC, et al. Utility of additional tissue sections in dermatopathology: diagnostic, clinical and financial implications. *J Cutan Pathol.* 2014; 41: 81-87.
- [9] Parameswaran L, Prihoda TJ, Sharkey FE. Diagnostic efficacy of additional step-sections in colorectal biopsies originally diagnosed as normal. *Hum Pathol.* 2008; 39: 579-583.