

Original Article

Surgical Repair of Nasal Septal Perforation by Mucosal Rotational Flap and Interposition of Cryopreserved Amniotic Membrane

Farrokh Farhadi Shabestari¹, DMD; Reza Khorshidi Khiavi¹, DMD; Mohsen Hashemi¹, DMD; Tannaz Abdollahzadeh Baghaei², DMD;

¹ Dept. of Oral and Maxillofacial Surgery, Faculty of Dentistry, Tabriz University of Medical Sciences, Tabriz, Iran.

² Dept. of Orthodontics, Faculty of Dentistry, Tabriz University of Medical Sciences, Tabriz, Iran.

KEY WORDS

Amnion;
Nasal septal perforation;
Nasal surgical procedures;

Received: 12 April 2021;
Revised: 14 August 2021;
Accepted: 5 September 2021;

Copyright

© Journal of Dentistry
This is an Open Access article distributed under the terms of the Creative Commons Attribution- Non Commercial 4.0 Unported License, (<http://creativecommons.org/licenses/by/4.0/>) which permits unrestricted use, distribution, and reproduction in any medium, provided the original work is properly cited.

ABSTRACT

Statement of the Problem: The surgical repair of nasal septal perforation (NSP) has always been a challenging procedure and no consensus has been made about a definitive protocol.

Purpose: In the current study, we investigated the use of cryopreserved amniotic membrane with mucosal rotational flap for the surgical repair of NSPs.

Materials and Method: In this prospective clinical study, 12 patients with symptomatic NSP underwent primary surgical repair, between December 2018 and October 2019. The surgical procedure comprised of a rotational flap on one side of the defect and cryopreserved amniotic membrane as an interpositional graft in the mucoperichondrial pocket on the other side. The patency of defect was checked at a follow-up appointment at least 3 months after surgery.

Results: Successful repair was perceived in 10 of 12 (83%) of patients. Reperforation occurred in two patients but the size of the defect was smaller than the original one. All of the patients reported elimination of all symptoms associated with NSP.

Conclusion: The use of cryopreserved amniotic membrane as an interpositional graft accompanied by a mucosal rotational flap seems to be efficient in alleviating the symptoms of NSP and closure of the defect.

Corresponding Author: Hashemi M, Dept. of Oral and Maxillofacial Surgery, Tabriz University of Medical Sciences, Tabriz, Iran. Tel: +98-04133347054 Email: mohsen.hashemi3263@gmail.com

Cite this article as: Farhadi Shabestari F, Khorshidi Khiavi R, Hashemi M, Abdollahzadeh Baghaei T. Surgical Repair of Nasal Septal Perforation by Mucosal Rotational Flap and Interposition of Cryopreserved Amniotic Membrane. *J Dent Shiraz Univ Med Sci.* September 2022; 23(3): 278-283.

Introduction

Nasal septal perforation (NSP) is a relatively common anatomic defect of the nasal septum and affect nearly 1% of the general population [1-2]. The etiology of NSP is varied, but is often the result of trauma, inhaled irritants, neoplasm and infectious or inflammatory disorders [3]. For symptomatic septal defects, symptoms include epistaxis, discharge, nasal obstruction, crusting, dryness, pain and whistling. However, around 62% are asymptomatic, which do not require closure [4]. Various techniques for repair of these perforations have been suggested including flaps [5], tissue expansion [6], and the use of allogeneic tissues, and biomaterials [7-8].

Human amniotic membrane

Human amniotic membrane (HAM) is growingly being

used as an allograft material in surgical procedures related to the genitourinary tract, skin, brain, and head and neck, particularly in ophthalmological reconstructive surgery. Some papers have recently suggested the use of HAM in oral and maxillofacial surgery [9-10]. It has been used for increasing the rate of survival of ischemic random pattern flaps [11], vestibuloplasty [12-13], implant surgery [14], closure of oronasal fistula [15], and replacement of diseased nasal mucosa [16], arthroplasty [17], and gingival wound healing [18]. Moreover, HAM is easily available and reasonably priced regarding its harvesting and processing to a medical product (for instance, testing for viral infections of the donors and cryopreservation) [19]. In the current study, we investigated the use of multilayered HAM for the surgical repair of NSPs.

Materials and Method

After acceptance by the Ethics Committee of Tabriz University of Medical Sciences (code: IR.TBZMED.REC.1397.662), this study was conducted on 12 symptomatic patients with NSP (8 male and 4 female subjects). Patients with any form of tobacco use, defects larger than 2 cm, and an underlying systemic disease such as autoimmune problems were excluded. None of the patients had unsuccessful previous surgical repair. The participants underwent surgical closure of the perforation between December 2018 and October 2019, at Oral and Maxillofacial Department of Tabriz University of Medical Sciences. Written informed consent was obtained from both the participants and the mothers donating HAM. The situation of all perforations was at the anterior part of septum. The size of perforation was determined by the largest diameter of the defect and was measured by a ruler in a nasal examination (Figure 1). During the presurgical period, daily irrigation of the nasal cavity was performed by sterile saline for 2 weeks. Nasal mupirocin ointment (Mupirocin 2%, Sina Daru Co., Tehran, Iran) was applied after irrigation.

Surgical technique

The surgery was conducted by closed approach. Mucosal rotational flap was planned to be raised on the side with a more patent nostril for better access and the mucoperichondrial flap on the contralateral side. At the beginning, 1% lidocaine with 1: 100,000 epinephrine

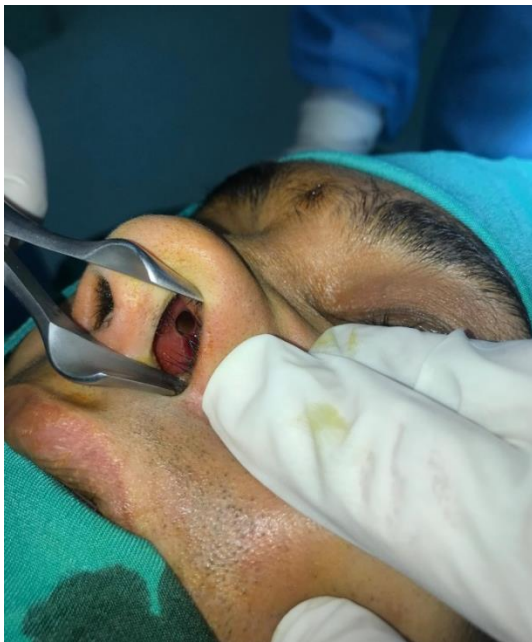

Figure 1: Diameter of nasal septal perforation was measured preoperatively

was injected in the septal area, and then oxymetazoline-soaked cotton was placed intranasally. The periphery of the defect was sharply incised. The incision for the mucosal rotational flap starts in the posteroinferior portion of the septum, continues in an anterosuperior direction, and reaches to the anterior border of the perforation. The blood supply of the flap is provided by a branch of the sphenopalatine artery (the posterior nasal artery). After elevation of the rotational flap, it was sutured to the periphery of the defect with chromic gut (Figure 2).

The cartilage was left exposed on the posterior superior aspect of the flap pedicle (Figure 1). On the contralateral side of the septum, a hemitransfixion incision was made and a mucoperichondrial flap was elevated. Then, cryopreserved HAM was cut to fit the perforation size and was placed in the mucoperichondrial pocket (Figure 3). Finally, the hemitransfixion incision was sutured and internal splints coated in tetracycline 3% ointment, were placed intranasally (Figure 4). The internal splints were removed two weeks later.

Follow-up

All patients were followed at least 3 months after surgery to check the closure of the defect.

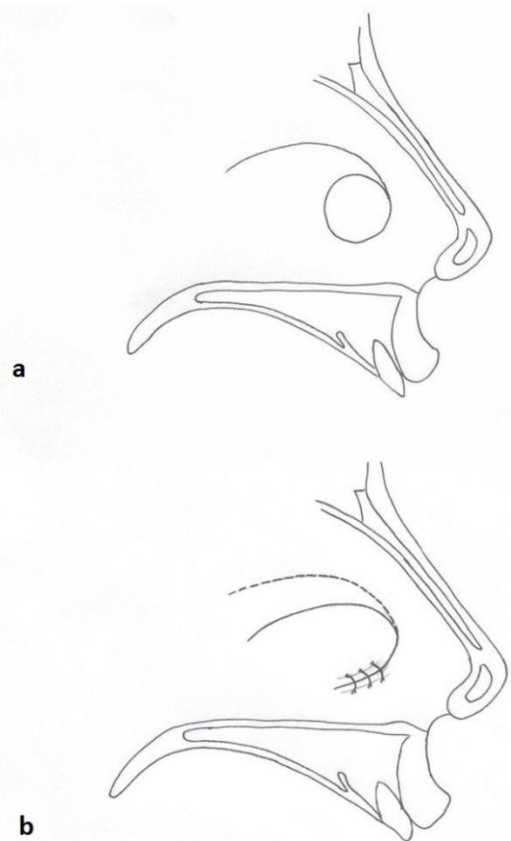


Figure 2a: Diameter of nasal septal perforation was measured preoperatively. **b:** Rotational flap based on posterior nasal artery

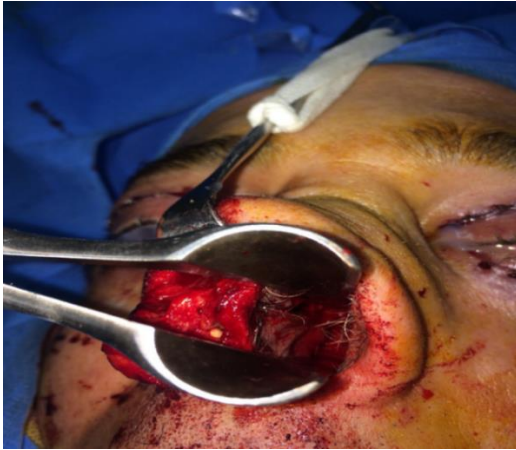

Figure 3: Rotational mucosal flap was performed on one side of septum

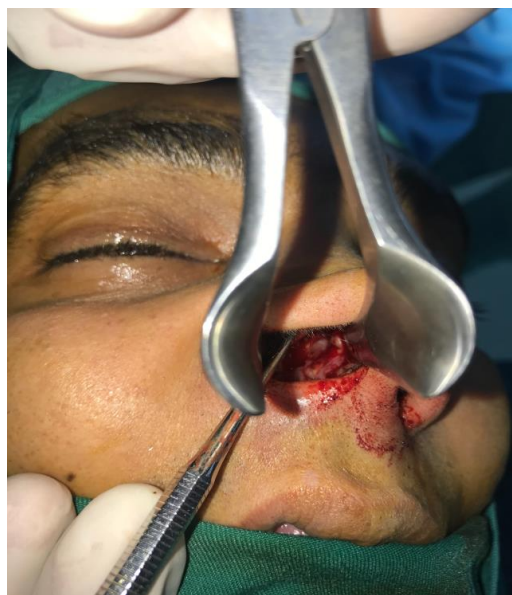

Figure 4: Preserved amniotic membrane was placed in the mucoperichondrial pocket on the other side of septum

Results

The patients were aged between 18 and 40 years (mean: 32.5). Mean defect size was 1.49 cm (range: 1 to 2cm). Epistaxis and dryness were the most common sympto-

ms. Successful closure of the defect was observed in 10 out of 12 patients, which means a success rate of 83%. Table 1 depicts the data of all cases and results of surgical repair of each case. The closure rate is 100% in cases with a defect smaller than 1cm and 80% in cases with a defect size of 1-2cm. A considerable reduction in the size of defect was noted in the two cases with reoperation. Total healing of normal mucosa and elimination of crusting was detected in all of the cases whose defect was completely closed. All of the cases, including the two cases with reoperation, reported elimination of all symptoms associated with NSP during the post-surgical period.

Discussion

NSP occurs in cases with blood supply deprivation due to rupture of the mucoperichondrium on both sides of the septal cartilage. This condition is possibly encountered in patients with history of trauma, surgical manipulation of the nasal septum, various drugs, and tumors [20]. In this study, NSP was mainly associated with surgical manipulation and trauma. Prevention is the best way for management of NSP [21].

NSP typically does not cause any symptoms, especially the ones located posteriorly. These defects tend to be smaller and less symptomatic due to better humidification in this area. On the other hand, the perforations located anteriorly are presumably associated with symptoms such as a sense of dryness, as it was in all of our cases. Fortunately, manipulation of mucoperichondrium and managing flaps is much easier in anteriorly positioned defects. Epistaxis and dryness were the most common complaints in this study.

The main purpose of treatment should be improvement of the quality of life by alleviating the symptoms.

Table 1: Patient information, and the results of surgical repair

Patient No.	Sex	Age	Cause of perforation	Size	Result	Follow-up duration (months)
1	M	27	Unknown	1.5 cm	Closure	12
2	M	30	Trauma	1.3 cm	Closure	11
3	F	35	Septo/septorhinoplasty	2 cm	Closure	11
4	M	32	Trauma	2 cm	Closure	10
5	F	34	Septo/septorhinoplasty	1.4 cm	Closure	10
6	M	38	Septo/septorhinoplasty	1.6 cm	0.8 cm Defect	10
7	M	33	Trauma	1 cm	Closure	8
8	M	40	Trauma	2 cm	0.6 cm Defect	7
9	F	26	Septo/septorhinoplasty	1.2 cm	Closure	7
10	F	29	Septo/septorhinoplasty	1 cm	Closure	5
11	M	37	Septo/septorhinoplasty	1.5 cm	Closure	4
12	M	29	Trauma	1.4 cm	Closure	3

The first line of treatment is aggressive irrigation of the nasal cavity and topical moisturizing ointments [7]. The use of septal buttons may cause even more widening of the defect and therefore could worsen the symptoms [22]. Surgical intervention is the final line in the treatment of NSP, provided when the cause of the defect is not a persistent source such as systemic condition like autoimmune disorders or cocaine abuse [23]. Many surgical approaches have been reported, none of which has been advocated by high-level evidence as the gold standard [20]. This is mostly due to the variety of applied approaches and insufficient sample size. The reported follow-up duration is also important. Some defects may seem to be successfully closed but reoperation may occur after a while [24].

A rotational flap design was considered to close the defect in this study. Rotational flaps as compared to bipediced flaps are more easily advanced without adding tension to the flap [25]. There is no controlled study to compare flap-only closure with flaps plus interpositional grafts, but higher closure rates are reported by studies utilizing local mucosal flaps and interposition grafts compared to studies using only local mucosal flaps to close perforations [25-30]. There are numerous alternatives for the graft material. Autografts such as temporal fascia, periosteum, bone of nasal septum, and allografts such as human dermis has been used [31]. Autografts like temporal fascia [26, 32] and mastoid periosteum [29, 33] have shown high success rates but donor site morbidity remains as a drawback. Septal graft also doubles this problem by reducing the support of the septal area and therefore increasing the risk of reoperation or even formation of a new defect [34]. Acellular human dermal graft has also been suggested as it is available in sufficient amounts, eliminates morbidity, and is thicker than grafts such as temporal fascia. Studies have reported miscellaneous results about the advantage of this graft material [7, 35-36]. Human amniotic membrane (HAM) is a newly introduced graft material, which is routinely used in ophthalmology. It has recently been used in oral and maxillofacial surgery for healing of the soft tissue around dental implants, healing of intraoral wounds, vestibuloplasty, and treatment of gingival recession [10, 37-38]. Properties such as improvement of intraoral and extraoral epithelialization, pain reduction, and scarring make HAM a suitable graft

material in defects such as NSPs [10].

In our study, 83.3% of all cases showed complete closure at the follow-up appointment. The closure rate was 100% in cases with a defect equal to or smaller than 1 cm and 80% in cases with a larger defect. This is a higher success rate compared to Delaney and Kridle [39] who reported a success rate of 90% for perforations smaller than 1cm and 73% for larger perforations. Reoperation occurred in two cases. Despite the reoperation of these cases, all of the cases reported no symptoms in the follow-up appointment, which means that the main goal of alleviation of symptoms was achieved. This results show a promising effect for application of HAM as an interpositional graft in surgical repair of NSPs. Both of the cases with reoperation had relatively large defects (more than 1.5cm). One of these cases had a history of nasal spray consumption, which may have limited the blood supply of the adjacent mucosa irreversibly and thereby have worsened the healing potential of local soft tissue. The follow-up duration was not the same for all of the cases. A longer follow-up period would be beneficial in the future studies as reoperation is possible after a while. Unfortunately, due to the limited number of cases, any statistical evaluation of the results was not possible, but it seems that more experience with HAM as graft material in NSP repair would possibly show high success rates and complete elimination of the symptoms. Further studies with this graft material would be advantageous.

Conclusion

Surgical repair of NSPs is a challenging procedure. Considering the stimulation of epithelialization by HAM as a biomembrane, it seems that using it as a graft material accompanied by a mucosal rotational flap would be beneficial. Although the rate of complete defect closure was not 100%, elimination of the symptoms in all cases indicates that this technique may help us for a better management of the patients suffering from NSP.

Conflict of Interest

The authors declare that they have no conflict of interest.

References

- [1] Oberg D, Akerlund A, Johansson L, Bende M. Prevalen-

- ce of nasal septal perforation: the Skovde population-based study. *Rhinology*. 2003; 41: 72-75.
- [2] Tasca I, Compadretti GC. Closure of nasal septal perforation via endonasal approach. *Otolaryngol Head Neck Surg*. 2006; 135: 922-927.
- [3] Daneshi A, Mohammadi S, Javadi M, Hassannia F. Repair of large nasal septal perforation with titanium membrane:: report of 10 cases. *Am J Otolaryngol*. 2010; 31: 387-389.
- [4] Heller JB, Gabbay JS, Trussler A, Heller MM, Bradley JP. Repair of large nasal septal perforations using facial artery musculomucosal (FAMM) flap. *Ann Plast Surg*. 2005; 55: 456-459.
- [5] André R, Lohuis P, Vuyk H. Nasal septum perforation repair using differently designed, bilateral intranasal flaps, with nonopposing suture lines. *J Plast Reconstr Aesthet Surg*. 2006; 59: 829-834.
- [6] Kobus KF. Cleft palate repair with the use of osmotic expanders: a preliminary report. *J Plast Reconstr Aesthet Surg*. 2007; 60: 414-421.
- [7] Ayshford C, Shykhon M, Uppal H, Wake M. Endoscopic repair of nasal septal perforation with acellular human dermal allograft and an inferior turbinate flap. *Clin Otolaryngol*. 2003; 28: 29-33.
- [8] Parry JR, Minton TJ, Suryadevara AC, Halliday D. The use of fibrin glue for fixation of acellular human dermal allograft in septal perforation repair. *Am J Otolaryngol*. 2008; 29: 417-422.
- [9] Dua HS, Gomes JA, King AJ, Maharajan VS. The amniotic membrane in ophthalmology. *Surv Ophthalmol*. 2004; 49: 51-77.
- [10] Kesting MR, Wolff KD, Nobis CP, Rohleder NH. Amniotic membrane in oral and maxillofacial surgery. *Oral Maxillofac Surg*. 2014; 18: 153-164.
- [11] Özkaya Ö, Egemen O, Yeşilada A, Sakız D, Ugurlu K. The effect of nonpreserved human amniotic membrane on the survival of ischaemic skin flaps in rats. *J Plast Reconstr Aesthet Surg*. 2012; 65: 1700-1705.
- [12] Güler R, Ercan M, Ulutuncel N, Devrim H, Uran N. Measurement of blood flow by the ¹³³Xe clearance technique to grafts of amnion used in vestibuloplasty. *Br J Oral Maxillofac Surg*. 1997; 35: 280-283.
- [13] Samandari MH, Yaghmaei M, Ejlali M, Moshref M, Saffar AS. Use of amnion as a graft material in vestibuloplasty: a preliminary report. *Oral Surg Oral Med Oral Pathol Oral Radiol Endod*. 2004; 97: 574-578.
- [14] Velez I, Parker WB, Siegel MA, Hernandez M. Cryopreserved amniotic membrane for modulation of periodontal soft tissue healing: a pilot study. *J Periodontol*. 2010; 81: 1797-1804.
- [15] Kesting MR, Loeffelbein DJ, Classen M, Slotta-Huspenina J, Hasler RJ, Jacobsen F, et al. Repair of oronasal fistulas with human amniotic membrane in minipigs. *Br J Oral Maxillofac Surg*. 2010; 48: 131-135.
- [16] Laurian N, Kalmanovitch M, Shimberg R. Amniotic graft in the management of severe epistaxis due to hereditary haemorrhagic telangiectasia. *J Laryngol Otol*. 1979; 93: 589-595.
- [17] Tuncel U, Ozgenel G. Use of human amniotic membrane as an interpositional material in treatment of temporomandibular joint ankylosis. *J Oral Maxillofac Surg*. 2011; 69: e58-e66.
- [18] Rinastiti M, Santoso A, Sosroseno W. Histological evaluation of rabbit gingival wound healing transplanted with human amniotic membrane. *Int J Oral Maxillofac Surg*. 2006; 35: 247-251.
- [19] Rohleder NH, Loeffelbein DJ, Feistl W, Eddicks M, Wolff KD, Gulati A, et al. Repair of oronasal fistulae by interposition of multilayered amniotic membrane allograft. *Plast Reconstr Surg*. 2013; 132: 172-181.
- [20] Chhabra N, Houser SM. Endonasal repair of septal perforations using a rotational mucosal flap and acellular dermal interposition graft. *Int Forum Allergy Rhinol*. 2012; 2: 392-396.
- [21] Lee HR, Ahn DB, Park JH, Kim YH, Sin CM, Youn SJ, et al. Endoscopic repairment of septal perforation with using a unilateral nasal mucosal flap. *Clin Exp Otorhinolaryngol*. 2008; 1: 154.
- [22] Watson D, Barkdull G. Surgical management of the septal perforation. *Otolaryngol Clin North Am*. 2009; 42: 483-493.
- [23] Re M, Paolucci L, Romeo R, Mallardi V. Surgical treatment of nasal septal perforations. Our experience. *Acta Otorhinolaryngol Ital*. 2006; 26: 102.
- [24] Goh A, Hussain S. Different surgical treatments for nasal septal perforation and their outcomes. *J Laryngol Otol*. 2007; 121:419-426.
- [25] Kridel RW, Appling WD, Wright WK. Septal perforation closure utilizing the external septorhinoplasty approach. *Arch Otolaryngol Head Neck Surg*. 1986;112:168-172.
- [26] Fairbanks D, Fairbanks GR. Nasal septal perforation: prevention and management. *Ann Plast Surg*. 1980; 5: 4-

- 52-459.
- [27] Murakami CS, Kriet JD, Ierokomos AP. Nasal reconstruction using the inferior turbinate mucosal flap. *Arch Facial Plast Surg.* 1999;1:97-100.
- [28] Romo T, Foster CA, Korovin GS, Sachs ME. Repair of nasal septal perforation utilizing the midface degloving technique. *Arch Otolaryngol Head Neck Surg.* 1988;114:739-742.
- [29] Teichgraeber JF, Russo RC. The management of septal perforations. *Plast Reconstr Surg.* 1993; 91: 229-235.
- [30] Vuyk H, Versluis R. The inferior turbinate flap for closure of septal perforations. *Clin Otolaryngol.* 1988;13:53-57.
- [31] Murrell GL, Karakla DW, Messa A. Free flap repair of septal perforation. *Plast Reconstr Surg.* 1998; 102: 818-821.
- [32] Belmont JR. An approach to large nasoseptal perforations and attendant deformity. *Arch Otolaryngol.* 1985; 111: 450-455.
- [33] Romo T, Jablonski RD, Shapiro AL, McCormick SA. Long-term nasal mucosal tissue expansion use in repair of large nasoseptal perforations. *Arch Otolaryngol Head Neck Surg.* 1995; 121: 327-331.
- [34] Ohlsén L. Closure of nasal septal perforation with a cutaneous flap and a perichondrocutaneous graft. *Ann Plast Surg.* 1988; 21: 276-288.
- [35] Kridel RW, Foda H, Lunde KC. Septal perforation repair with acellular human dermal allograft. *Arch Otolaryngol Head Neck Surg.* 1998;124:73-8.
- [36] Romo T, Sclafani AP, Falk AN, Toffel PH. A graduated approach to the repair of nasal septal perforations. *Plast Reconstr Surg.* 1999; 103: 66-75.
- [37] Kothari CR, Goudar G, Hallur N, Sikkerimath B, Gudi S, Kothari MC. Use of amnion as a graft material in vestibuloplasty: a clinical study. *Br J Oral Maxillofac Surg.* 2012; 50: 545-549.
- [38] Rehan M, Khatri M, Bansal M, Puri K, Kumar A. Comparative Evaluation of Coronally Advanced Flap Using Amniotic Membrane and Platelet-rich Fibrin Membrane in Gingival Recession: An 18-Month Clinical Study. *Contemp Clin Dent.* 2018; 9: 188.
- [39] Delaney SW, Kridel RW. Contemporary trends in the surgical management of nasal septal perforations: a community survey. *Facial Plast Surg.* 2019; 35:78-84.