

Original Article

Does the Angulation of an Impacted Mandibular third Molar Affect the Prevalence of Preoperative Pathoses?

Ahmet Altan ¹, Nihat Akbulut ¹

¹ Dept. of Oral and Maxillofacial Surgery, Faculty of Dentistry, Gaziosmanpaşa University, Tokat, Turkey.

KEY WORDS

Tooth, impacted;
Mandible;
Surgery, oral;
Pathology;
Molar, third;

Received January 2018;
Received in Revised form April 2018;
Accepted April 2018;

ABSTRACT

Statement of the Problem: The removal of a third molar tooth associated with a pathological condition is usually an easy decision. However, it is necessary for clinicians to know about the prevalence of preoperative pathologies associated with impacted mandibular third molars to the identification of the prophylactic approach to be applied to symptom-free impacted third molars.

Purpose: The objective was to investigate the effect of the angulation of impacted mandibular third molars on the prevalence of associated pathologies.

Materials and Method: In this retrospective study, we examined the panoramic radiographs of 954 patients referred for impacted third molar surgery. A total of 1598 impacted mandibular third molar teeth were included in the study. Pathological conditions included the caries on distal surface of the adjacent second molar, caries on impacted mandibular third molars, bone loss distal to the adjacent second molar, the radiolucent area distal to the impacted mandibular third molar were determined.

Results: Caries were observed more in the impacted third molar (18.9%) compared to the adjacent second molar (15.8%). The radiolucent area on distal surface of the impacted mandibular molar was 11%, while the periodontal bone loss distal to the adjacent second molar was 4.9%. Mesioangular-impacted mandibular third molars had high risk of caries development on second and third molar. The prevalence of periodontal tissue damage to the adjacent second molar was higher in horizontal and mesioangular angulation. Vertical and distoangular-impacted mandibular third molars had high risk for bone loss at distal aspect.

Conclusion: The prevalence rate of pathological conditions in mesioangular impacted teeth was higher.

Corresponding Author: Altan A., Gaziosmanpaşa University, Faculty of Dentistry, Ali Sevki Ereğ Yerleşkesi, Tokat, Turkey Tel: +905057013189 Fax: +90356212 4225 Email: dt.ahmetaltan@gmail.com

Cite this article as: Altan A., Akbulut N. Does the Angulation of an Impacted Mandibular third Molar Affect the Prevalence of Preoperative Pathoses? *J Dent Shiraz Univ Med Sci.*, March 2019; 20(1): 48-52.

Introduction

The third molars are the last teeth to erupt and are the most posterior in the oral cavity. Of all of the teeth, the mandibular third molars remain the most impacted. [1] These teeth may remain impacted due to reasons such as insufficient retromolar distance, precocious loss of a second molar tooth, and the density in the bone structure. The impacted tooth may remain in the jaw without causing symptoms for years, but may also cause pathologies such as pericoronitis, infection, non-restorable decay, and root resorption in adjacent teeth, periodontal

bone loss, cystic lesions, and neoplasms. [2]

The surgical extraction of these teeth for prophylactic, orthodontic, and prosthetic reasons, or for the diagnosis of associated pathologies is one of the most commonly applied dentoalveolar procedures in oral and maxillofacial surgery. [3] Various methods have been used for the classification of impacted third molars. The oral surgeon may speculate on the difficulty of an extraction according to the anatomical position of the impacted molars. [4] Furthermore, understanding the relationships between associated pathological conditions

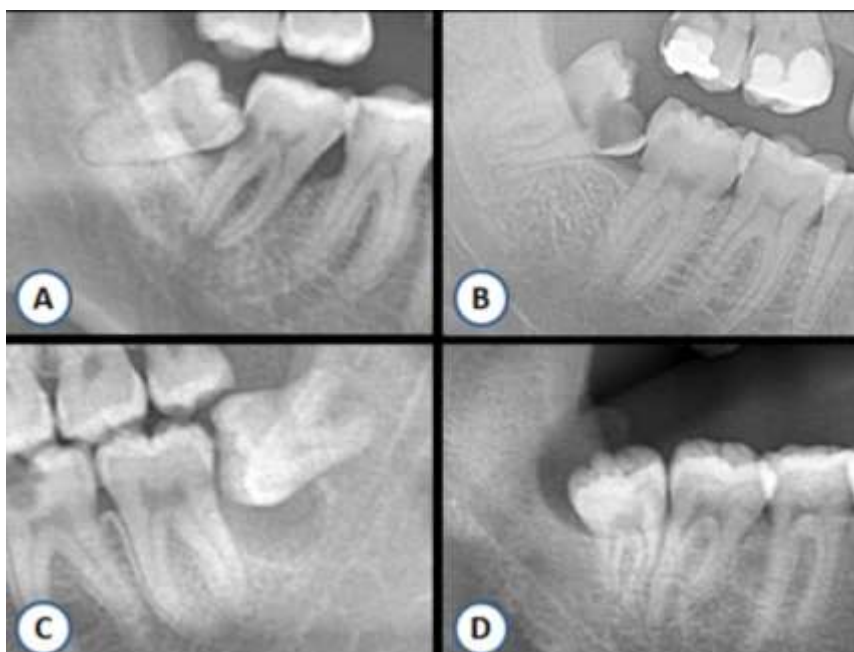


Figure 1a: Caries in adjacent second molar, **b:** Caries in impacted mandibular third molar, **c:** Periodontal bone loss of the adjacent molar, **d:** Radiolucency of the distal aspect of impacted mandibular third molar

and classifications can help the dentist or oral surgeon decide on the appropriate prophylactic extraction of asymptomatic teeth. One of these classifications is the Winter classification, [5] which is made according to the angle of the third molar.

The aim of this study was to investigate the effect of the angulation of impacted mandibular third molars on the prevalence of associated pathologies, based on radiological criteria.

Materials and Method

In this retrospective study, we examined and analyzed the panoramic radiographs of 954 patients (531 females, 423 males) referred for impacted third molar dental surgery to Gaziosmanpasa University, Faculty of Dentistry, Department of Oral and Maxillofacial Surgery, between the years 2013 to 2017. A total of 1598 impacted mandibular third molar teeth extracted under local anesthesia were included in the study. The local Ethics Committee approved this study (Project # 17KA EK154). Patients without adjacent second molar teeth, fully erupted third molars, and radiographs with low quality images were excluded from the study.

In this study, the Shiller method [6] was used to measure the angular values of the impacted third molars. The angulation of the impacted third molar was determined as the angle between the mandibular occlusal plane and the occlusal plane of the third molar. Ac-

cording to the data obtained from panoramic radiographs, the angles such as 0-10° vertical, 11-70° mesioangular, $\geq 71^\circ$ horizontal, rare cases with distoangular, buccolingual, mesioinversion, distoinversion angulation were classified as “others.”

Pathological conditions determined from panoramic radiographs were sorted. These conditions included the caries on the distal surface of the adjacent second molar, caries on impacted mandibular third molars, bone loss distal to the adjacent second molar, and the radiolucent area distal to the impacted mandibular third molar (Figure 1).

An experienced surgeon evaluated panoramic radiographs. To check the diagnostic repeatability, a second surgeon randomly examined 30 panoramic radiographs with radiographic lesions for five consecutive days. No difference was found between the two observers.

SPSS 20.0 package program was used in the statistical analyses of the study data. Descriptive statistics and chi-square tests were used in the data analyses. When the p value was less than 0.05, the difference between the variables was considered statistically significant.

Results

In this study, panoramic radiographs of 954 patients were examined and 1598 impacted teeth were analyzed.

Table 1: Age and gender distribution of patients with impacted mandibular third molars

Age Groups	Female	Male	Total
16-20	85	59	144
21-25	238	142	380
26-30	94	96	190
31-35	67	56	123
≥36	47	70	117
Total	531	423	954

A total of 891 (55.8%) of these teeth were observed in female patients and 707 (44.2%) were observed in male patients. The patients' ages ranged from 16–64 (mean= 26.42±7.6) years. Most of the patients who underwent impacted third molar surgery were between 20–30 years. Age and gender distributions are presented in Table 1.

There were 630 (39.4%) of the 1598 teeth that were associated with at least one pathologic condition that could be detected radiographically. The caries in the second and third molars, periodontal bone loss distal to the adjacent second molar, and the prevalence of the radiolucent area distal to the third molar are summarized in Table 2. Caries were the most common pathological situation. Caries were observed more in the impacted third molar (18.9%) compared to the adjacent second molar (15.8%). The radiolucent area on the distal surface of the impacted mandibular molar was 11%, while the periodontal bone loss distal to the adjacent second molar was 4.9%.

When the prevalence of the caries distal to the adjacent second molars was evaluated, the impaction in the mesioangular position ($\chi^2=176, 02$) had higher ratios than the other angulations ($p < 0.05$). Similarly, the prevalence of caries in impacted third molars was higher in the group with mesioangular impactions ($\chi^2=23, 2$) compared to other groups ($p < 0.05$).

The prevalence of periodontal bone loss distal to the adjacent second molar was higher ($\chi^2=81, 64$) in

those with mesioangular and horizontal impactions ($p < 0.05$). The radiolucent prevalence distal to the impacted third molars was higher ($\chi^2=124, 42$) in the vertical and "others" group containing the distoangular angles ($p < 0.05$).

Discussion

The extraction of impacted third molars is one of the most commonly performed procedures in oral and maxillofacial surgery. Impacted third molars may cause pericoronitis, periodontal diseases, and pathologies such as caries, cyst-tumor formations, and systemic infections that can threaten the patient's life. [2, 7] In such compulsory situations, the extraction of the impacted third molar is inevitable. However, in asymptomatic situations, complications including pain, swelling, infection, and nerve injury that may occur due to tooth extraction lead to the avoidance of the prophylactic extraction of the teeth. In this retrospective study, the relationship between the angulations of the preoperative pathologies associated with the impacted mandibular third molars was examined. It is thought that the results of this study may help in the decisions concerning the extraction of these teeth.

A number of classifications have been made for preoperative evaluations of impacted third molar teeth. [5, 8] Different classifications may provide an idea about the difficulty of the procedure before the surgery. One of these classifications is the winter classification. [5] According to this classification, the impacted third molars are divided into groups according to their angles, such as vertical, mesioangular, horizontal, and distoangular.

In this study, the relationship between the groups formed by Winter classification [5] and preoperative pathologies was examined. It was determined that the prevalence of pathology in teeth in the mesioangular

Table 2: Prevalence of pathologies associated with impacted mandibular third molars

Pathologic Conditions	n	Caries in adjacent second molar		Caries in impacted mandibular third molar		Periodontal bone loss of the adjacent molar		Radiolucency of the distal aspect of impacted mandibular third molar	
		Yes	No	Yes	No	Yes	No	Yes	No
Vertical	815	45(5.5%)	770(94.5%)	133(16.3%)	682(83.7%)	2(0.2%)	813(99.8%)	154(18.9%)*	661(81.1%)
Mesioangular	548	173(31.6%)*	375(68.4%)	132(24.1%)*	416(75.9%)	58(10.6%)*	490(89.4%)	10(1.8%)	538(98.2%)
Horizontal	192	34(17.7%)	158(82.3%)	37(19.3%)	155(80.7%)	17(8.9%)*	175(91.1%)	3(1.6%)	189(98.4%)
Others	43	-	43(100%)	-	43(100%)	2(4.7%)	41(95.3%)	11(25.6%)*	32(74.4%)
Total	1598	252(15.8%)	1346(84.2%)	302(18.9%)	1296(81.1%)	79(4.9%)	1519(95.1%)	178(11.1%)	1420(88.9%)

*Significantly different from other angulations.

group was higher compared to the other groups. These results will be able to help dental practitioners, especially in decisions concerning the prophylactic extraction of impacted mandibular third molars.

According to the results of this study, the most frequently encountered pathology was caries observed distal to the impacted third molar and adjacent second molar. In previous studies, it has been shown that the prevalence rate of caries distal to the adjacent second molar associated with the impacted mandibular third molar varied from 6% to 32%. [9-13] The prevalence in the current study was 15.8%. This variability between rates may be due to cultural and socioeconomic level differences among the patients. The angulation of the teeth may have also played a role in the ratio differences. There was a significant difference in the mesioangular group compared to the other groups and the prevalence was determined as 31.6% in mesioangular angulation. McArdle and Renton [14] suggested the prophylactic extraction of impacted third molars in the mesioangular position to prevent the development of distal caries in the mandibular second molars. Moreover, the prevalence may increase with the increasing age of the patients. [13] In the current study, the patients' ages ranged between 16 and 64 years, but the average age was 26.42 years; thus, the study group was at an age that could still be considered young.

One of the pathologies examined in this study was the presence of a radiolucent area distal to the impacted mandibular third molars. The prevalence rate of the radiolucent area in the vertical and the "others" group including distoangular angulations was higher and statistically significant compared to mesioangular and horizontal groups. This result is similar with the results of the study carried out by Polat *et al.* [2] The cyst formation associated with impacted third molars has been reported. [15] The expanded radiolucent image in the pericoronal region of the impacted third molar may help in providing information concerning cystic changes. However, Stephen *et al.* [16] reported that increased radiolucent width may lead to a false-positive diagnosis and an increase in the prevalence rate. The fact that no change was determined in the radiolucent area in 4-year follow-ups of asymptomatic impacted third molars supports this hypothesis. [17] Therefore, it is useful to perform radiological and his-

tological examinations together to be able to state whether there is a cystic pathological change.

Another pathology associated with impacted third molars is the periodontal bone loss observed distal to the adjacent second molars. In this study, the mesioangular and horizontally impacted mandibular third molars led to significantly more periodontal bone loss distal to the adjacent second molars. In their study, Brickley *et al.* [18] reported that bone loss distal to the second molars was associated with the mesioangular impacted third molars. In our study, the periodontal bone loss distal to the adjacent second molar was higher in the mesioangular group compared to other groups.

There are several limitations to consider when interpreting the results of this retrospective study. First, extraoral radiographs have low sensitivities in detecting proximal caries [19-20] Panoramic radiography may not detect early caries lesions; however, deep caries lesions that have advanced to the dentine can be detected. Akarslan *et al.* [21] reported that when interproximal caries were detected in mandibular molar teeth, panoramic radiographs were less accurate than bitewing and periapical radiographies for this diagnosis. We selected the patients with a complaint of impacted third molar teeth in this study. Oral surgeons in our department routinely use panoramic radiographs in patients for impacted third molar surgery. In addition, the direction of eruption in the mandibular lower third molar can be predicted more accurately with tomographic technique. If we have risks such as inferior alveolar nerve proximity, we prefer tomography. We performed the study in accordance with ethical rules with panoramic radiographs giving less radiation.

Conclusion

The results showed that there was a relationship between the angulation of the impacted third molar and the prevalence of pathologies observed. The prevalence rate of pathological conditions in mesioangular-impacted teeth was higher. These data concerning the natural course of impacted teeth may contribute to both more precise predictions of the complication risks associated with impacted mandibular third molars and to the identification of the prophylactic approach to be applied to symptom-free impacted third molars.

Conflict of Interest

The authors declare that they have no conflict of interest.

References

- [1] Damlar İ, Altan A, Tatlı U, Arpağ OF. Retrospective Investigation of the Prevalence of Impacted Teeth in Hatay. *Cukurova Med J.* 2014; 39: 559-565.
- [2] Polat HB, Ozan F, Kara I, Ozdemir H, Ay S. Prevalence of commonly found pathoses associated with mandibular impacted third molars based on panoramic radiographs in Turkish population. *Oral Surg Oral Med Oral Pathol Oral Radiol Endod.* 2008; 105: e41-e47.
- [3] Fuster Torres MA, Gargallo Albiol J, Berini Aytés L, Gay Escoda C. Evaluation of the indication for surgical extraction of third molars according to the oral surgeon and the primary dentist. Experience in the Master of Oral Surgery and Implantology at Barcelona University Dental School. *Med Oral Patol Oral Cir Bucal.* 2008; 13: E499-E504.
- [4] Hashemipour MA, Tahmasbi-Arashlow M, Fahimi-Hanzaei F. Incidence of impacted mandibular and maxillary third molars: a radiographic study in a Southeast Iran population. *Med Oral Patol Oral Cir Bucal.* 2013; 18: e140-e145.
- [5] Winter GB. Principles of exodontia as applied to the impacted third molar. 1st ed. American Medical Books: St Louis; 1926. p. 241-279
- [6] Shiller WR. Positional changes in mesio-angular impacted mandibular third molars during a year. *J Am Dent Assoc.* 1979; 99: 460-464.
- [7] Bataineh AB, Albashaireh ZS, Hazza'a AM. The surgical removal of mandibular third molars: a study in decision making. *Quintessence Int.* 2002; 33: 613-617.
- [8] Pell GJ, Gregory BT. Impacted mandibular third molars: classification and modified techniques for removal. *Dent Digest.* 1933; 39: 330-338.
- [9] Chang SW, Shin SY, Kum KY, Hong J. Correlation study between distal caries in the mandibular second molar and the eruption status of the mandibular third molar in the Korean population. *Oral Surg Oral Med Oral Pathol Oral Radiol Endod.* 2009; 108: 838-843.
- [10] Chu FC, Li TK, Lui VK, Newsome PR, Chow RL, Cheung LK. Prevalence of impacted teeth and associated pathologies--a radiographic study of the Hong Kong Chinese population. *Hong Kong Med J.* 2003; 9: 158-163.
- [11] Ozeç I, Hergüner Siso S, Taşdemir U, Ezirganlı S, Göktoğra G. Prevalence and factors affecting the formation of second molar distal caries in a Turkish population. *Int J Oral Maxillofac Surg.* 2009; 38: 1279-1282.
- [12] van der Linden W, Cleaton-Jones P, Lownie M. Diseases and lesions associated with third molars. Review of 1001 cases. *Oral Surg Oral Med Oral Pathol Oral Radiol Endod.* 1995; 79: 142-145.
- [13] Falci SG, de Castro CR, Santos RC, de Souza Lima LD, Ramos-Jorge ML, Botelho AM, et al. Association between the presence of a partially erupted mandibular third molar and the existence of caries in the distal of the second molars. *Int J Oral Maxillofac Surg.* 2012; 41: 1270-1274.
- [14] McArdle LW, Renton TF. Distal cervical caries in the mandibular second molar: an indication for the prophylactic removal of the third molar? *Br J Oral Maxillofac Surg.* 2006; 44: 42-45.
- [15] Al-Khateeb TH, Bataineh AB. Pathology associated with impacted mandibular third molars in a group of Jordanians. *J Oral Maxillofac Surg.* 2006; 64: 1598-1602.
- [16] Stephens RG, Kogon SL, Reid JA. The unerupted or impacted third molar--a critical appraisal of its pathologic potential. *J Can Dent Assoc.* 1989; 55: 201-207.
- [17] Sewerin I, von Wowern N. A radiographic four-year follow-up study of asymptomatic mandibular third molars in young adults. *Int Dent J.* 1990; 40: 24-30.
- [18] Ahlqvist M, Gröndahl HG. Prevalence of impacted teeth and associated pathology in middle-aged and older Swedish women. *Community Dent Oral Epidemiol.* 1991; 19: 116-119.
- [19] Brickley M, Shepherd J, Mancini G. Comparison of clinical treatment decisions with US National Institutes of Health consensus indications for lower third molar removal. *Br Dent J.* 1993; 175: 102-105.
- [20] Clark HC, Curzon ME. A prospective comparison between findings from a clinical examination and results of bitewing and panoramic radiographs for dental caries diagnosis in children. *Eur J Paediatr Dent.* 2004; 5: 203-209.
- [21] Akarslan ZZ, Akdevelioğlu M, Güngör K, Erten H. A comparison of the diagnostic accuracy of bitewing, periapical, unfiltered and filtered digital panoramic images for approximal caries detection in posterior teeth. *Dentomaxillofac Radiol.* 2008; 37: 458-463.