

Case Report**Endodontic Management of Calcified Oehler's Type IIIb Dens Invaginatus in Permanent Maxillary Lateral Incisor Using Cone Beam Computed Tomography**Shaik Izaz¹, Nagesh Bolla¹, Bhargavi Dasari², Shilpa Guntaka³¹ Dept. of Conservative Dentistry and Endodontics, Sibar Institute of Dental Sciences, India.² Senior Lecturer, KIMS Dental College, Amalapuram, A.P, India, Preceptor, Dept. of Oral and Maxillofacial Radiology, Rutgers School of Dental Medicine, Newark, New Jersey, USA.³ MPH in Epidemiology and Biostatistics, University of Southern Mississippi, Hattiesburg, USA.**KEY WORDS**Cone-Beam Computed Tomography;
Dens invaginatus;
Maxillary lateral incisor;
Three dimensional obturation;Received April 2017;
Received in Revised form June 2017;
Accepted April 2018;**ABSTRACT**

Dens Invaginatus is a developmental disturbance resulting from abnormal morpho differentiation. It is characterized by an invagination of the enamel and dentin, creating a lumen inside the affected tooth, which may extend as deep as the apical foramen. In the present scenario, calcified Oehler's type IIIb dens invaginatus in left maxillary lateral incisor in 23-year-old male patient was seen. As the two-dimensional imaging lacks accuracy in such complicated cases, cone beam computed tomography was used to assess the calcification three dimensionally. Endodontic treatment was performed in two visits, using thermoplastized gutta percha obturation technique.

Corresponding Author: Shaik Izaz. Dept. of Conservative Dentistry and Endodontics, Sibar Institute of Dental Sciences, Guntur, Andhra Pradesh-522509, India. Email: shaik.ajas@gmail.com
Tel: +0958177786

Cite this article as: Izaz S., Bolla N., Dasari B., Guntaka Sh. Endodontic Management of Calcified Oehler's Type IIIb Dens Invaginatus in Permanent Maxillary Lateral Incisor Using Cone Beam Computed Tomography. *J Dent Shiraz Univ Med Sci.*, 2018 September; 19(3): 243-247.

Introduction

Dental invagination (DI) is one of the developmental malformations that usually affect permanent dentition resulting from the infolding of the enamel organ into the dental papilla prior to calcification of the dental tissues. The invagination originates in the crown and may elongate into the root. DI in a human tooth was first reported by Socrates in 1856 [1] There are different types of theories have been intended in relation to aetiology of DI. These interpolate infection, trauma, growth pressure on the dental arches in the course of odontogenesis effecting infolding of the enamel and rapid proliferation of the internal enamel epithelium and accelerated propagation of the internal enamel epithelium in to the concealed papilla. Nonetheless, the accurate cause of the lesions rest ambiguous. [2]

Oehler recommended the most universally preferred classification of this anomaly in 1957. [3] This classification is based on the enamel invagination depth noticed radiographically. Type I illustrates enamel lined invagination restricted to the upper part of the tooth;

type II exhibits elongation of the invagination ahead the cement-enamel junction terminating as a blind sac. Type III consists of penetration of the root by the invagination to create an extra canal opening on lateral side of root. DI lesions have been proclaimed to impinge 0.3% to 10% of the population. [3] Lateral incisors are frequently affected by DI supplanted by maxillary central incisors, and more barely premolar and canine teeth. These teeth can exist with uncommonly shaped crowns often elucidated as dilated, peg shaped, or barrel shaped. DI is arduous to treat because of the convoluted root canal system. [2]

Many treatments have been proposed in literature, including endodontic treatment of the invagination individually or together with the main canal, surgical treatment, or extraction of the entire tooth. [4] Cone beam computed tomography (CBCT) is a three dimensional (3D) radiographic technique that is suitable for several endodontic applications, such as the diagnosis and treatment of teeth with complicated or irregular root canal anatomy. [5] The purpose of this case report is to

interpret how CBCT was utilized for diagnosing, treatment planning, and successfully managing a complex dens invaginatus case with endodontic therapy.

Case Report

The aim of this case report is to present the nonsurgical endodontic management of non-vital type IIIb DI in left permanent maxillary lateral incisor (tooth #10) using CBCT as an advanced diagnostic tool. A 28-year male patient visited to the endodontic clinic with a chief complaint of discoloured left maxillary lateral incisor (Figure 1).

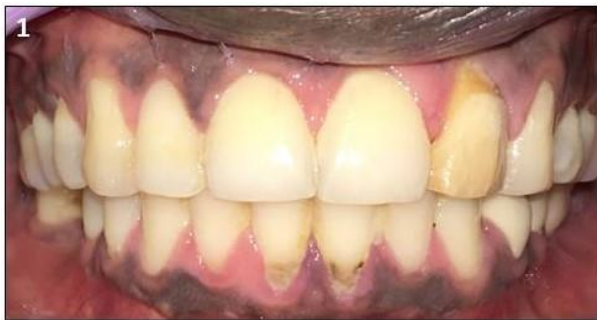

Figure 1: Pre-operative intra-oral view

On intraoral hard tissue examination tooth #10 was tender to palpation and pulp sensibility test with an electric pulp tester (Ashoo Sons API Pulp Tester, Delhi, India) disclosed tooth to be non-vital. Radiographic examination revealed uncommon root canal anatomy with widening of periodontal ligament space and periapical lesion at the apex (Figure 2a). Based on the clinical and radiological examination, it was diagnosed as dens invaginatus in tooth #10. The treatment choices were discussed with the patient and informed consent was acquired. The treatment plan composed of preservi-

ng the invagination intact and finding the canals and obturated with thermoplasticized gutta percha technique.

Anesthesia was administered by means of an anterior superior alveolar infiltration with 1ml of 2% lignocaine with 1:80,000 adrenaline (Lignox, Indoco Remedies Ltd., India). Consecutive isolation procedures (Hygienic dental dam, Coltene, Whaldent, Switzerland), a conservative access cavity was performed from the palatal aspect with a small round size no-2 bur. Initial access preparation exhibited three orifices (Figure 2b) that were proved by the help of radiograph (Figure 2c). A calcified fourth palatal canal was detectable in the radiograph and was incapable to identify it. All the three canals (2 buccal and 1 palatal) were biomechanical prepared until 20k files (Dentsply, Maillefer) in a step-back approach. During root canal preparation, 3% sodium hypochlorite (NaOCl) was used as the irrigant. The root canals were flushed with saline and dried with sterile paper points. Calcium hydroxide powder (Prime Dental Product, Mumbai, India) was mixed to a creamy consistency with saline, placed in the root canals using a lentulospiral (Dentsply, Maillefer) and sealed with Cavit (3M, ESPE).

To confirm the diagnosis of the existence of a fourth canal and to pinpoint its location, a CBCT scan (Kodak 9000; Carestream Dental, Atlanta) was proposed following an informed consent. A three-dimensional image of tooth #10 was achieved using CS 3D imaging software (Carestream Dental LLC) at a setting of (70 KV of tube voltage and a tube current of 10 mA for 10.8 seconds). The CBCT images disclosed a fourth canal, which was calcified 5mm from the access cavity in palatal location. The invagination was intact on

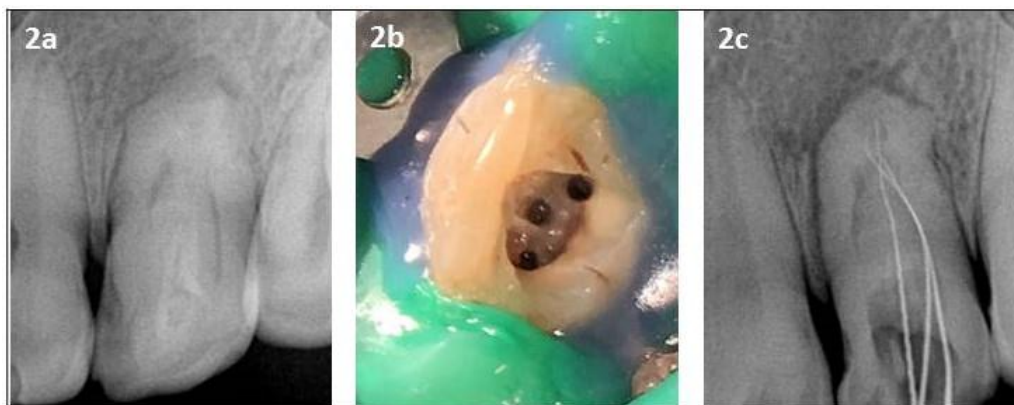


Figure 2a: Pre-operative periapical radiography, **b:** Initial access preparation exhibited three orifices in tooth # 10, **c:** Working length with three canals (2 buccal and 1 palatal)

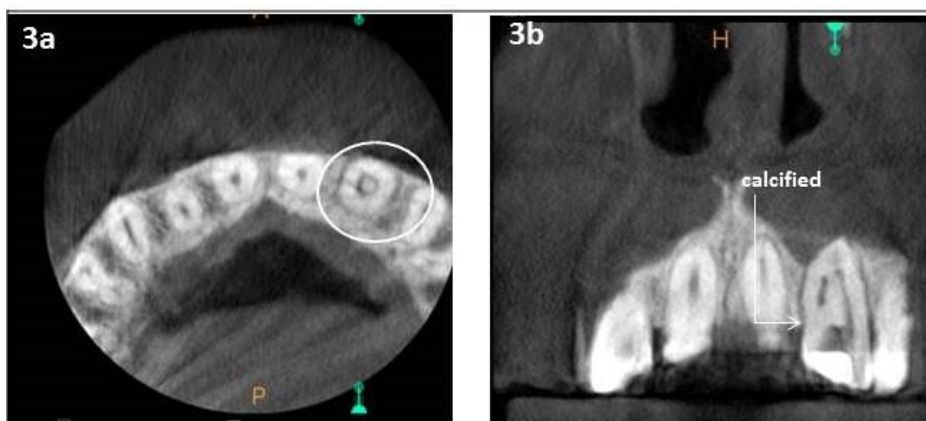

Figure 3a: Pre-operative CBCT (axial view), **b:** sagittal view

the palatal aspect and the major canal partially enclosed the invagination in an O shaped form (Figure 3a, 3b).

In second visit, under rubber dam isolation (Hygienic dental dam Coltene, Whalident, Switzerland), using the CBCT images as the guidance, the fourth (palatal) canal was identified under 6X magnification (Seiler Instrument Inc) following processing of the access cavity using tapered diamond coated ultrasonic tips (Tün Endo Ultrasonics, Engineered Endodontics, WI, USA). Working length was distinguished using an electronic apical foramen locator (Propex pixi, Dentsply) and intraoral periapical radiograph (Figure 4a). The fourth canal was instrumented with size 06, 08, and 10 K-Flexo hand files (Dentsply, Maillefer) in a step-back technique. Cleaning and shaping were performed with HyFlex controlled memory (CM) rotary instruments (Coltene-Whaledent, Switzerland) till #25 6% using 3% Sodium hypochlorite (NaOCl) as the irrigant with the change of each instrument. During the cleaning and shaping procedure, two buccal canals were united. Now all the three canals (1 buccal and 2 palatal) were irrigated with saline and dried with paper points. Root canals

were filled with 3% NaOCl and triggered using a sonic device (Endo-Activator, Dentsply Maillefer) for 30 seconds at 10,000 rpm and the procedure was repeated for 30 seconds after restoring the solution (Figure 4b).

Final irrigation was completed using 17% EDTA (Smear Clear, Kerr Corporation Orange, CA) for 2 minutes. Canals were flushed with saline and a master cone-fit radiograph was obtained (Figure 4c). All the canals were dried using paper points, restored with gutta percha and AH plus sealer (Dentsply, Maillefer) using warm vertical condensation technique (System B, Sybron-Endo) and root canals were back-filled using an injectable gutta-percha technique (Obtura, SybronEndo) (Figure 5a, 5b). A direct bonded composite resin restoration was placed and a post-operative CBCT was advised to confirm the quality of treatment procedures (Figure 6a, 6b). Under asymptomatic conditions porcelain f-used to metal crown was placed after 15days (Figure 5c).

Discussion

Dental anomalies can cause aesthetic and periodontal problems. DI lesions were first described in 1794 after

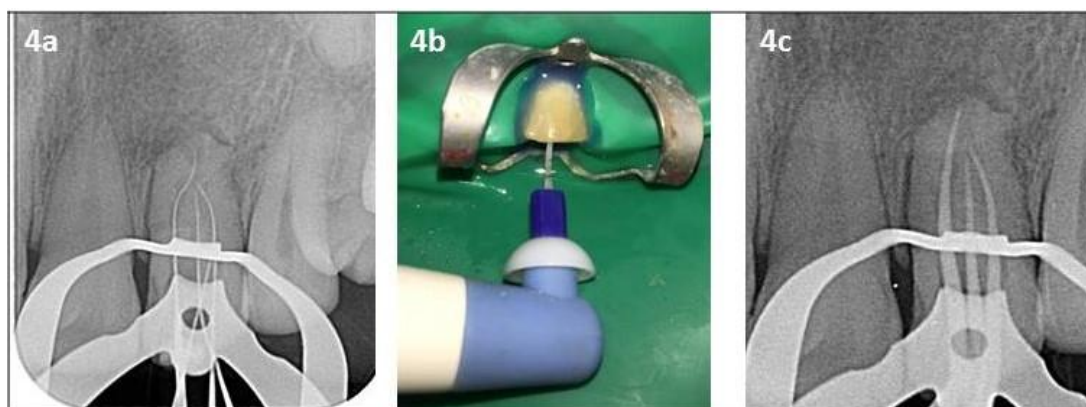


Figure 4a: Working length by periapical radiography confirming 4 canals, **b:** NaOCl agitation with Endoactivator (Dentsply), **c:** Master cone by periapical radiography

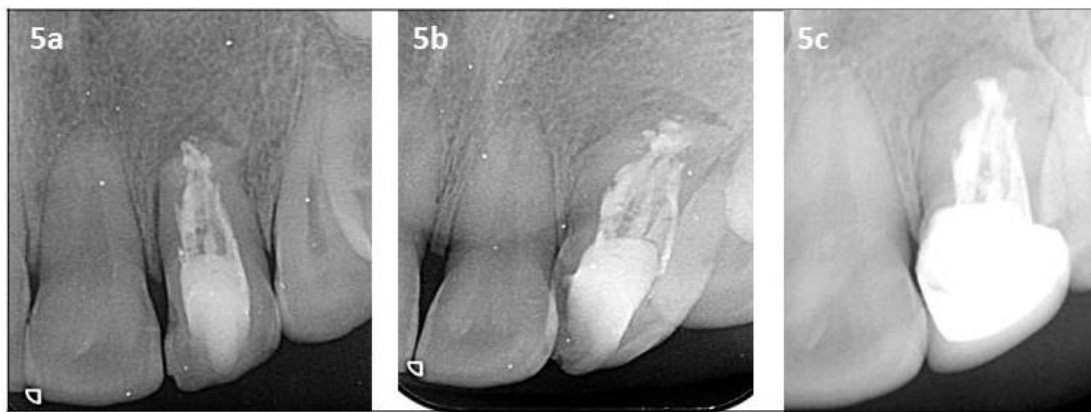

Figure 5a, 5b, 5c: Post-operative periapical radiography with three different angulations

being discovered in the tooth of a whale by Ploquet.[6] A number of different terms have been used to describe the condition including dens in dente, dentoid in dente, invaginated odontome, dilated gestant odontome, and dilated composite odontome and tooth inclusion. DI is often asymptomatic and the crowns of affected teeth may show very little external deformity. If undiagnosed, affected teeth are prone to developing caries and peri-radicular pathology. [6]

Complex anatomical cases such as DI always show a diagnostic and treatment challenge to the dentist. Appropriate treatment plans strictly require complete visualization of the anatomy of root canal. Due to the inherent drawbacks of the two dimensional radiographs, they are unable to reveal the details of the DI three-dimensionally. [7] The introduction of three dimensional CBCT in the 1990s has revolutionized the dental imaging and contributed in a large way to diagnosis and treatment planning of many complex cases. Type, extension, and morphologic changes in the tooth can be showed using CBCT in cases of DI. [4] CBCT uses low effective radiation dose and besides generating un-

distorted 3D reconstruction of the teeth and surrounding soft tissues, provides inter-relational images in three orthogonal planes: axial, sagittal, and coronal. CBCT enables a 3D evaluation of teeth with complex or abnormal root canal anatomy. [8]

In this case report, CBCT enabled a 3D visualization of the abnormal anatomy and showed that the invagination occupied most of the canal. From the axial view the canal dilation can be seen. The coronal view displays the calcification of the canal at the middle third, which clearly depicts the unusual anatomy of the tooth.

Varied treatment options for Oehler’s type III DI have been mentioned in the literature. Each dens invaginatus configuration requires a different approach. Proposed treatment modalities range from periodic observation to prophylactic sealing of the invaginated pit in asymptomatic teeth. In pulpal necrosis, endodontic therapy and root canal of only the invaginated portion or of both the invaginated portion. [9] Both the surgical endodontics and conventional endodontics should be considered especially for large periapical lesions not resolv-

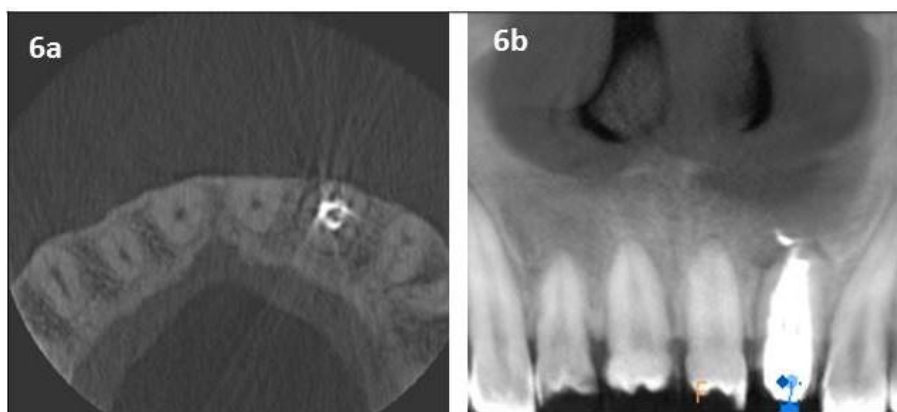


Figure 6a, 6b: Post-operative CBCT axial and sagittal view

ed non-surgically or in cases, which cannot be treated non-surgically because, failure to gain a coronal access. In this case, nonsurgical method was preferred because of good coronal access and not much of periapical pathology. [9]

Exploring the canals is one of the important missions to be accomplished by an endodontist. Much advancement was put forward to affect the task, one of which was ultrasonics that has enhanced the quality of treatment and represents an important adjunct in the treatment of difficult cases. It also aids in refining the access, locating the orifices and calcified canals, and removal of attached pulp stones. Summing up the microscopic visualization with ultrasonic instruments can be the safe and effective combination to achieve optimal results. [10]

With all the methods established, the protest is still to penetrate, reach, and kill bacteria, which are well known to protect themselves from the dentinal mud, their own secretions, and biofilms. Sufficient irrigation and disinfection aids in the success of root canal therapy. In the present case, 3% (NaOCl), 17% (EDTA) were active irrigants. Passive irrigation was done with endo-activator. The Endo-Activator system has been reported to provide inmost penetration of an irrigation solution to all areas of the endodontic space, and vigorously clean debris from lateral canals, remove the smear layer and dislodge clumps of simulated biofilm. [11]

The obturation material was forced in to the surrounding area of the invaginated portion in both middle and apical third of the main canal using subsequent warm compaction technique. It was later observed in the final radiograph and post-operative CBCT.

Conclusion

Accurate preoperative assessment of endodontic architecture is the key to success of endodontic treatment. CBCT, in this case, helped in revealing complex tooth anatomy and calcification, which was not able to appreciate in the conventional radiographs.

Acknowledgment

The authors deny any conflicts of interest related to this study.

Conflict of Interest

The authors disclose no potential conflicts of interest.

References

- [1] Thakur S, Thakur NS, Bramta M, Gupta M. Dens invagination: A review of literature and report of two cases. *J Nat Sci Biol Med.* 2014; 5: 218-221.
- [2] Hülsmann M. Dens invaginatus: aetiology, classification, prevalence, diagnosis, and treatment considerations. *Int Endod J.* 1997; 30: 79-90.
- [3] Oehlers FA. Dens invaginatus II. Associated posterior crown forms and pathogenesis. *Oral Surg Oral Med Oral Pathol.* 1957; 10: 1302–1316.
- [4] Durack C, Patel S. Cone beam computed tomography in endodontics. *Braz Dent J.* 2012;23:179–191.
- [5] Mupparapu M, Singer SR. A review of dens invaginatus (dens in dente) in permanent and primary teeth: report of a case in a microdontic maxillary lateral incisor. *Quintessence Int.* 2006; 37: 125-129.
- [6] Pai SF, Yang SF, Lin LM. Nonsurgical endodontic treatment of dens invaginatus with largeperiradicular lesion: a case report. *J Endod.* 2004; 30: 597-600.
- [7] Jaya R, Mohan Kumar RS, Srinivasan RA. A rare case of dilated invaginated odontome with talon cusp in a permanent maxillary central incisor diagnosed by cone beam computed tomography. *Imaging Sci Dent.* 2013; 43: 209-213.
- [8] Vier-Pelisser FV, Pelisser A, Recuero LC, S6 MV, Borba MG, Figueiredo JA. Use of cone beam computed tomography in the diagnosis, planning and follow up of a type III dens invaginatus case. *Int Endod J.* 2012; 45: 198-208.
- [9] Bishop K, Alani A. Dens invaginatus. Part 2: clinical, radiographic features and management options. *Int Endod J.* 2008; 41: 1137-1154.
- [10] Rampado ME, Tjäderhane L, Friedman S, Hamstra SJ. The benefit of the operating microscope for access cavity preparation by undergraduate students. *J Endod.* 2004; 30: 863-867.
- [11] Arslan D, Guneser MB, Dincer AN, Kustarci A, Er K, Siso SH. Comparison of Smear Layer Removal Ability of QMix with Different Activation Techniques. *J Endod.* 2016; 42: 1279-1285.