

Original Article

Diagnosis of Approximal Caries after Delayed Scanning of Photostimulable Phosphor Plates

Zahra Ghoncheh ¹, Yasaman Kheirandish ², Hanieh Kaviani ¹, Mohammad Javad Kharazi Fard ³, Kurosh Sadeghi ⁴

¹ Dept. of Oral Maxillofacial Radiology, Tehran University of Medical Sciences, International Campus, Tehran, Iran.

² Dept. of Oral Maxillofacial Radiology, Tehran University of Medical Sciences, Tehran, Iran.

³ Epidemiologist, Dental Research Center, Tehran University of Medical Sciences, Tehran, Iran.

⁴ Dentist, Private Practice, Tehran, Iran.

KEY WORDS

Radiography;
Radiography, Dental,
Digital;
Dental Caries;

ABSTRACT

Statement of the Problem: Considering the high diagnostic accuracy and wide dynamic range of photostimulable phosphor plates (PSPs), they can be a good alternative for radiographic films.

Purpose: This study was aimed to assess the effects of delay in scanning PSPs on the diagnostic accuracy of detection of approximal caries.

Materials and Method: Radiographs from fifty-two extracted molar and premolar teeth were radiographed using DIGORA PSP (Soredex Corporation, Helsinki, Finland). The teeth were either intact or with non-cavitated approximal caries. The plates were scanned immediately (time zero) and at 10 min, 30 min, 60 min and 120 min after exposure. Sixty-five images were obtained and evaluated for presence or absence of approximal caries by two oral and maxillofacial radiologists and 2 restorative specialists. The diagnostic accuracy of approximal caries detection was measured using a 5-point rating scale. Definite presence of caries was confirmed using a stereomicroscope. Analysis of caries detection data was performed by calculating sensitivity and specificity using repeated measures with ANOVA.

Results: Significant differences were found in complete negative predictive value, absolute negative predictive value and complete dentine sensitivity value between different scan times ($p < 0.05$). These values were significantly different at 10 min, 60 min and 120 min ($p < 0.05$). However, immediate scan and 30 min delay were not significantly different ($p > 0.05$). The accuracy of approximal caries detection at 120 min was less than at 60 min and at 60 min was less than at 30 min.

Conclusion: In order to detect approximal caries more accurately, DIGORA PSPs should be scanned within 30 min after exposure.

Corresponding Author: Kheirandish Y., Dept. of Oral Radiology, School of Dentistry, Tehran University of Medical Sciences, Tehran, Iran. Tel: +98-2183384260 Fax: +98-2166401132
Email: yasamankhei@yahoo.com

Received May 2016;
Received in revised form October 2016;
Accepted December 2016;

Cite this article as: Ghoncheh Z., Kheirandish Y., Kaviani H., Kharazi Fard MJ., Sadeghi K. Diagnosis of Approximal Caries after Delayed Scanning of Photostimulable Phosphor Plates. J Dent Shiraz Univ Med Sci., 2017 September; 18(3): 201-206.

Introduction

In 1994 DIGORA, digital system designed the first intraoral storage phosphor system and since then, it has been extensively used in the clinical setting. [1-2] photostimulable phosphor plates (PSPs) usually have the same size and flexibility as radiographic films. Considering their high diagnostic accuracy and wide dynamic

range, they can be a good alternative for radiographic films. [3-4] Studies comparing PSPs charge-coupled devices (CCD) and conventional film bases have reported that PSPs have image quality equal or higher than that of other devices. [5-7]

Longer processing time and lower image quality after light exposure to plates are among the most im-

portant disadvantages of optical plate systems. [8-9] It has been suggested that plates have to be processed as soon as possible after the exposure because trapped electrons are spontaneously released over time causing subsequent reduction in image quality and lower diagnostic accuracy in the clinical setting. [10-11] However, in the clinical setting, immediate scanning of PSPs is not usually feasible and a delay exists between the exposure time and scanning. For instance, a time interval exists between the first and last periapical radiographs taken when patients need a series of full mouth radiographs. [12] Numerous studies have investigated the consequences of delay in plates scanning. [5, 8-9, 11-12] These studies have mostly investigated the storage conditions of plates in addition to delay and have mostly focused on detection of tooth structures (enamel, dentine, pulp, periodontal ligament space, lamina dura and trabecular pattern). No data is available on the effect of delay on the accuracy of the diagnosis of pathologic conditions particularly approximal caries. This study was aimed to assess the effect of delayed scanning of PSPs on detection of approximal caries.

Materials and Method

Fifty-two extracted human teeth were evaluated, out of which, 26 were premolars and 26 were molars. The teeth were either intact or had non-cavitated approximal caries. Cavitated and restored teeth were not included. All samples were obtained from dental centers in which the teeth were extracted due to specific reasons rather than current study objectives.




Figure 1a: Photostimulable phosphor plate, **b:** Mounted teeth, **c:** Soft tissue simulator, **d:** Radiography tube

The test teeth were mounted into wax blocks and thirteen blocks were prepared, each containing 2 premolar and 2 molar teeth. The approximal surfaces of teeth

were positioned next to one another to simulate natural contact points. (Figure 1)

In total, six approximal surfaces were evaluated in each block. In the first and last teeth of the row in each block, only the surface in contact with the adjacent tooth was evaluated. (Figure 2)

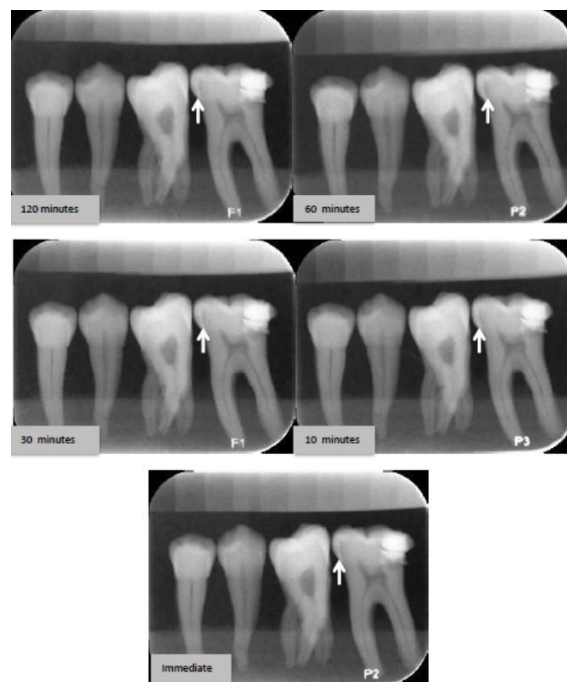


Figure 2: Images obtained from the scanning of PSPs immediately after exposure or at different time points. Arrows indicate approximal caries

In order to ensure the reproducibility of the image geometry, a setting was used allowing the fixed position of radiation source, object and the PSP. Digital images were obtained using bitewing technique. All radiographs were taken using MINRAY® device (Soredex, Nahkelantie 160, Finland) with the exposure setting of 70 kVp voltage, 7mA, 2.0mm aluminum (Al) equivalent filtration, at a source-receptor distance of 45 cm and 0.1 s exposure time.

In order to simulate the soft tissue absorption of radiation, an acrylic block (polymethyl methacrylate) measuring 15cm x15cm with 4 cm thickness was placed between the X-ray tube and the block. [13]

Size 2 PSPs, measuring 30.0 mm x 40.0 mm were scanned using Soredex DIGORA Optime scanner (Helsinki, Finland) with standard resolution. Scanned images were saved in a computer as digital imaging and communications in medicine (DICOM) files.

Before the exposure, any previous data on PSPs were deleted using the strong light source incorporated

into the scanner. By doing so, any previous memory on the plates was deleted. Each block was radiographed and PSPs were scanned immediately after exposure (to avoid any possible effects of time delay on storage) and 10 min, 30 min, 60 min and 120 min after exposure. Plates, not immediately scanned, were stored in a light-tight box until scanning.

Two oral and maxillofacial radiologists and two restorative specialists evaluated 65 images and 390 approximal surfaces (13 blocks \times 6 surfaces in each block \times 5 times exposure) for presence or absence of approximal caries using a 5- point scale as follows:

1. Definitely no caries
2. Probably no caries
3. I am not sure
4. Probable carious lesion
5. Definite carious lesion

Observation conditions were the same for all observers. The observers viewed the images on a 19-inch monitor (Samsung SyncMaster) and a display resolution of 768 x 1360 in a dimly lit room with 45 cm distance. Images were saved by SCANORA Lite software in DICOM format. All images were shown randomly, using simple randomization presented by Microsoft Excel software. Observation of images was done in three separate sessions. In order to decrease tiredness and reduce the chance of over-thinking the previous diagnoses, one-week time interval was allowed between the observation sessions. After completion of the primary assessment, images were assessed again after a one-week interval. Observers were allowed to change the density and contrast as desired. No time limit was set for the observers.

In order to confirm the presence of caries, the teeth were sectioned individually and serially in the mesiodistal direction using an IsoMet saw (CNC; Nemo Fanavaran Pars, Mashhad, Iran) with a disc thickness of 40 μ (0.4mm). Teeth sections were fixed on slides, evaluated under a stereomicroscope (Olympus, SZX10) at 15 X magnification, and scored as follows:

Zero: Intact

One: Enamel caries

Two: Dentine caries

Teeth with demineralization and brown or opaque-white discoloration in an approximal area were scored based on the penetration depth of lesion into enamel (1) or dentine (2). The deepest penetration depth

measured on the slide was recorded as the caries penetration depth.

Data analysis

Caries detection data were analyzed by calculating absolute/definite sensitivity and specificity values. In this study, absolute sensitivity/specificity was defined as the number of definitely correct diagnoses. Moreover, complete sensitivity/ specificity was defined as total number of definite and probably correct diagnoses. The positive value (PPV) and negative predictive value (NPV) were also reported as an axillary finding. In order to compare sensitivity and specificity, repeated measures ANOVA was used. If the difference between indices was significant, ($p < 0.05$) pairwise comparison was carried out using LSD test. LSD is a famous post hoc test for ANOVA models, which is based on the lowest significant differences. Statistical analyses were performed using SPSS version 20 software.

Results

Of 52 teeth that were intact, or had non-cavitated approximal caries, 26 were molars and 26 were premolars. Seventy-eight approximal surfaces were evaluated. Histologic examination, as the gold standard for diagnosis, revealed that 47 surfaces (60.3%) were intact (no caries), 11 (14.1%) had enamel and 20 (25.6%) had dentine caries.

The mean and standard deviation of diagnostic indices at different times of scanning and two times evaluation by the four observers are shown in Table 1.

In current study, NPV and PPV were calculated using sensitivity and specificity values and are only collateral findings.

In *in vitro* studies, in which real positive and negative ratios are predefined and are not based on prevalence comparison of PPV and NPV, have no advantage to comparison of sensitivity and specificity.

Based on statistical analyses, significant differences existed in complete NPV at different time points ($p < 0.001$). The diagnosis at time zero (immediate scanning of plates) was significantly different from 60 min ($p = 0.01$) and 120 min ($p = 0.02$). However, no significant difference was found between scanning at 10 min and 30 min ($p > 0.05$). The difference between scanning at 10 min and 60 min ($p = 0.007$) and 120 min ($p = 0.001$) was significant but no difference was found bet-

Table 1: The mean and standard deviation of diagnostic incidence for enamel and dentine approximal caries, in different delayed scanning times

Time	0	10	30	60	120	p Value
Absolut specificity	71.28±23.15	69.96±28.45	65.95±33.18	66.22±28.89	64.61±30.09	0.988
Complete specificity	94.26±4.53	92.61±6.63	89.08±11.96	88.30±10.63	84.75±12.47	0.338
Sensitivity enamel Absolute	7.96±13.26	5.68±9.65	7.96±13.26	6.82±12.63	3.41±6.77	0.924
Sensitivity enamel Complete	30.68±27.06	31.95±23.20	23.88±26.16	21.72±20.80	12.51±18.15	0.473
Sensitivity dentin Absolute	41.88±13.07	40.00±9.63	38.75±12.17	32.50±10.35	33.13±10.99	0.369
Sensitivity dentin Complete	80.63±13.21	76.88±11.31	68.13±16.68	62.50±11.65	56.25±16.85	0.009
Absolute NPV ¹	93.53±5.81	92.20±3.74	90.15±5.38	88.55±5.35	85.30±3.60	0.016
Complete NPV	0.88±0.05	0.88±0.04	0.84±0.03	0.80±0.02	0.79±0.04	0.000
Absolute PPV ²	0.98±0.03	0.98±0.03	0.98±0.03	1.00	0.98±0.04	0.817
Complete PPV	0.96±0.03	0.97±0.05	0.94±0.09	0.93±0.09	0.92±0.09	0.699

¹ Negative Predictive Value² Positive Predictive Value

wen immediate scanning and 30 min delay ($p > 0.05$).

Absolute NPV was significantly different at different scanning times as well ($p = 0.016$). The difference between time zero and 120 min was significant ($p = 0.014$). No significant difference was found between other time points ($p > 0.05$).

No significant difference was found between different time points in absolute specificity ($p = 0.988$) and complete specificity ($p = 0.338$).

No significant difference was found between different time points in absolute enamel sensitivity ($p = 0.924$) and complete enamel sensitivity ($p = 0.473$).

No significant difference was detected between different time points in absolute dentine sensitivity ($p = 0.369$).

Complete dentine sensitivity was significantly different at different scanning times ($p = 0.009$). The difference in this respect between time zero and 120 min ($p = 0.01$) and at 10 min and 120 min ($p = 0.04$) was significant.

No significant difference was found in absolute PPV ($p = 0.817$) or complete PPV ($p = 0.699$) at different time points. Although this study was not designed for intra- and inter-observer agreement, they were obtained as an additional finding and Kappa coefficient was more than 0.6.

Discussion

Based on the results, no change occurred in caries detection by up to 30 min delay in scanning of DIGORA Optime PSPs. However, delay for more than 30 min caused a significant reduction in the quality of images. This finding was compatible with the results of Sogur *et al.* [5] Delay for 10 min had significant difference with

delay for 60 min and 120 min but no difference was found between immediate scanning and 30 min delay. Thus, it can be concluded that 120 min delay in scanning, significantly decreased the accuracy of detection of approximal caries and the reduction in diagnostic accuracy at 120 min was greater than 60 min and 60 min was greater than 30 min delay.

Based on the results, up to 30 min delay in scanning of plates had no effect on detection of approximal caries. This finding was in agreement with the results of Sogur *et al.* [5] They evaluated the effect of delay in scanning at zero min, 10 min, 30 min, 60 min and 120 min time points, detecting the occlusal caries in extracted molar teeth. They reported delay in scanning for up to 30 min had no effect on the accuracy of detection of occlusal caries. [5]

Bramante *et al.* [8] evaluated image quality following delayed scanning for 5 min, 60 min and 120 min and demonstrated a lower image quality after 120 min delay. The difference between the current study and Bramante *et al.*'s study results might be due to the evaluation of delay in scanning of PSPs with transparent and opaque covers that affect contrast, resolution and brightness of tooth structures (enamel, dentine, root, pulp) and periodontal structures (periodontal ligament, cortical bone, alveolar bone). In our study, only the effect of delay in scanning was investigated.

Martins *et al.* [1] evaluated the effect of 10 min and 30 min and 1 h, 2 h, 3 h and 4 h delay on reduction of pixel density and reported this reduction after 4 h of delay. Such delay had no effect on clinical diagnosis. The difference between our results and those of Martin *et al.*'s may be due to the storage conditions of plates (environmental temperature, storage in a refrigerator,

and low humidity) that affect the quality of image of anatomic structures namely enamel, dentine, pulp, periodontal ligament, lamina dura, and trabecular pattern of bone. [1]

Martins *et al.* [14] also evaluated the effect of 6 h, 12 h, 14 h, 18 h, 48 h and 72 h delay on the pixel density and reported a change in pixel density at 6 h. This result was not in agreement with our finding. The reason for this difference may be the fact that Martins *et al.* evaluated the effect of storage conditions of sensors while we only evaluated the effect of time. [14]

This study was in agreement with that of Sogur *et al.* [5] The difference between our results and those of other studies may be due to the storage conditions. In our study, storage condition of all specimens was matched and they were all kept in a light-tight box. In addition, previous studies only assessed the detection of lesions by the observers instead of using a five-point scale. Even those using such a scale often combined the definite and probable diagnoses for final statistical analyses while in our study, definite and probable diagnoses were analyzed and reported separately.

Our study showed decreased diagnostic accuracy for detection of approximal caries after 30 minute- delay in scanning and we may conclude that such a delay may significantly have an impact on the clinical outcome.

In conclusion, it is recommended that the plates should be scanned immediately after exposure in order to prevent a decrease in their quality. Delay less than 30 minutes will not have a significant impact on the accuracy of detection of approximal caries. In case of delay longer than 30min, even if stored in a light-tight box, the image will not be reliable enough for detection of approximal caries.

Conclusion

As the first study to assess the effects of delay in scanning PSPs on the diagnostic accuracy of detection of approximal caries in the enamel and dentine, the results showed that the difference in the mean complete sensitivity for detection of dentine caries was significant between time zero and 10 min with 120 min. However, the difference in the mean definite dentine sensitivity was not significant. The difference in the mean definite and complete sensitivity for enamel was not significant either. It seems that the diagnostic sensitivity for enamel

lesions is also low in immediate scanning; indicating that radiography usually underestimates the extension of enamel caries. In order to detect approximal caries more accurately, DIGORA PSPs should be scanned within 30 minutes after exposure.

Acknowledgements

This study was supported by deputy dean of faculty of dentistry, Tehran University of Medical Sciences, International Campus. The authors thank for their support.

Conflict of Interest

There is no conflict of interest to declare.

References

- [1] Martins MG, Whaites EJ, Ambrosano GM, Haiter Neto F. What happens if you delay scanning Digora phosphor storage plates (PSPs) for up to 4 hours? *Dentomaxillofac Radiol.* 2006; 35: 143-146.
- [2] Oliveira AE, de Almeida SM, Paganini GA, Haiter Neto F, Bóscolo FN. Comparative study of two digital radiographic storage phosphor systems. *Braz Dent J.* 2000; 11: 111-116.
- [3] Berkhout WE, Beuger DA, Sanderink GC, van der Stelt PF. The dynamic range of digital radiographic systems: dose reduction or risk of overexposure? *Dentomaxillofac Radiol.* 2004; 33: 1-5.
- [4] Farman AG, Farman TT. A comparison of 18 different x-ray detectors currently used in dentistry. *Oral Surg Oral Med Oral Pathol Oral Radiol Endod.* 2005; 99: 485-489.
- [5] Sogur E, Baksi BG, Mert A. The effect of delayed scanning of storage phosphor plates on occlusal caries detection. *Dentomaxillofac Radiol.* 2012; 41: 309-315.
- [6] de Almeida SM, de Oliveira AE, Ferreira RI, Bóscolo FN. Image quality in digital radiographic systems. *Braz Dent J.* 2003; 14: 136-141.
- [7] Borg E, Attaelmanan A, Gröndahl HG. Subjective image quality of solid-state and photostimulable phosphor systems for digital intra-oral radiography. *Dentomaxillofac Radiol.* 2000; 29: 70-75.
- [8] Bramante CM, Bramante AS, de Souza RE, Moraes IG, Bernardineli N, Garcia RB. Evaluation of the effects of processing delays and protective plastic cases on image quality of a photostimulable phosphor plate system. *J Appl Oral Sci.* 2008; 16: 350-354.

- [9] Akdeniz BG, Gröndahl HG, Kose T. Effect of delayed scanning of storage phosphor plates. *Oral Surg Oral Med Oral Pathol Oral Radiol Endod.* 2005; 99: 603-607.
- [10] Pharoah M, White S. *Oral radiology: principles and interpretation.* 7th ed. St. Louis, Mo.: Mosby; 2009. p. 78-84.
- [11] Akdeniz BG, Gröndahl HG. Degradation of storage phosphor images due to scanning delay. *Dentomaxillofac Radiol.* 2006; 35: 74-77.
- [12] Ang DB, Angelopoulos C, Katz JO. How does signal fade on photo-stimulable storage phosphor imaging plates when scanned with a delay and what is the effect on image quality? *Oral Surg Oral Med Oral Pathol Oral Radiol Endod.* 2006; 102: 673-679.
- [13] Caldas Mde P, Ramos-Perez FM, de Al-meida SM, Haiter-Neto F. Comparative evaluation among different materials to replace soft tissue in oral radiology studies. *J Appl Oral Sci.* 2010; 18: 264-267.
- [14] Martins MG, Haiter Neto F, Whaites EJ. Analysis of digital images acquired using different phosphor storage plates (PSPs) subjected to varying reading times and storage conditions. *Dentomaxillofac Radiol.* 2003; 32: 186-190.