

Original Article

Evaluation of the Effects of Three Plant Species (*Myrtus Communis L.*, *Camellia Sinensis L.*, *Zataria Multiflora Boiss.*) on the Healing Process of Intraoral Ulcers in Rats

Maryam Alsadat Hashemipour¹, Sodabeh Lotfi², Molok Torabi³, Fariba Sharifi⁴, Mehdi Ansari⁴, Amirreza Ghassemi⁵, Saied Sheikshoae⁶

¹ Oral and Dental Disease Research Center and Dept. of Oral Medicine, School of Dentistry, Kerman University of Medical Sciences, Kerman, Iran.

² Kerman Social Determinants on Oral Health Research Center and Dept. of Oral Medicine, School of Dentistry, Kerman University of Medical Sciences, Kerman, Iran.

³ Dept. of Oral and Maxillofacial Pathology, Kerman University of Medical Sciences, Kerman, Iran.

⁴ Dept. of Pharmaceutics, Kerman University of Medical Sciences, Kerman, Iran.

⁵ Periodontic Resident, Saint Louis University, Saint Louis, MO, United States.

⁶ Neuroscience Research Center, Kerman University of Medical Sciences, Kerman, Iran.

KEY WORDS

Ulcer;
Mouth;
Wound;
Healing;
Plant;

Received July 2016;
Received in Revised form October 2016;
Accepted December 2016;

ABSTRACT

Statement of the Problem: Use of traditional medicine to relieve human sufferings has a very long history. The effects of these plants in wound curing and subsequently making the best mucosa patch for treatment of oral ulcers is still under investigation.

Purpose: The main goal of present research work is to assess the efficacy of *Myrtus communis L.*, *Camellia sinensis L.* and *Zataria multiflora Boiss.* on oral ulcer recovery process in rats.

Materials and Method: In this study, 60 healthy adult male rats in 5 groups were investigated. A wound with 2 mm diameter was punched into the hard palate of each rat. For topical application, a mucosa patch of materials or blank was packed into the wound. Histological samples were harvested on post injury days 2, 4, 6, and 8.

Results: This study showed that there were no significant differences between groups in the reduction of weight. Comparison of clinical wound size showed that group *Myrtus communis L.* had the greatest reduction in wound size on days 4, 6 and 8, which was significantly different from the other groups. The highest thickness of epithelium was observed in groups *Myrtus communis L.* and *Camellia sinensis L.* on days 6 and 8. Group *Myrtus communis L.* showed the highest values on days 6 and 8. This study showed a lower mononuclear cell counts in group *Myrtus communis L.* on days 6 and 8 compared to other groups which was statistically significant.

Conclusion: The results of the present study showed that *Myrtus communis L.* has significant effects on oral wound healing processes. These favorable results might introduce a new group of material or medicine derived from this plant.

Corresponding Author: Hashemipour MA., Dept. of Oral Medicine, School of Dentistry, Kerman University of Medical Sciences, Kerman, Iran. Tel: +98-412118074 Fax: +98-3412118073 Email: m.s.hashemipour@gmail.com, m_hashemipoor@kmu.ac.ir

Cite this article as: Hashemipour MA., Lotfi S., Torabi M., Sharifi F., Ansari M., Ghassemi A., Sheikshoae S. Evaluation of the Effects of Three Plant Species (*Myrtus Communis L.*, *Camellia Sinensis L.*, *Zataria Multiflora Boiss.*) on the Healing Process of Intraoral Ulcers in Rats. *J Dent Shiraz Univ Med Sci.*, 2017 June; 18(2): 127-135.

Introduction

Traditional medicine has been used to relieve human sufferings for a very long period of time and is still one of the most inspiring sources of providing medicines. [1-2] Recently, the use of herbal medicines has in-

creased markedly by patients who seek traditional treatment modalities and has been approved by patients and physicians. [3-4] There are several factors that affect patients' tendency to use traditional medicine including easy access and patients' interest in self-

treatment. Also, on this subject, one can recall to the belief of patients that traditional treatments are safer, more reliable, and cheaper than conventional medications. [5]

A large number of herbal preparations are introduced for the treatment of various medical conditions including dermatologic conditions. The use of herbal medicines in the treatment of skin conditions, including ulcerations, wounds, and burns, has become common regarding research studies and confirmation of their efficacy. [6-15]

The aim of the present study was to evaluate the effect of three plant-derived medicines (top aerial branches of *Zataria multiflora Boiss.* from the family of *Lamiaceae*, Branches of *Myrtus communis L.* from the *Myrtaceae* family, and leaves of *Camellia sinensis L.* from the family of *Theaceae*) on wound healing process in rats' oral cavity.

Myrtus communis has traditionally been used as an antiseptic and disinfectant and as an antihypertensive agent. It has attracted a lot of attention for a long time due to its anti-inflammatory, antiviral, antiseptic and disinfecting properties. Its fruit is used as an antiseptic, astringent, [16] anti-flatulent, [16-18] analgesic, diuretic, [17, 19-20] anti-inflammatory [21] and anti-diabetic agent. [22]

Green tea is known as one of the most common drinks, with antineoplastic and antioxidative properties. [23] In ancient China and South East of Asia, green tea was used as an herbal medicine for the treatment of diabetes. [24-25] It has a wide range of food value and a broad spectrum of therapeutic applications in decreasing blood glucose and lipid levels, blood pressure, incidence of cardiovascular diseases and cardiac rhythm. It also has anticoagulative, and anti-HIV properties, and causes an increase in the non-specific immunity of the body. [26-27]

Z. multiflora belongs to the *Labiatae* family and is indigenous to Iran. The medicinal parts of this plant are its top branches and its dried leaves. This plant has a high antioxidative property comparable to that of ascorbic acid, butylated hydroxytoluene (BHT) and vitamin E. In addition, its anti-proliferative and anti-tumoral effects have been reported on various cell lines. [28-29]

In the present study, three types of plants are chosen because they grow in all parts of Iran and are

available easily. Furthermore, their benefits in treatment skin and stomach wounds are proven according to different several studies. [7-10] So, in the present study, an attempt is made for investigating the effects of these plants in wound curing. It is worth mentioning that the present investigation is continuously doing on other plants, and the main goal is making the best mucosa patch for treatment of oral ulcers.

Materials and Method

In this study, the procedures of all steps were based on international protocols for animal care under the supervision of the Ethics Committee of Medical Kerman University (#256.93.k)

Leaves and stems of *Zataria multiflora Boiss.* stems and seed of *Myrtus communis L.* and leaves of *Camellia sinensis L.* are collected in spring and summer.

In the present research work, an attempt was made to investigate the authentication of herbal materials according to macroscopic and microscopic examinations. Macroscopic examination involved the comparison of morphological characters that are visible with the naked eye or under low magnification with descriptions of the plant or botanical drug in floras or monographs. Characters such as size, shape and color of leaves (or leaf fragments), and also flowers or fruits are commonly used in macroscopic identification. Microscopic examination is focused on anatomical structures in the plant material that are visible only with the help of a microscope such as trichome (hair) shape and structure, the arrangement of stomata in the epidermis, the presence or absence of compounds such as mucilage, starch or lignin, or the presence of tissues with characteristic cells. The plant was collected from Kerman (Baft, Iran), dried in shade, and powdered by mechanical grinder. The voucher samples were preserved for reference in the Herbarium of Pharmacognosy Department, School of Pharmacy, Kerman University of Medical Sciences, Kerman, Iran.

The plant powder was extracted using aqueous infusion and maceration with ethanol. For the aqueous infusion, 1000 ml of hot water was added to 100 g leaves powder, boiled for 15 min, and filtered through cloth. For ethanolic extraction, the plant powder was macerated in 500 ml ethanol (80%,v/v) for 72h and the mixture was subsequently filtered and concentrated in

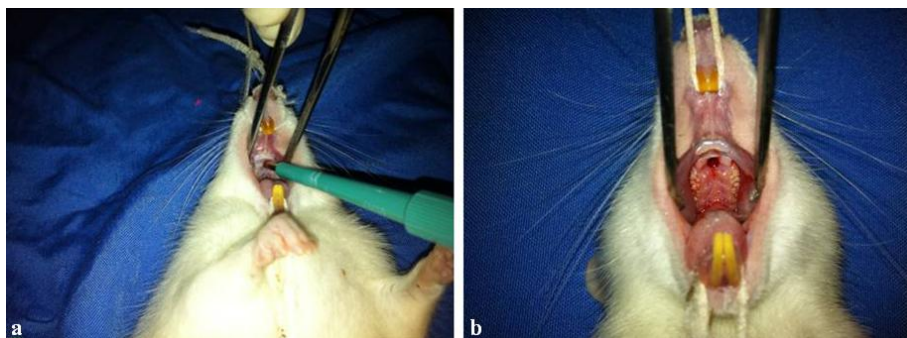


Figure 1a and b: A #2 punch which was used to create a wound in the hard palate in the oral cavity, measuring 2x2 mm, with a depth of 2-3 mm; to include whole epithelium and the connective tissue

vacuum at 40°C. By distillation technique, the extracts were concentrated in vacuum and stored at -20° C. [11]

A total of 60 healthy white Sprague-Dawley rats weighing 250-300 g were selected in this study. The animals were randomly divided into 5 groups of 12. 12 rats were placed in the control group and 48 rats were equally divided into *Z. multiflora*, *M. communis*, *C. sinensis* and the basic material groups.

The animals were kept in a well ventilated room at the animal laboratory of the Neuroscience Research Center, while the temperature and moisture were under control. A standard 12-hour cycle of day and night was established in the room. Standard food and water were provided for these rodents with equal dietary conditions for all the animals.

The hand and legs of the animals were tied to the dissection table and a buckle-shaped clamp was fastened on the upper incisor tooth to keep the mouth open. The animals were divided into 5 groups of 12 and numbered. The animals in each group were kept in separate cages, while the food regime was the same for all the animals, with consumption of soft food stuffs.

On the first day, all the 60 animals underwent a general anesthesia procedure with ketamine at a dose of 60 mg/kg and Xylazine (Rompun®), as a muscle relaxing agent at a dose of 7.5 mg/kg. A #2 punch was used to create a wound in the hard palate in the oral cavity, measuring 2x2 mm, with a depth of 2-3 mm; therefore, the wound included the whole epithelium and the connective tissue, (Figure 1). [30] After controlling hemorrhage and the formation of a clot, the animals were divided into 5 groups of 16, including group C in which animals did not receive any medication, group Z in which the animals received the methanolic extract of *Z. multiflora*., group M in which the animals received the

methanolic extract of *M. communis*., group CS in which the animals received the methanolic extract of *C. sinensis*. and group B in which the animals received the basic material.

In the present study, materials were prepared in the form of mucous patch. The medications were placed on the wounds at certain concentrations and volumes in 48 animals and the remaining 12 animals were considered as the controls (group C). Mucosa patch was used one time daily during eight days. All the animals were weighed every day using an accurate weighing machine. [31] The wounds were clinically evaluated during the whole period of study (8 days) before re-administration of medications. The animal underwent a general anesthesia procedure every day and the depth and width of the ulcers were measured using slide calipers, [32-33] by an operator who was blinded to animal groupings.

Three animals from each group were euthanized on days 2, 4, 6 and 8, [32-33] respectively by using ether. Each wound was removed by a #5 punch, a periosteum elevator and a scalpel blade, consisting of adjacent muscles and 1 mm of the healthy peripheral tissues and fixed in 10% formalin. The samples were sent to the pathology laboratory. They were embedded in paraffin, stained with H&E and evaluated by a pathologist blinded to the status of each sample. The histopathologic criterion for the evaluation of wounds was tissue inflammation (Table 1).

In addition, the wounds were histopathologically graded from 1 to 5 for re-epithelialization (Table 2). [34] Two-way ANOVA was used to compare mean wound sizes, the maximum ulcer diameter, animal weights in different groups and re-epithelialization degree. The criteria $p < 0.05$ was considered significant, and the statistical analysis was performed by the SPSS 21 software.

Table 1: Histopathological scores to evaluate inflammation

0	No acute inflammation
1	Perivascular scattered acute inflammatory cells
2	Perivascular and submucosal scattered acute inflammatory cells
3	Submucosal band-like inflammatory infiltrate, less than ¼ of one power field
4	Submucosal band-like inflammatory infiltrate, between ¼ and ½ of one power field without tissue necrosis
5	Submucosal band-like inflammatory infiltrate, more than ½ of one power field with tissue necrosis

Table 2: Histopathological grading to evaluate re-epithelialization

1	Re-epithelialization at the edge of the wound
2	Re-epithelialization covering less than half of the wound
3	Re-epithelialization covering more than half of the wound
4	Re-epithelialization covering the entire wound, irregular thickness
5	Re-epithelialization covering the entire wound, normal

Results

The average weights of the animals in the 5 groups (M, CS, Z, B, and C) at the beginning of the study were 220, 215, 222, 218, and 225 g, and after 4 days with oral ulcer were decreased to 215, 205, 209, 210, and 220 g, respectively. There were no significant differences between groups in the reduction of weight ($p > 0.05$). Comparison of clinical wound size showed that group M had the greatest reduction in wound size on days 4, 6 and 8, which was significantly different from the other groups ($p < 0.05$) (Figure 2).

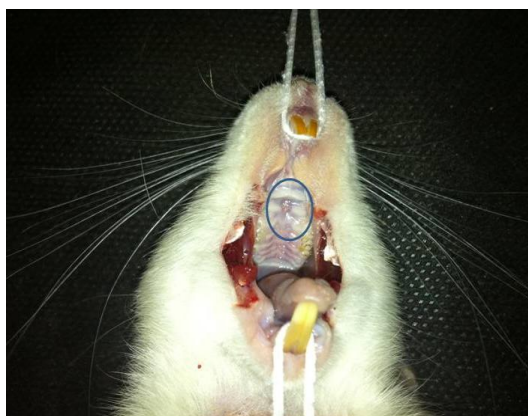

Figure 2: Clinical photographic of the palate wound that showed healing of the wound in the group M.

In relation to the residual wound area, group M showed the lowest values among all the treatment groups at all the intervals ($p < 0.05$). Furthermore, clinical examination of the wounds in groups M and CS showed gradual healing over time in all the groups. Slow wound healing was observed on days 3 and 4 days

postoperatively. Macroscopically, bone was covered with a sero fibrinous layer. Margins of the wound became irregular and started to migrate towards the center of the wound. The area of fibrin covering the base of the wound decreased rapidly from day 3 to day 4. On the day 4, the defect was largely covered with epithelium. At the end of experiment (day 8), most of the defects were healed with minimal central depression.

The highest thickness of epithelium was observed in groups M and CS on days 6 and 8, which was significantly different from the other groups ($p < 0.05$). In addition, group C had the lowest thickness of epithelium, which was significantly different from the other groups at all the intervals ($p < 0.05$) (Figure 3 and 4).

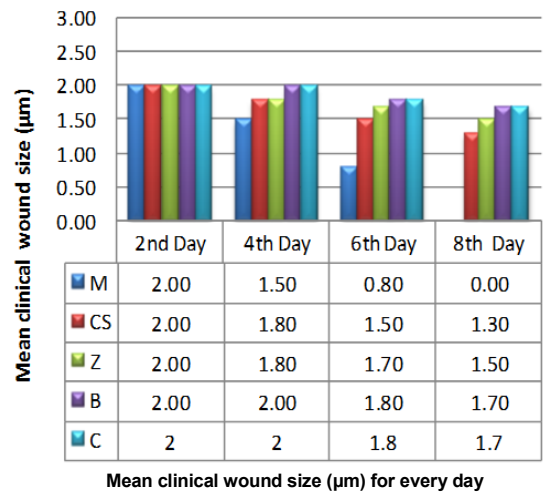


Figure 3: Mean clinical wound size (µm) during the period of experiments

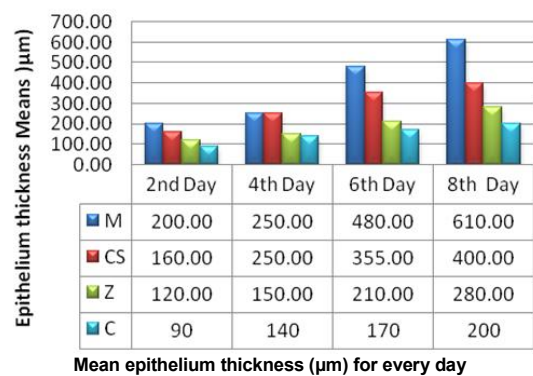


Figure 4: Mean epithelium thickness (µm) during the period of experiments.

In groups C and B, the inflammation score was highest at all the intervals, and a significant difference was observed between the groups ($p < 0.05$), while groups M and CS showed the lowest values on days 2, 4, 6, and 8, with a significant difference between the groups ($p < 0.05$) (Figure 5).

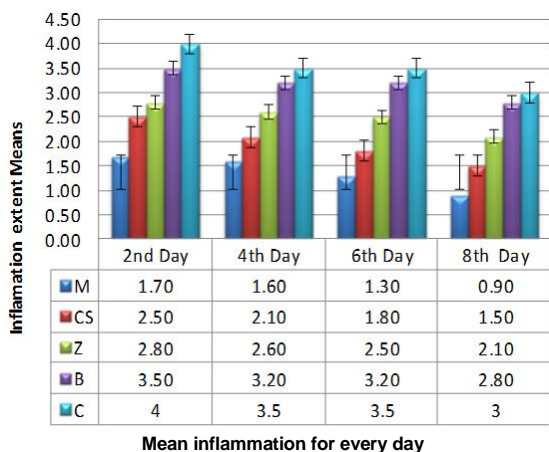


Figure 5: Mean inflammation during the period of experiments.

There were significant differences between re-epithelialization results. Group M showed the highest values on days 6 and 8 ($p < 0.05$), while the groups C and B showed the lowest values at all the intervals (Figure 6). According to two-way ANOVA, a higher count of polymorphonuclear cells (PMNs) was observed on days 2 and 4 in groups Z, B and C, with significant differences from groups M and CS ($p < 0.05$). A lower score was observed in group M at all the intervals, with significant differences from other groups ($p < 0.05$).

This study showed a lower mononuclear cell counts in group M on days 6 and 8 compared to others, which was statistically significant; the counts were lower in groups Z, B and C on days 2; while, the difference was not significant ($p < 0.05$).

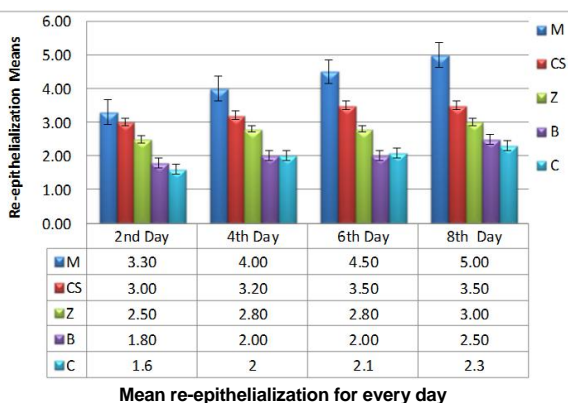
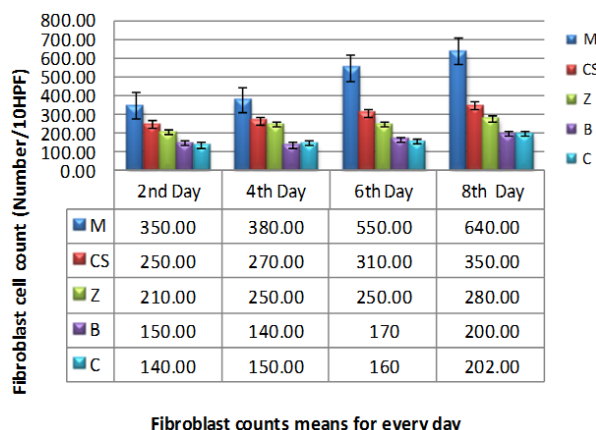


Figure 6: Mean re-epithelialization during the period of experiments

Group M showed the highest values of fibroblast counts at all the intervals, and a significant difference was observed between the groups ($p < 0.05$) (Figure 7).

Discussion

Wounds are common conditions of the oral cavity, affli-



Fibroblast counts means for every day

Figure 7: Fibroblast counts (Number/10HPF) during the period of experiments

cting 12-20% of the population. [35] A large number of chemical compounds used for healing of oral ulcers and wounds after oral surgeries have been evaluated. Maintaining a high level of oral hygiene and plaque control determine the success of oral cavity surgeries, [36] which is especially important in the case of some specific wounds such as wounds induced in the palate for free graft of soft tissues, in which a large amount of tissue is lost; because they go through secondary intention healing process. [37]

The results of this study showed that *M. communis* has the greatest effect on wound healing process. This plant resulted in a decrease in neutrophil counts and an increase in the number of fibroblasts and improved epithelialization process. *C. sinensis*, *Z. multiflora* ranked second to third in relation to their effect on wound healing. Studies by Sharififar *et al.* [7-10] and Hosseinzadeh *et al.* [11] have shown the strong anti-inflammatory, antioxidative and antibacterial properties of these plants and in some cases they can have significant effects on wound healing.

Essential oils of *M. communis* leaves are used in France as an antiseptic. In addition, they have been used in hospitals in Paris in respiratory and certain urinary bladder conditions and have been recommended for local procedures in local conditions. [38-41] Its fruit has been used in diarrhea, dysentery, internal wounds, rheumatism, [38-39] foot ulcers, malodorous wounds, aphthous stomatitis, sinusitis, hair loss, bleeding, bronchitis, etc. [42] The antimicrobial and antioxidant properties of compounds produced by *M. communis* have been reported in some studies. [43-44] *M. communis* L. extracts profile constitutes polyphenolic compounds

phenolic acids, tannins and flavonoids. Some results have indicated that phenolic compounds significantly contributed to the wound healing. [43] This activity may be attributed to the enzyme inhibition by the more oxidized phenolic compounds possibly through reaction with sulfhydryl compounds or through more non-specific interactions with the protein. [44]

Findings of Ramezani *et al.* [45] revealed that in experimental group (*Myrtus Communis* cream) in comparison to control group, a significant increase was seen in wound closure, hair follicle numbers, and blood vessel numbers. Also increased skin thickness and diameter of collagen fibers were observed. These findings showed the acceleration of wound healing in the treated samples. [45] Also, Rezaie *et al.* showed that *Myrtus communis* has considerable effect on healing of the experimental skin wounds on rats compared with zinc oxide. [46] Sumbul *et al.* showed that oral administration of aqueous extracts of *M. communis* significantly reduced the ulcer index in all models of gastric ulcers (ethanol, indomethacin and pyloric ligation). Also this plant reduced the gastric juice volume, total acidity and increased the gastric pH and gastric wall mucus content in all the models of ulcers. [47]

Green tea contains large amounts of *C. sinensis* that is a polyphenols and the concentrations progressively decrease in produced tea and in some tea products, such as black tea, their concentrations reach zero. Polyphenols are achromatic water-soluble substances and have a great role in human health, including antimicrobial, antineoplastic and anti-allergic properties, preventive effects on cardiovascular diseases and a strengthening effect on the human immune system. Antimicrobial effects of polyphenols include an inhibitory effect on the growth of various bacteria and viruses and fermenting bacteria. [23, 48]

According to previous studies, the anti-neoplastic and anti-mutational effects of epicatechins of green tea leaves [27] and the inhibitory effect of extract of green tea on some carcinogenic chemical agents have been proved. [49] The anti-ulcerative effects of the extract of black tea leaves on various wounds and ulcers, including stress-induced peptic ulcers, have been confirmed. [49-50] Hamaishi *et al.* [51] showed that green tea may primarily protect rat gastric mucosa from acute gastric mucosal injury and promote the healing

of chronic gastric ulcers by its antioxidant activity and gastric mucus-increasing actions. The study of Chatterjee *et al.* [52] reported that green tea relieved pain in a manner similar to diclofenac sodium, which is an indication of the anti-inflammatory effect of this plant. Eshghpour *et al.* [53] showed that green tea mouthwash could be an appropriate and safe choice to control postoperative pain after third molar surgery, which is an indication of the anti-inflammatory effect of this plant. Scoparo *et al.* [54] in their study found that green tea reduces the gastric lesions induced by ethanol and protects the gastric mucosa. In addition, the maintenance of gastric mucus and reduced glutathione levels was involved with the polysaccharides gastroprotection. [54]

Z. multiflora is traditionally used in various foodstuffs, especially in yoghurt, to add flavor and as an appetizer and antifatulent. It is also used to alleviate pains due to premature pregnancies and ruptures. In addition, the extracts of top branches of *Z. multiflora* have exhibited anti-inflammatory effects in acute and chronic inflammatory conditions. [27-28] This plant species has been used in traditional medicine as an antiseptic, antispasmodic and anti-inflammatory agent. [27] Moreover, it was showed that the aqueous and methanolic extracts of top branches of *Z. multiflora* have definite anti-inflammatory effects in acute and chronic inflammation. [28]

Conclusion

The results of the present study showed that *Myrtus communis L.* have significant effects on oral wound healing processes. These favorable results might introduce a new group of material or medicine which has been derived from this plant. Moreover, *Camellia sinensis L.* and *Zataria multiflora Boiss.* had no significant effect on wound healing.

Acknowledgements

This study was supported by the Kerman University of Medical Sciences. The authors would like to express their thanks to the Research Deputy for their financial support.

Conflict of Interest

Authors declare no conflict of interest.

References

- [1] Halberstein RA. Medicinal plants: historical and cross-cultural usage patterns. *Ann Epidemiol.* 2005; 15: 686-699.
- [2] Zollman C, Vickers A. ABC of complementary medicine. Users and practitioners of complementary medicine. *BMJ.* 1999; 319: 836-838.
- [3] Raskin I, Ribnicky DM, Komarnytsky S, Ilic N, Poulev A, Borisjuk N, et al. Plants and human health in the twenty-first century. *Trends Biotechnol.* 2002; 20: 522-531.
- [4] Kovacs EM, Lejeune MP, Nijs I, Westerterp-Plantenga MS. Effects of green tea on weight maintenance after body-weight loss. *Br J Nutr.* 2004; 91: 431-437.
- [5] De Smet PA. Herbal medicine in Europe--relaxing regulatory standards. *N Engl J Med.* 2005; 352: 1176-1178.
- [6] Rezaq AA, Elmallh MM. Anti-ulcer effect of cinnamon and chamomile aqueous extracts in rat models. *J Am Sci.* 2010; 6: 209-216.
- [7] Sharififar F, Derakhshanfar A, Dehghan-Nudeh G, Abbasi N, Abbasi R, Gharaei RR, et al. In vivo antioxidant activity of *Zataria multiflora* Boiss essential oil. *Pak J Pharm Sci.* 2011; 24: 221-225.
- [8] Sharififar F, Khazaelia P, Alli N. In Vivo Evaluation of Anti-inflammatory Activity of Topical Preparations from Fenugreek (*Trigonella foenum-graecum* L.) Seeds in a Cream Base. *Iran J Pharma Sci* 2009; 5: 157-162.
- [9] Sharififar F, Khazaeli P, Alli N, Talebian E, Zarehshahi R, Amiri S. Study of antinociceptive and anti-inflammatory activities of certain Iranian medicinal plants. *J Intercult Ethnopharmacol.* 2012; 1: 19-24.
- [10] Sharififar F, Moshafi MH, Mansouri SH, Khodashenas M, Khoshnoodi M. In vitro evaluation of antibacterial and antioxidant activities of the essential oil and methanol extract of *Zataria multiflora* Boiss. *Food Control.* 2007; 18: 800-805.
- [11] Hosseinzadeh H, Ramezani M, Salmani G. Antinociceptive, anti-inflammatory and acute toxicity effects of *Zataria multiflora* Boiss extracts in mice and rats. *J Ethnopharmacol.* 2000; 73: 379-385.
- [12] Dkhil MA, Abdel Moniem AE, Al-Quraishy S, Awadallah Saleh R. Antioxidant effect of purslane (*Portulaca oleracea*) and its mechanism of action. *J Med Plants Res.* 2011; 5: 1589-1563.
- [13] Miguel MG. Antioxidant and anti-inflammatory activities of essential oils: a short review. *Molecules.* 2010; 15: 9252-9287.
- [14] Sindhu G, Ratheesh M, Shyni GL, Nambisan B, Helen A. Anti-inflammatory and antioxidative effects of mucilage of *Trigonella foenum graecum* (Fenugreek) on adjuvant induced arthritic rats. *Int Immunopharmacol.* 2012; 12: 205-211.
- [15] Tipoe GL, Leung TM, Hung MW, Fung ML. Green tea polyphenols as an anti-oxidant and anti-inflammatory agent for cardiovascular protection. *Cardiovasc Hematol Disord Drug Targets.* 2007; 7: 135-144.
- [16] Nadkarni KM. *Indian Materia Medica.* 3rd ed. Popular Prakashan Pvt. Ltd.: Bombay- Indian; 1989. p. 838.
- [17] Kirtikar KR, Basu BD. *Indian Medicinal Plants.* 3rd ed. International book distributors: Dehra Dun; 1988. p. 1040-1042.
- [18] *The Wealth of India: A Dictionary of Indian Raw Materials and Industrial Products* 3/4 Raw Materials Series, Publications and Information Directorate, Council of Scientific & Industrial Research. 1th ed. New Delhi, India: Popular Prakashan; 1962. p. 482-483.
- [19] Ghani MN, Khazainul A, Sheikh Mohammad B. *Urdu Bazar.* 1th ed. Lahore: Popular Prakashan; 1920. p. 444-445.
- [20] Kabiruddin M, Makhzanul M, Bashir M. Lahore. 1th ed. Pakistan: Popular Prakashan; 1951. p. 47-48.
- [21] Hakeem MA, Bustanul M. *Idara Tarraqui Urdu Publications.* 1th ed. Lucknow: Popular Prakashan; 1895. p. 278.
- [22] Trease W, Evans D. *Pharmacognosy.* 15th ed. W.B. Saunders Comp Ltd.: Toronto; 2006. p. 477.
- [23] Fujiki H. Two stages of cancer prevention with green tea. *J Cancer Res Clin Oncol.* 1999; 125: 589-597.
- [24] Kozlovsky A, Artzi Z, Hirshberg A, Israeli-Tobias C, Reich L. Effect of local antimicrobial agents on excisional palatal wound healing: a clinical and histomorphometric study in rats. *J Clin Periodontol* 2007; 34: 164-71.
- [25] Mori L, Bellini A, Stacey MA, Schmidt M, Mattoli S. Fibrocytes contribute to the myofibroblast population in wounded skin and originate from the bone marrow. *Exp Cell Res.* 2005; 304: 81-90.
- [26] Mouli V, Castilloux G, Auger FA, Garrel D. Modulated response to cytokines of human wound healing myofibroblasts compared to dermal fibroblasts. *Experiment cell Res.* 1998; 238: 283-293.
- [27] Cheng S, Ding L, Zhen Y, Lin P, Zhu Y, Chen Y, et al. Progress in studies on the antimutagenicity and anticarcinogenicity of greentea epicatechins. *Chin Med Sci J.*

- 1991; 6: 233-238.
- [28] Burt SA, Vlieland R, Haagsman HP, Veldhuizen EJ. Increase in activity of essential oil components carvacrol and thymol against *Escherichia coli* O157:H7 by addition of food stabilizers. *J Food Prot.* 2005; 68: 919-926.
- [29] Burt S. Essential oils: their antibacterial properties and potential applications in foods--a review. *Int J Food Microbiol.* 2004; 94: 223-253.
- [30] Hashemipour MA, Ghasemi AR, Dogaheh MA, Torabi M. Effects of Locally and Systemically Applied n-3 Fatty Acid on Oral Ulcer Recovery Process in Rats. *Wounds.* 2012; 24: 258-266.
- [31] Olfert ED, Cross BM, McWilliam AA. Guide to the care and use of experimental animals. Canadian Council on Animal Care. 1993; 12: 301-309.
- [32] Hasturk H, Kantarci A, Ohira T, Arita M, Ebrahimi N, Chiang N, et al. RvE1 protects from local inflammation and osteoclast-mediated bone destruction in periodontitis. *FASEB J.* 2006; 20: 401-403.
- [33] Kesavalu L, Vasudevan B, Raghu B, Browning E, Dawson D, Novak JM, et al. Omega-3 fatty acid effect on alveolar bone loss in rats. *J Dent Res.* 2006; 85: 648-652.
- [34] Rosenstein ED, Kushner LJ, Kramer N, Kazandjian G. Pilot study of dietary fatty acid supplementation in the treatment of adult periodontitis. *Prostaglandins Leukot Essent Fatty Acids.* 2003; 68: 213-218.
- [35] Sciubba JJ. Oral mucosal diseases in the office setting--part I: Aphthous stomatitis and herpes simplex infections. *Gen Dent.* 2007; 55: 347-354.
- [36] Zambon JJ, Ciancio SG, Mather ML, Charles CH. The effect of an antimicrobial mouthrinse on early healing of gingival flap surgery wounds. *J Periodontol.* 1989; 60: 31-34.
- [37] Kozlovsky A, Artzi Z, Hirshberg A, Israeli-Tobias C, Reich L. Effect of local antimicrobial agents on excisional palatal wound healing: a clinical and histomorphometric study in rats. *J Clin Periodontol.* 2007; 34: 164-171.
- [38] Nadkarni KM. *Indian Material Medical.* 3rd ed. Popular Prakashan Pvt.Ltd.: Bombay; 1989. p. 838.
- [39] Kirtikar KR, Basu BD. *Indian Medicinal Plants.* 3rd ed. International Book Distributors: Dehra Dun; 1988. p. 1040-1042.
- [40] *The Wealth of India: A Dictionary of Indian Raw Materials and Industrial Products* ¼ Raw Materials Series, Publications and Information Directorate. 1th ed. Council of Scientific & Industrial Research: New Delhi, India; 1962. p. 482-483.
- [41] Flaminia G, Cionia P, Morellia I, Maccionib S, Baldini R. Phytochemical typologies in some populations of *Myrtus communis L.* on Caprione Promontory (East Liguria, Italy). *Food Chem.* 2004; 85: 599-604.
- [42] Rastogi RP, Mehrotra BN. *Compendium of Indian Medicinal Plants*, Central Drug Research Institute Lucknow. Publications and Information Directorate. 1th ed. CSIR: New Delhi; 1993. p. 444.
- [43] Shan B, Cai YZ, Brooks JD, Corke H. The in vitro antibacterial activity of dietary spice and medicinal herb extracts. *Int J Food Microbiol.* 2007; 117: 112-119.
- [44] Schelz Z, Hohmann J, Molnar J. Recent advances in research of antimicrobial effects of essential oils and plant derived compounds on bacteria. In: Chattopadhyay D, editor. *Ethnomedicine: a source of complementary therapeutics.* 2nd ed. Kerala: Research Signpost; 2010. p. 179- 201.
- [45] Ramezani T, Moosavi SR, Nabeuni M, Azarnia M. The effect of *Myrtus Communis* leave extract cream on wound healing process in Wistar rats. *J Tradit Med.* 2014; 3: 854-864.
- [46] Rezaie A, Mohajeri D, Khamene B, Nazeri M, Shishegar R, Zakhireh S. Effect of *Myrtus communis* on healing of the experimental skin wounds on rats and its comparison with zinc oxide. *Current Research Journal of Biological Sciences.* 2012; 4: 176-185.
- [47] Sumbul S, Ahmad MA, Asif M, Saud I, Akhtar M. Evaluation of *Myrtus communis* LINN. Berries (common myrtle) in experimental ulcer models in rats. *Hum Exp Toxicol.* 2010; 29: 935-944.
- [48] Balentine DA, Wiseman SA, Bouwens LC. The chemistry of tea flavonoids. *Crit Rev Food Sci Nutr.* 1997; 37: 693-704.
- [49] Katiyar SK, Korman NJ, Mukhtar H, Agarwal R. Protective effects of silymarin against photocarcinogenesis in a mouse skin model. *J Natl Cancer Inst.* 1997; 89: 556-566.
- [50] Wheeler SD, Wheeler JW. The medical chemistry of tea. *Drug Dev Res.* 2004; 61: 45-65.
- [51] Hamaishi K, Kojima R, Ito M. Anti-ulcer effect of tea catechin in rats. *Biol Pharm Bull.* 2006; 29: 2206-2213.
- [52] Chatterjee P, Chandra S, Dey P, Bhattacharya S. Evaluation of anti-inflammatory effects of green tea and black tea: A comparative in vitro study. *J Adv Pharm Technol Res.* 2012; 3: 136-138.

[53] Eshghpour M, Mortazavi H, Mohammadzadeh Rezaei N, Nejat A. Effectiveness of green tea mouthwash in post-operative pain control following surgical removal of impacted third molars: double-blind, randomized clinical trial. *Daru*. 2013; 21: 59-65.

[54] Scoparo CT, Souza LM, Dartora N, Sasaki GL, Santana-Filho AP, Werner MF, et al. Chemical characterization of heteropolysaccharides from green and black teas (*Camellia sinensis*) and their anti-ulcer effect. *Int J Biol Macromol*. 2016; 86: 772-781.