

**Original Article****A Comparative Study of Macrophage Density in Odontogenic Cysts and Tumors with Diverse Clinical Behavior**Maryam Kouhsoltani<sup>1</sup>, Mahsa Abdolhosseinzadeh<sup>2</sup>, Ayla Bahramian<sup>3</sup>, Maedeh Vakili Saatloo<sup>4</sup>, Fatemeh Dabbaghi Tabriz<sup>5</sup>, Tala Pourlak<sup>6</sup><sup>1</sup> Dept. of Oral and Maxillofacial Pathology, School of Dentistry, Tabriz University of Medical Sciences, Tabriz, Iran.<sup>2</sup> Dentist, Tabriz, Iran.<sup>3</sup> Dept. of Oral Medicine, School of Dentistry, Tabriz University of Medical Sciences, Tabriz, Iran.<sup>4</sup> Dept. of Oral and Maxillofacial Pathology, School of Dentistry, Urmia University of Medical Sciences, Urmia, Iran.<sup>5</sup> Dept. of Operative Dentistry, School of Dentistry, Tabriz University of Medical Sciences, Tabriz, Iran<sup>6</sup> Dept. of Pathology, School of Medicine, Tabriz University of Medical Sciences, Tabriz, Iran.**KEY WORDS**

CD68;

Immunohistochemistry;

Macrophage Density;

Odontogenic Lesions;

**ABSTRACT****Statement of the Problem:** Macrophages are the target of attention in numerous diseases. Many studies reported them as the regulators of the growth, dissemination, and clinical behavior of various lesions. There are relatively scarce data regarding the role of macrophages in oral lesions, particularly odontogenic lesions.**Purpose:** This study investigated the macrophage density in odontogenic lesions of diverse biologic performance.**Materials and Method:** In this comparative analytical study, 60 cases of odontogenic lesions including ameloblastoma, keratocystic odontogenic tumor, dentigerous cyst, and radicular cyst were immunohistochemically stained with anti-CD68 antibody. One-way ANOVA and Tukey's HSD test were used for statistical analysis.**Results:** The results showed that the macrophage density in keratocystic odontogenic tumor ( $35.72 \pm 7.74$ ) and ameloblastoma ( $46.12 \pm 9.84$ ) was not significantly different from that in dentigerous cyst ( $43.87 \pm 8.13$ ). Interestingly, the macrophage density in keratocystic odontogenic tumor was lower than that in dentigerous cyst. No significant difference was observed in macrophage density between the ameloblastoma and much less aggressive lesions like dentigerous cyst ( $p = 0.59$ ). Macrophage density in radicular cyst ( $81.53 \pm 11.04$ ) was significantly higher than other odontogenic lesions ( $p < 0.001$ ).**Conclusion:** The lack of significant differences in macrophage density between the known aggressive odontogenic tumors and much less aggressive lesions implied that macrophages might not contribute to the biological behavior of the odontogenic lesions. Therefore, it could support the notion that targeted therapy would not have prominent clinical potential to decrease the extent of mutilating surgeries in odontogenic lesions.Received April 2017;  
Received in Revised form July 2017;  
Accepted September 2017;**Corresponding Author:** Pourlak T., Dept. of Pathology, School Faculty of Medicine, Tabriz University of Medical Sciences, Tabriz, Iran. Tel: +98-41-33355965-9 Email: dr.pourlaktala@yahoo.comCite this article as: Kouhsoltani M., Abdolhosseinzadeh M., Bahramian A., Vakili Saatloo M., Dabbaghi Tabriz F., Pourlak T. A Comparative Study of Macrophage Density in Odontogenic Cysts and Tumors with Diverse Clinical Behavior. *J Dent Shiraz Univ Med Sci.*, 2018 June; 19(2): 150-154.**Introduction**

Odontogenic lesions are one of the most common and important disorders of oral and maxillofacial region. These lesions arise from the odontogenic apparatus, which forms dental organ and its peripheral structures. Odontogenic cysts and tumors, particularly those with

aggressive biological behavior (the destructive lesions with high growth and recurrence rates), have harmful effects including bone destruction. However, the pathogenesis and reasons for the diverse clinical behavior of these lesions remain ambiguous. [1-3]

Various epithelium-associated factors have been

indicated to influence the biological behavior of the odontogenic lesions. [4-5] Nevertheless, due to the inconsistency of the results, micro-environmental factors have received more attentions as the more important component influencing the development, dissemination, and biological behavior of these lesions. [2, 4-5]

Odontogenic lesions contain a stromal component that mainly consists of blood vessels, fibroblasts, and immunological cells, principally macrophages and lymphocytes. [6-7] Macrophages are the major cellular component of the stroma and play a key role in the microenvironment. Dissimilar to dendritic cells that move in and out of the oral mucosa, macrophages remain within it and exhibit diverse functions. [6, 8] These cells increase in a number of oral diseases and are the target of attention in numerous lesions. Many studies have reported that macrophages are the regulators of the growth, dissemination, and clinical course of various diseases. [9-12]

There are relatively scarce data about the macrophage density in oral lesions. Therefore, the aim of this study was to investigate the role of macrophages in odontogenic lesions with diverse biologic behaviors. This can be helpful in planning of targeted therapeutic strategies with the hope of reducing mutilating and extensive surgeries. In the present study, anti-CD68 antibody was used as a valuable immunohistochemical biomarker for the identification of macrophages. [13-14]

## **Materials and Method**

The protocol of the present comparative analytical study was approved by the Ethics Committee of Tabriz University of Medical Sciences under the code IRIC: TBZMED.REC.1394.1130

### **Tissue samples**

Samples of 15 dentigerous cyst (DC), 15 keratocystic odontogenic tumor (KOT), 15 radicular cyst (RC) and 15 ameloblastoma were retrieved from the laboratory archives of Oral and Maxillofacial Department of Tabriz Dentistry School over a 10-year period (from 2005 to 2015).

The study was performed on odontogenic cysts and tumors located in the jaw bones of patients who had received only surgical treatments and whose appropriate paraffin blocks and complete health records and clinical findings were available. The study excluded inappropri-

ate paraffin blocks, which could not be properly cut, the samples with insufficient microscopic fields to analyze, and inflamed dentigerous cysts, keratocystic odontogenic tumors, and ameloblastomas.

### **Immunohistochemical staining**

Formalin-fixed paraffin-embedded tissue samples were cut into 4- $\mu$ m sections and submitted to immunohistochemical staining. The samples were stained with Biotin-streptavidin method according to the manufacturer's guidelines (DakoCytomation; Glostrup, Denmark). The samples were deparaffinized in xylene, rehydrated with graded alcohol, and peroxidase quenched in 1% hydrogen peroxide. The sections were then treated with 0.01 M sodium citrate buffer (pH 6.0) for unraveling of the epitopes, and subsequently rinsed with distilled water.

The samples were incubated with 1:50 diluted monoclonal mouse anti-human CD68 primary antibody for 30 min at the room temperature to detect the macrophages, and then rinsed with phosphate buffered saline. The immune reaction was amplified by using the secondary antibody and Streptavidin-Biotin-Peroxidase HRP complex (Envision/HRP). The reaction products were visualized by using 3, 3'-diaminobenzidine (DAB) as chromogen. The sections were finally counterstained with Harris hematoxylin and mounted.

### **Staining evaluation**

The prepared slides were scanned at 100X magnification to identify the fields with the highest number of macrophages (hot spot fields). Five hot spot fields were selected and the quantitative evaluations were performed at 400X magnification. The stained CD68-positive cells were counted in each high power field and the mean of five fields was considered as macrophage density for each case.

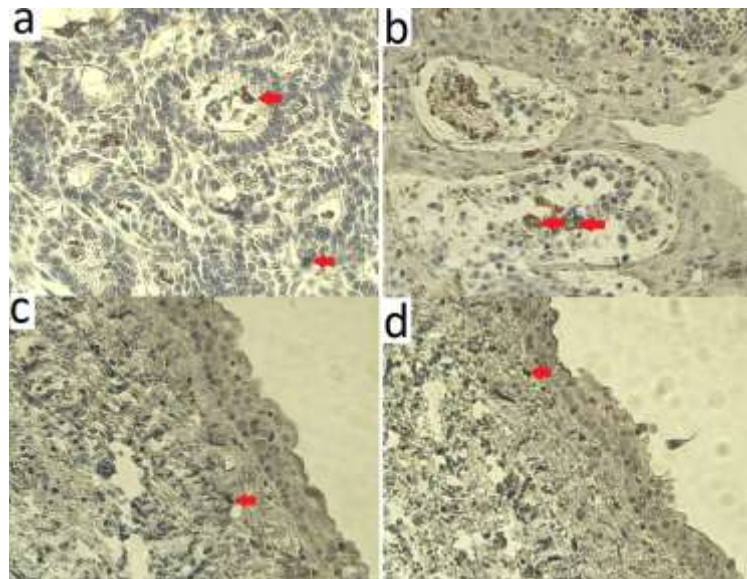
### **Statistical analysis**

The data from each clinical group were expressed as mean  $\pm$  standard error of mean. The collected data were analyzed by using SPSS software, version 20.0 (SPSS; Chicago, IL). One-way ANOVA and Tukey's HSD test was used for statistical comparisons between the groups. *p* Value <0.05 was considered to be statistically significant.

## **Results**

### **Clinical and histopathologic profile of the patients**

The study was performed on 60 samples in four groups



**Figure 1:** CD68 positive cells (marked with red arrows) in: a) ameloblastoma, b) radicular cyst, c) keratocystic odontogenic tumor, d) dentigerous cyst (IHC stain,  $\times 400$ ).

of dentigerous cyst, keratocystic odontogenic tumor, radicular cyst, and ameloblastoma ( $n=15$  each). In dentigerous cyst group, 7 cases were males and 8 were females, aging from 10 to 59 years old (mean=26 years). Most of the lesions were located in posterior mandible. In keratocystic odontogenic tumor group 6 were males and 9 were females with the age range of 13-52 years old (mean=26 years). These lesions were mostly located in posterior mandible. In radicular cyst samples, 8 were males and 7 were females with the age range from 12 to 62 years old (mean=26 years). The most commonly affected locations were posterior regions of the jaws (mandible and maxilla were affected equally). In ameloblastoma group, 5 cases were males and 10 were females aging from 23 to 49 years old (mean=40 years). The lesions were mostly located in posterior mandible.

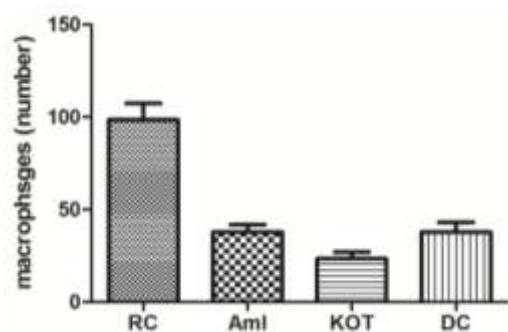
The basic histopathologic features of the studied lesions are described in literature. Most cases of ameloblastoma demonstrated plexiform or follicular histopathologic patterns.

**Detection of macrophages**

Based on the findings of the current study, CD68- positive cells were disseminated among the lymphocytic components. Macrophages were clustered or diffusely distributed along the inflammatory infiltrations, generally near the epithelium of the lesion (Figure 1).

The mean values and standard error of means (SEMs) for all the studied odontogenic lesions were as follows in descending order:  $81.53 \pm 11.04$  for radicular cyst,  $46.12 \pm 9.84$  for ameloblastoma,  $43.87 \pm 8.13$  for

dentigerous cyst, and  $35.72 \pm 7.74$  for keratocystic odontogenic tumor (Figure 2). Our results showed that macrophage densities in keratocystic odontogenic tumor and ameloblastoma were not significantly different from that in dentigerous cyst ( $p= 0.35$  and  $p= 0.59$ , respectively). Interestingly, the macrophage density in keratocystic odontogenic tumor was lower than that in dentigerous cyst. The statistical analysis of the data showed a higher macrophage density in radicular cyst in comparison with the other studied groups ( $p < 0.001$ ).



**Figure 2:** Histogram of macrophage density in RC: radicular cyst; Aml: ameloblastoma; KOT: keratocystic odontogenic tumor; DC: dentigerous cyst

**Discussion**

Both odontogenic cysts and tumors originate from odontogenic apparatus. However, these lesions show different degrees of aggressiveness and clinical behavior. [1, 3] Ameloblastoma is a benign tumor with high degree of infiltration, bone destruction and recurrence. According to the World Health Organization’s (WHO) latest classification of odontogenic lesions, keratocystic

odontogenic tumor is categorized as an odontogenic tumor, because of its growth mechanism, clinical course, and relatively high recurrence rate. However, this lesion is a cystic tumor, which is less aggressive than ameloblastoma. [1, 3]

Dentigerous cyst is a developmental cyst with a relatively non-invasive clinical course and low recurrence rate. Radicular cyst is an inflammatory cyst with a relatively indolent clinical course. [1-3] The development of odontogenic lesions involves a micro-environment in which chemical mediators and cellular component influence their progression. However, the biologic significance of macrophages (the major cellular component of the stroma) is not fully understood in these lesions. [2, 18]

Many previous studies have investigated the relationship between the number of macrophages and the biological course of the diseases in various sites of the body. However, the results are conflicting and it is still uncertain if macrophages exert pro or anti-growth actions. Some studies reported obvious relationships between these cells, and the development and the clinical outcome of the diseases. Conversely, these cells showed anti-tumor functions in other studies. [14-16]

The present study found no significant difference in the macrophages densities of diverse clinical variants of odontogenic lesions except for radicular cyst. It could be suggested that macrophages do not play an active role in the pathogenesis of these lesions. Therefore, macrophages are possibly a component of nonspecific inflammatory reaction in these odontogenic lesions.

In a study by Guzmán-Medrano *et al.*, [2] macrophages were more commonly observed in solid ameloblastoma than in unicystic and desmoplastic ameloblastoma. The lower density of macrophages in desmoplastic ameloblastoma might be associated with the very low cellular density in these lesions because of the high volume of desmoplasia in these lesions. Unfortunately, the mentioned study did not include a control group, otherwise, it could be stated that macrophage density was not significantly different between the case and control groups.

Interestingly, the current study detected no significant difference in macrophage density between ameloblastoma and much less aggressive lesions. Some studies showed marked differences not only between lesions

but also between different clinical variants of some tumors such as ameloblastoma. [2] Different pathologic grades, clinical stages, and populations may explain the different results of these studies. Furthermore, the macrophage count can also be influenced by different methods of assessment and subsequently different immunohistochemical antibodies that are used for macrophages detection like CD68 [2] and CD163. [17]

The highest amount of macrophages in radicular cyst was also confirmed in other studies. Macrophages increase in periapical lesions due to many reasons such as immune responses and inflammatory processes. [18-19] Although many studies demonstrated that macrophages were tumor cell destroyers, some of them proved that they prohibited the tumors development. [20-21] The findings of the present study did not support macrophages as the contributing factor in the aggressiveness of odontogenic lesions.

### **Conclusion**

Development of a lesion is a complex process involving numerous factors and this study do not approve macrophages as the main contributing factor in the biological behavior of these odontogenic lesions. Therefore, it can be claimed that molecular targeting of macrophages does not have significant potential clinical value to reduce the mutilating and extensive surgeries of aggressive odontogenic lesions. However, further studies with larger sample sizes and other relatively rare odontogenic tumors are recommended to confirm the role of macrophages in the clinical course of odontogenic lesions

### **Acknowledgements**

This paper was extracted from the thesis No. 1422. This thesis was financially supported by the Research Council of Tabriz, University of Medical Sciences.

### **Conflict of Interest**

There is no conflict of interest.

### **References**

- [1] Regezi JA, Sciubba JJ, Jordan RC. Oral pathology: clinical pathologic correlations. 7th ed. St Louis: Saunders Elsevier; 2017. p. 245-288.
- [2] Guzmán-Medrano R, Arreola-Rosales RL, Shibayama M, Silva-Olivares DA, Bologna-Molina R, Rodríguez MA.

- Tumor-associated macrophages and angiogenesis: a statistical correlation that could reflect a critical relationship in ameloblastoma. *Pathol Res Pract.* 2012; 208: 672-676.
- [3] Neville B, Damm D, Allen C, Bouquot J. Allergies and immunologic diseases. *Oral and maxillofacial pathology.* 4th ed. St Louis: Saunders Elsevier; 2016. p. 632-681.
- [4] Kumamoto H, Izutsu T, Ohki K, Takahashi N, Ooya K. p53 gene status and expression of p53, MDM2, and p14 proteins in ameloblastomas. *J Oral Pathol Med.* 2004; 33: 292-299.
- [5] Thosaporn W, Iamaroon A, Pongsiriwet S, Ng KH. A comparative study of epithelial cell proliferation between the odontogenic keratocyst, orthokeratinized odontogenic cyst, dentigerous cyst, and ameloblastoma. *Oral Dis.* 2004; 10: 22-26.
- [6] Bôas DS, Takiya CM, Coelho-Sampaio TL, Monção-Ribeiro LC, Ramos EA, Cabral MG, et al. Immunohistochemical detection of Ki-67 is not associated with tumor-infiltrating macrophages and cyclooxygenase-2 in oral squamous cell carcinoma. *J Oral Pathol Med.* 2010; 39: 565-570.
- [7] Giușcă SE, Zugun FE, Târcoveanu E, Carasevici E, Amălinei C, Căruntu ID. Immunohistochemical study of colorectal cancer liver metastases: the immune/ inflammatory infiltrate. *Rom J Morphol Embryol.* 2010; 51: 73-79.
- [8] Merry R, Belfield L, McArdle P, McLennan A, Crean S, Foey A. Oral health and pathology: a macrophage account. *Br J Oral Maxillofac Surg.* 2012; 50: 2-7.
- [9] Nonomura N, Takayama H, Nakayama M, Nakai Y, Kawashima A, Mukai M, et al. Infiltration of tumour-associated macrophages in prostate biopsy specimens is predictive of disease progression after hormonal therapy for prostate cancer. *BJU Int.* 2011; 107: 1918-1922.
- [10] Steidl C, Lee T, Shah SP, Farinha P, Han G, Nayar T, et al. Tumor-associated macrophages and survival in classic Hodgkin's lymphoma. *N Engl J Med.* 2010; 362: 875-885.
- [11] Tsutsui S, Yasuda K, Suzuki K, Tahara K, Higashi H, Era S. Macrophage infiltration and its prognostic implications in breast cancer: the relationship with VEGF expression and microvessel density. *Oncol Rep.* 2005; 14: 425-431.
- [12] Wolf GT, Chepeha DB, Bellile E, Nguyen A, Thomas D, McHugh J. Tumor infiltrating lymphocytes (TIL) and prognosis in oral cavity squamous carcinoma: a preliminary study. *Oral Oncol.* 2015; 51: 90-95.
- [13] Rosai J. *Rosai and Ackerman's Surgical Pathology.* 10th ed. St Louis: Saunders Elsevier; 2012. p. 48-63.
- [14] Sugimura K, Miyata H, Tanaka K, Takahashi T, Kurokawa Y, Yamasaki M, et al. High infiltration of tumor-associated macrophages is associated with a poor response to chemotherapy and poor prognosis of patients undergoing neoadjuvant chemotherapy for esophageal cancer. *J Surg Oncol.* 2015; 111: 752-759.
- [15] Forssell J, Oberg A, Henriksson ML, Stenling R, Jung A, Palmqvist R. High macrophage infiltration along the tumor front correlates with improved survival in colon cancer. *Clin Cancer Res.* 2007; 13: 1472-1479.
- [16] Komohara Y, Hasita H, Ohnishi K, Fujiwara Y, Suzu S, Eto M, et al. Macrophage infiltration and its prognostic relevance in clear cell renal cell carcinoma. *Cancer Sci.* 2011; 102: 1424-1431.
- [17] Sousa-Neto ES, Cangussu MC, Gurgel CA, Guimarães VS, Ramos EA, Xavier FC, et al. Interaction of stromal and microvascular components in keratocystic odontogenic tumors. *J Oral Pathol Med.* 2016; 45: 557-564.
- [18] Rodini CO, Lara VS. Study of the expression of CD68+ macrophages and CD8+ T cells in human granulomas and periapical cysts. *Oral Surg Oral Med Oral Pathol Oral Radiol Endod.* 2001; 92: 221-227.
- [19] Walker KF, Lappin DF, Takahashi K, Hope J, Macdonald DG, Kinane DF. Cytokine expression in periapical granulation tissue as assessed by immunohistochemistry. *Eur J Oral Sci.* 2000; 108: 195-201.
- [20] Medrek C, Pontén F, Jirström K, Leandersson K. The presence of tumor associated macrophages in tumor stroma as a prognostic marker for breast cancer patients. *BMC Cancer.* 2012; 12: 306.
- [21] Herrera M, Herrera A, Domínguez G, Silva J, García V, García JM, et al. Cancer-associated fibroblast and M2 macrophage markers together predict outcome in colorectal cancer patients. *Cancer Sci.* 2013; 104: 437-444.