

Original Article**Morphology and Dimensions of Nasopalatine Canal: a Radiographic Analysis Using Cone Beam Computed Tomography**Leila Khojastepour ¹, Abdolaziz Haghnegahdar ¹, Marzieh Keshtkar ²¹ Dept. of Oral and Maxillofacial Radiology, School of Dentistry, Shiraz University of Medical Science, Shiraz, Iran.² Student Research Center, Dental School, International Branch of Shiraz University of Medical Science, Shiraz, Iran.**KEY WORDS**Nasopalatine Canal;
Cone Beam Computed
Tomography (CBCT);
Anatomic Variation;**ABSTRACT****Statement of the Problem:** The surgical procedure of dental implantation in anterior maxillary area may be limited by the shape and size of nasopalatine canal (NPC). CBCT imaging provides three-dimensional information for surgical planning.**Purpose:** This study is designed to evaluate the anatomy of NPC in a selected Iranian population.**Materials and Method:** In this cross sectional study, CBCT images of 301 patients were evaluated for NPC characteristics. Five linear measurements including width and length of NPC were performed on reformatted sagittal cross sections. The shapes of NPC were also classified in three groups according to Bronstein *et al.* classification in CBCT coronal cross sections. The effects of age and gender on measured dimension were assessed. Student's t-test, one-way ANOVA/Tukey HSD tests, chi-square and Pearson's correlation coefficient were used for statistical analysis.**Results:** The study comprised 140 males (48.5%) and 161 females (53.5%) with mean age of 34.56±11.87. The mean length of NPC for men and women were 11.46 and 9.37 mm respectively, showing a significant statistical difference. Other dimensions of NPC and alveolar bone thickness were also greater in men with exception of buccal bone plate width in front of Stensen foramen (8.45±2.24 vs. 8.52±2.03 mm). Most of the cases showed Y-shape configuration. The diameter of oral opening of NPC (3.17±1.01 mm) was positively correlated with the patients age ($r=0.138$, $p=0.01$), while buccal bone over the oral opening of NPC (7.05±1.38) mm showed negative correlation with age ($r=-0.199$, $p=0.001$).**Conclusion:** All NPC dimensions are meaningfully greater in men except for buccal bone plate thickness in front of Stensen foramen. The type of canal has no effect on dimensions of the canal.**Corresponding Author:** Keshtkar M., Dental School, Shiraz University of Medical science Ghasrod-dasht Street, Postal code 71956-15875 Email: keshtgarmd88d@yahoo.com Tel: +98-71-36263193-4 Fax: +98-71-362670325Received July 2016;
Received in Revised form September 2016;
Accepted February 2017;**Cite this article as:** Khojastepour L., Haghnegahdar AA., Keshtkar M. Morphology and Dimensions of Nasopalatine Canal: a Radiographic Analysis Using Cone Beam Computed Tomography. *J Dent Shiraz Univ Med Sci.*, 2017 December; 18(4): 244-250.**Introduction**

Currently, various implant procedures are considered as the method of choice for replacing missing teeth. Dental implants spread among dentist all over the world since they could restore the functional and es-

thetic needs much more satisfying than previous prosthodontics measures. [1] On the other hand, placing a successful implant is a great challenge for dental clinicians. One of the most critical factors determining the success of any dental implant treatment is the receiv-

ing bone status. [2] Quantity of bone and its shape provide necessary space for implant fixture. Quality of bone will determine the future stability and osseointegration success. Maxillary anterior teeth are of utmost esthetically important teeth. They are also very vulnerable to trauma especially in childhood. [3] Replacing these teeth is a challenge for dentists; therefore, repairing function, esthetic and phonetics must all be considered and satisfied. [3] Esthetic outcome is considered as an essential factor in implant dentistry and it could even surpass the functional aspects of the dental implant therapy in the anterior of maxilla. [4] Location and angle of implant would affect all these aspects. [5-7] A safe distance between critical anatomical landmarks and dental implant is also necessary for a successful and stable implant treatment. The nasopalatine canal (NPC) is a bony connection between the nasal and oral cavities and contains relative neurovascular bundle. The inferior (oral) end of the NPC is a circular opening called incisive foramen behind the maxillary central incisors. [8-11] The superior (nasal) end of the canal usually bifurcates into foramina of Stensen. [9] As a normal variation, the NPC may be split into any number of canaliculi by a complete or incomplete bony septum. [10-11]

According to Jacobs *et al.*, [12] surgical interventions in NPC area have been increased significantly. Awareness about the anatomical variations of the NPC is fundamental for avoiding neurovascular bundles damage. [8-9, 13-17]

To avoid injury to the nerve and vessel within the canal and its subsequent complications such as hemorrhage and sensory dysfunction, dental implants must be placed at an adequate distance from NPC. [12, 18] In addition to sensory dysfunction, neural tissue violation may result in failure of osseointegration. [19-20] Meanwhile, cone beam computed tomography (CBCT) could provide thorough three-dimensional information regarding shape, location and dimensions of NPC and its relative variations if present. [18, 21-24] This information is necessary for avoiding the complications during and after dental-implant surgery. [25]

Rapid development and widespread use of CBCT in last decade provides valuable 3D information that has encouraged researchers to study anatomical varia-

tions of different maxillofacial structures, including incisive canal. [14-15, 18, 22-24]

The aim of this study was to evaluate the morphology, dimensions and variations of NPC in CBCT images of dentulous adult patients. Buccal bone plate dimensions and the effects of sex and age on aforementioned items were also investigated.

Materials and Method

After receiving approval from Ethical Committee, the patients referred to a private Dentomaxillofacial radiology clinic for pre-implant CBCT evaluation were asked to participate in this cross sectional study. Four hundred and thirty patients enrolled in whom 301 patients (161 females, 140 males) met the exclusion-inclusion criteria. The inclusion criteria were the age ≥ 18 years and having both maxillary central incisors. Presence of impacted teeth, radiolucent or radiopaque lesion, bone grafts or any bony surgical intervention in the anatomical area of interest, suspected NPC pathology, cleft plate and related syndromes as well as history of orthodontic treatment were considered as exclusion criteria. Written informed consent was obtained from all participants.

All the CBCT images were obtained in standard resolution mode (voxel size of 0.3mm) using NewTom VGi scanner (QR srl; Verona, Italy, kVp=110, and exposure time of 3.6 s) with FOV 8×8cm, or 8×12cm. Coronal and sagittal cross sections were prepared with 1mm thickness at an interval of 0.5mm. The images were observed by a trained senior student of dentistry under direct supervision of an experienced maxillofacial radiologist in standard viewing conditions. Both NPC dimensions and anatomy were assessed. The measurements were made for dimensions of the NPC canal in mm using the reformatted sagittal CBCT cross sections as K1 (diameter of nasal opening of the canal) K2 (diameter of oral opening of the canal), K3 (length of the canal; maximum vertical distance between the nasal and oral opening), K4 (width of the buccal bone plate over the oral opening) and K5 (width of the buccal bone plate over the nasal opening). (Figure 1)

In the coronal CBCT cross sections, the NPC anatomy was classified into three groups based on Bornstein *et al.*'s classification. [24] This classification included type A with a single canal; type B with two

parallel canals and type C which included variations of the Y-type of canal with one oral opening (incisive foramen) and two or more nasal openings (foramina of Stensen). (Figures 2 and 3)

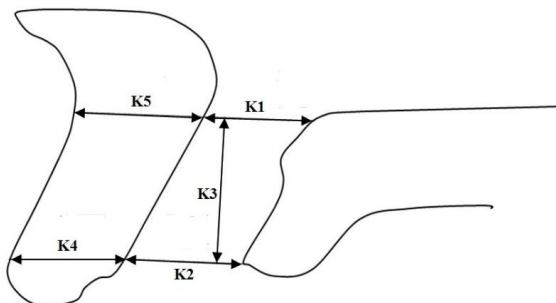


Figure 1: Measured dimensions on reformatted sagittal cross section, K1: diameter of nasal opening of NPC, K2: diameter of oral opening of NPC, K3: length of NPC, K4: buccal bone plate width over the NPC oral opening, K5: buccal bone plate width over the NPC nasal opening




Figure 2: Anatomic Classification of NPC morphology: A single canal (Type A), Two separate canals (Type B) and Y shape canals (Type C)

Statistical analysis

Student’s t-test and one-way ANOVA/Tukey HSD tests were used to compare the mean of dimensions between different groups of participants. Chi-square test was used to compare the frequency of canal shape between groups. Pearson’s correlation coefficient was applied to assess the correlation between dimensions and age, SPSS version 17.0 (SPSS Inc., Chicago, IL, USA) was employed for data analysis. Results were considered significant at the $p < 0.05$ level.

Results

Considering the study criteria, from 430 cases who recruited in this cross sectional study, 301 cases were included. The age of patients ranged from 18 to 74 years (34.56 ± 11.87 years). 129 cases were excluded due to one of the following reasons: poor image quality and artifacts (17 cases); suspected NPC canal pathology (19 cases); missing or extracted central incisors (35 cases); implant placement and/or bone graft in the maxillary anterior region (27 cases); presence of orthodontics appliances and/or maxillary expander (31 cases).

The study comprised 140 males (48.5%) and 161 females (53.5%) with mean age of 33.32 ± 12.42 and 33.08 ± 12.80 respectively. Measured dimensional values in study sample were recorded in Table 1.

Table 1: The description of measured dimensions

Variable	Max	Min	Mean \pm SD
K1 (mm)	10.00	0.3	3.17 \pm 1.51
K2 (mm)	6.00	1.00	3.17 \pm 1.014
K3 (mm)	21.00	5.00	10.34 \pm 2.74
K4 (mm)	12.00	2.00	7.05 \pm 1.38
K5 (mm)	14.00	1.00	8.49 \pm 2.13

Type C was the most prevalent type of NPC among the study cases and Type B was the least frequent one (46.6% versus 10%). The frequencies and percentages of various NPC types according to gender are presented in Table 2. There was no statistically significant difference in canal type distribution according to the gender.

Table 2: The frequencies and percentages of various nasopalatine canal types according to gender

Gender	NPC Type		
	A	B	C
Male	63(45.0%)	10(7.1%)	67(47.9%)
Female	68(42.2%)	20(12.4%)	73(45.3%)

Chi-Square test, $p = 0.41$

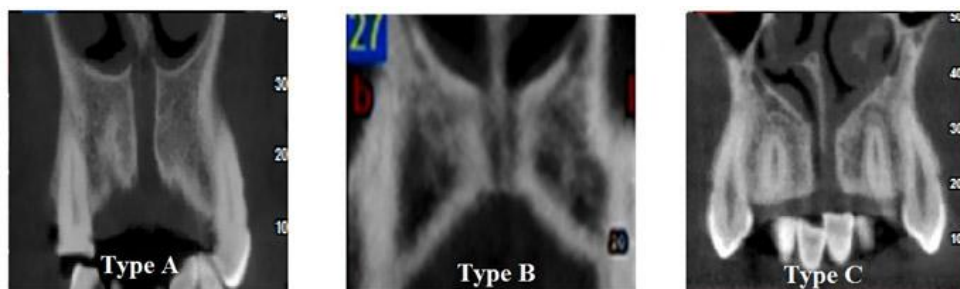


Figure 3: Example of various types of NPC morphology

Table 3: Effect of the gender on measured dimensions in reformatted sagittal CBCT cross sections (t-test)

	Dimensional Measurements Mean \pm SD mm				
	K1	K2	K3	K4	K5
Male	3.39 \pm 1.55	3.40 \pm 1.08	11.46 \pm 2.86	7.36 \pm 1.45	8.45 \pm 2.24
Female	2.98 \pm 1.45	2.97 \pm .91	9.37 \pm 2.24	6.78 \pm 1.27	8.52 \pm 2.03
p Value	.020	.000	.000	.000	.790

Table 4: Comparison of nasopalatine canal and buccal plate dimensions between different types of canal (ANOVA)

Canal Types	Measurements (mm)				
	K1	K2	K3	K4	K5
A	2.92 \pm 1.27 ^A	3.16 \pm 0.93 ^A	10.57 \pm 2.92 ^A	7.04 \pm 1.41 ^A	8.28 \pm 2.32 ^A
B	3.87 \pm 2.10 ^B	3.03 \pm 1.10 ^A	10.43 \pm 2.84 ^A	7.43 \pm 1.63 ^A	8.63 \pm 1.96 ^A
C	3.25 \pm 1.52 ^{AB}	3.21 \pm 1.08 ^A	10.112 \pm 2.55 ^A	6.98 \pm 1.29 ^A	8.64 \pm 1.97 ^A
p Value	0.006	0.690	0.381	0.262	0.351

Mean values with at least one same letter in superscript were not statistically different (Tukey HSD test)

The effect of the gender on measured dimensions was recorded on Table 3. All NPC diminution including the length and the diameter of both nasal and oral opening (K3,K2 and K1) were significantly greater among men. Buccal bone palate thicknesses at the front of oral opening of the canal (K4) of men were also significantly greater than that in women. (Table 3)

NPC dimensions as well as width of the buccal bone over the oral and nasal opening in different types of canal are shown in Table 4. There were no statistically significant differences among various measured dimensions in different types of canal except for the diameter of nasal opening. Nasal opening of NPC in type B cases was significantly greater than type A. (Table 5)

Table 5: Correlation between measured dimensions and age

Variable	r	p Value
K1	-0.021	0.705
K2	0.138	0.01*
K3	-0.062	0.266
K4	-0.199	0.001*
K5	0.053	0.24

* Pearson correlation

The width of the buccal bone over the oral opening of NPC (7.05 \pm 1.38mm) decreased as the age increased and it showed significant negative correlation with age (r= -0.199, p= 0.001). The width of oral opening of NPC however (3.17 \pm 1.01mm), was positively correlated with the patients age and it significantly increased by aging. (r= 0.138, p= 0.01).

Discussion

Maxillary anterior teeth are of outmost esthetic importance, especially upon smiling. Their angulations and l-

ocation determine the midface profiles of the individual. These teeth are also responsible for incising. Unfortunately, they are most vulnerable teeth to trauma because of their exposed location. Since they are also thin planar teeth, considerable proportions of their structures can be damaged by caries in a short time or through iatrogenic assaults during dental treatments. All these may result in their loss prematurely. Currently, surgical implants are the broadest accepted method to rehabilitate tooth loss in anterior maxilla, but this procedure faces some anatomic limitations in the area. NPC can occupy up to 58% of buccal bone plate width, which should receive and support the implants. [13] Adequate information about dimensions and 3-dimensional configuration of this canal is critically needed for comprehensive planning of an implant treatment in anterior maxilla. Incautious operations may damage the neurovascular content of NPC, resulting in anesthesia, hemorrhage, and failure of osseointegration. Three-dimensional CBCT imaging can reveal the anatomic characteristics and variation of NPC precisely. [15, 19, 26]

CBCT imaging is increasingly applied for pre-implant radiographic evaluations. This technique of imaging is based on a cone-shaped x-ray source and a two dimensional detector, which preparing data in a single rotation around the patient head. Time and patient dose are considerably decreased comparing with conventional CT scans. [26-27] This study performed to search the normal metric values of NPC in an Iranian population using CBCT imaging. The mean lengths of NPC were 11.46 in males and 9.37 mm in females, showing a significant difference between genders. Avila

et al., Güncü et al. and Safi et al. also reported comparable significant sexual differences. [23, 26, 28] Acar and Kamburoğlu [13] found the diameter of oral and nasal opening of NPC to be greater in men. Similarly, a significant difference was found between men and women in NPC anatomic diameters in present study. Regardless of the gender, Kajan et al. [29] reported mean values for oral and nasal opening of NPC in an Iranian population to be about 3.53 ± 1.01 and 3.7 ± 2.3 mm respectively. These quantities were 3.17 ± 1.01 and 3.17 ± 1.51 respectively in the present studies that are comparable since both studies are performed in approximately similar population. Acar and Kamburoğlu; [13] however, reported slightly greater values for both opening diameter in a Turkish population. Further investigations are needed to evaluate how racial characteristics may play a role in anatomic varieties of NPC.

Recently Jia et al. [30] evaluated the ridge configuration anterior to the NPC in dentate and partially edentulous individuals. According to the results of their study, the palatal concavity depth and angle were greater and bone height was shorter in partially edentulous patients. [30] In the study of Al-Amer et al., for avoiding the possible negative effect on the morphology of the IC, the edentulous cases during CBCT assessment of maxillary incisive canal and foramen were excluded from the study sample. [14]

Unlike Dalili et al. [29] and Safi et al. [23] studies, the presence of both maxillary central incisors were considered as the inclusion criteria in the present study. In accordance with Safi et al. [23] findings, Y-shaped canals in coronal cross sections of the present study was also the most frequent configuration for NPC (type C=46.5%). It followed intimately by single canal (type A=43.5%). Two parallel canals (type B) comprised only 10% of cases. The sequence and percentages are closely similar with those reported by Bronstein et al. [24] and Fernández-Alonso et al., [27] although different race were studied in their researches. This probably shows that canal shapes may not be affected by race.

Bronstein et al. [24] and Fernández-Alonso et al., [27] reported that buccal bone plate is affected by gender, although the geometric characteristics of measurements were different between these studies. Our results in this regard were in accordance with their findings. Some studies evaluated the effect of presence or ab-

sence of maxillary anterior teeth on the width of buccal bone plate. [13, 24, 27] They mentioned that missing of maxillary anterior teeth would result in dramatic decrease in buccal bone plate width. In present study, all measurements were performed on dentate upper jaws. Regarding the critical esthetic role of upper central incisors, most people prefer to benefit immediate implants for replacing these teeth. [14] Therefore, there will be usually no time for bone resorption, and normal dentate relationships should be considered.

It is worthy of mention that, based on the present study, the buccal bone plate width in dentate individual decreases with age, resulting in accompanying increase in the diameter of NPC. It means that resorption occurs more significantly in the lingual side of alveolar bone regardless of the presence of teeth. Finally, there was no relationship between the values of measured dimensions and the types of canal morphology. It means that each morphological types of NPC can be observed in any individual regardless of the dimension of their mid face.

Conclusion

NCP shows a large variety in morphology and dimensions. In studied population, Y-shape canals (type C) were the most prevalent form and two separated canals (type B) comprises the least cases. All NPC canal dimensions as well as the buccal bone plate over the oral opening of the canal are significantly higher in male individuals. Furthermore, buccal bone plate width reversely and NPC diameter directly are affected by age.

Acknowledgements

The authors thank the Vice-Chancellery, International branch of Shiraz University of Medical Science for supporting this research (Grant# 8895146). This article is based on the thesis by Dr. Marzieh Keshtkar. The authors also thank Dr. Vosoughi of the Dental Research Development Center, of the School of Dentistry for the statistical analysis.

Conflict of Interest

The authors disclose no potential conflicts of interest.

References

- [1] Turkeyilmaz I, Tözüm TF, Tumer C, Ozbek EN. Assessment of correlation between computerized tomog-

- raphy values of the bone, and maximum torque and resonance frequency values at dental implant placement. *J Oral Rehabil.* 2006; 33: 881-888.
- [2] Truhlar RS, Orenstein IH, Morris HF, Ochi S. Distribution of bone quality in patients receiving endosseous dental implants. *J Oral Maxillofac Surg.* 1997; 55 (12 Suppl 5): 38-45.
- [3] Schwartz-Arad D, Levin L, Ashkenazi M. Treatment options of untreatable traumatized anteriormaxillary teeth for future use of dental implantation. *Implant Dent.* 2004; 13: 120-128.
- [4] Teughels W, Merheb J, Quirynen M. Critical horizontal dimensions of interproximal and buccal bone around implants for optimal aesthetic outcomes: a systematic review. *Clin Oral Implants Res.* 2009; 20 Suppl 4: 134-145.
- [5] Artzi Z, Nemcovsky CE, Bitlitum I, Segal P. Displacement of the incisive foramen in conjunction with implantplacement in the anterior maxilla without jeopardizing vitality of nasopalatine nerve and vessels: a novel surgical approach. *Clin Oral Implants Res.* 2000; 11: 505-510.
- [6] Chatriyanuyoke P, Lu CI, Suzuki Y, Lozada JL, Rungcharassaeng K, Kan JY, et al. Nasopalatine canal position relative to the maxillary central incisors: a cone beam computed tomography assessment. *J Oral Implantol.* 2012; 38: 713-717.
- [7] Shiratori LN, Marotti J, Yamanouchi J, Chilvarquer I, Contin I, Tortamano-Neto P. Measurement of buccal bone volume of dental implants by means of cone-beam computed tomography. *Clin Oral Implants Res.* 2012; 23: 797-804.
- [8] Liang X, Jacobs R, Martens W, Hu Y, Adriaensens P, Quirynen M, et al. Macro and microanatomical, histological and computed tomography-scan characterization of the nasopalatine canal. *J Clin Periodontol.* 2009; 36: 598-603.
- [9] Neves FS, Oliveira LK, Ramos Mariz AC, Crusóé-Rebello I, de Oliveira-Santos C. Rare anatomical variation related to the nasopalatine canal. *Surg Radiol Anat.* 2013; 35: 853-855.
- [10] Radlanski RJ, Emmerich S, Renz H. Prenatal morphogenesis of the human incisive canal. *Anat Embryol (Berl).* 2004; 208: 265-271.
- [11] Song WC, Jo DI, Lee JY, Kim JN, Hur MS, Hu KS, et al. Microanatomy of the incisive canal using three-dimensional reconstruction of microCT images: an ex vivo study. *Oral Surg Oral Med Oral Pathol Oral Radiol Endod.* 2009; 108: 583-590.
- [12] Jacobs R, Lambrechts I, Liang X, Martens W, Mraiwa N, Adriaensens P, et al. Neurovascularization of the anterior jaw bones revisited using high-resolution magnetic resonance imaging. *Oral Surg Oral Med Oral Pathol Oral Radiol Endod.* 2007; 103: 683-693.
- [13] Acar B, Kamburoğlu K. Morphological and volumetric evaluation of the nasopalatine canal in a Turkish population using cone-beam computed tomography. *Surg Radiol Anat.* 2015; 37: 259-265.
- [14] Al-Amery SM, Nambiar P, Jamaludin M, John J, Ngeow WC. Cone beam computed tomography assessment of the maxillary incisive canal and foramen: considerations of anatomical variations when placing immediate implants. *PLoS One.* 2015; 10: e0117251.
- [15] Mraiwa N, Jacobs R, Van Cleynenbreugel J, Sanderink G, Schutyser F, Suetens P, et al. The nasopalatine canal revisited using 2D and 3D CT imaging. *Dentomaxillofac Radiol.* 2004; 33: 396-402.
- [16] López Jornet P, Boix P, Sanchez Perez A, Boracchia A. Morphological Characterization of the Anterior Palatine Region Using Cone Beam Computed Tomography. *Clin Implant Dent Relat Res.* 2015; 17 Suppl 2: e459-e464.
- [17] Etoz M, Sisman Y. Evaluation of the nasopalatine canal and variations with cone-beam computed tomography. *Surg Radiol Anat.* 2014; 36: 805-812.
- [18] de Oliveira-Santos C, Rubira-Bullen IR, Monteiro SA, León JE, Jacobs R. Neurovascular anatomical variations in the anterior palate observed on CBCT images. *Clin Oral Implants Res.* 2013; 24: 1044-1048.
- [19] Jacobs R, Mraiwa N, Van Steenberghe D, Sanderink G, Quirynen M. Appearance of the mandibular incisive canal on panoramic radiographs. *Surg Radiol Anat.* 2004; 26: 329-333.
- [20] Lee JY, Jahng JW, Kim SM, Kim MJ, Lee JH. Simultaneous inferior alveolar nerve regeneration and osseointegration with a nerve growth factor-supplying implant: a preliminary study. *J Oral Maxillofac Surg.* 2015; 73: 410-423.
- [21] Vâlcu M, Rusu MC, Sendroiu VM, Didilescu AC. The lateral incisive canals of the adult hard palate - aberrant anatomy of a minor form of clefting? *Rom J Morphol Embryol.* 2011; 52: 947-949.
- [22] Thakur AR, Burde K, Guttal K, Naikmasur VG. Anato-

- my and morphology of the nasopalatine canal using cone-beam computed tomography. *Imaging Sci Dent.* 2013; 43: 273-481.
- [23] Safi Y, Moshfeghi M, Rahimian S, Kheirkhahi M, Es-lami Manouchehri M. Assessment of Nasopalatine Canal Anatomic Variations Using Cone Beam Computed Tomography in a Group of Iranian Population. *Iran J Radiol.* 2017; 14: e37028.
- [24] Bornstein MM, Balsiger R, Sendi P, von Arx T. Morphology of the nasopalatine canal and dental implant surgery: a radiographic analysis of 100 consecutive patients using limited cone-beam computed tomography. *Clin Oral Implants Res.* 2011; 22: 295-301.
- [25] Bernades-Mayordomo R, Guijarro-Martínez R, Hernández-Alfaro F. Volumetric CBCT analysis of the palatine process of the anterior maxilla: a potential source for bone grafts. *Int J Oral Maxillofac Surg.* 2013; 42: 406-410.
- [26] Ávila-Ruiz F, Ávila-Ruiz F, Cuello S, Hermo-Silla A, Aravena P. Sexual dimorphism in the incisive canal in humans: A literature review. *Journal of Oral Research.* 2014; 3: 57-61.
- [27] Fernández-Alonso A, Suárez-Quintanilla JA, Muínelo-Lorenzo J, Bornstein MM, Blanco-Carrión A, Suárez-Cunqueiro MM. Three-dimension-al study of nasopalatine canal morphology: a descriptive retrospective analysis using cone-beam computed tomography. *Surg Radiol Anat.* 2014; 36: 895-905.
- [28] Güncü GN, Yıldırım YD, Yılmaz HG, Galindo-Moreno P, Velasco-Torres M, Al-Hezaimi K, et al. Is there a gender difference in anatomic features of incisive canal and maxillary environmental bone? *Clin Oral Implants Res.* 2013; 24: 1023-1026.
- [29] Kajan ZD, Kia J, Motevasseli S, Rezaian SR. Evaluation of the nasopalatine canal with cone-beam computed tomography in an Iranian population. *Dent Res J (Isfahan).* 2015; 12: 14-19.
- [30] Jia X, Hu W, Meng H. Relationship of central incisor implant placement to the ridgeconfiguration anterior to the nasopalatine canal in dentate and partially edentulous individuals: a comparative study. *Peer J.* 2015; 3: e1315.