

Case Report

Bilateral Cystic Lesions Associated to Maxillary Erupted Dilated Odontomas: A Case Report

Mahmoodi A.^a, Shahidi Sh.^b, Houshyar Mar.^c, Houshyar Man.^d

^a Dept. of Periodontology, School of Dentistry, Shiraz University of Medical Sciences, Shiraz, IRAN

^b Dept. of Oral Radiology, School of Dentistry, Shiraz University of Medical Sciences, Shiraz, IRAN

^c Periodontist, Dental Center of Dastgheib Hospital, Shiraz University of Medical Sciences, Shiraz, IRAN

^d Dept. of Oral Radiology, School of Dentistry, Shiraz University of Medical Sciences, Shiraz, IRAN

KEY WORDS

Odontoma;
Cone beam computed
tomography;
Radicular cyst

Received Oct. 2011 ;
Received in revised form March 2012 ;
Accepted March 2012

ABSTRACT

The term 'Dilated Odontoma' is a malformation which most frequently occurs in the deciduous, permanent or supernumerary teeth. It can be diagnosed with deep invagination of the enamel inside the crown or root. In other words, the most extreme form of dens in the dente is known as "dilated odontoma".

Although dilated odontomas are usually asymptomatic, their eruption into the mouth can give rise to pain, inflammation, and infection.

This report is an attempt to describe the case of a 22-year-old female presenting with bilateral cystic lesions associated with erupted dilated odontomas of the maxilla.

The patient had no history of pain but she complained about a recurrent swelling which she was suffering from for about two years. Conventional radiographs showed bilateral cystic lesions associated with dilated odontomas. The findings were also confirmed by Dent Scan. The treatment plan consisted of surgical removal of the lesions, followed by histopathologic study in order to confirm the initial diagnosis.

* **Corresponding author.** Houshyar Mar., Address: Dental Center of Dastgheib Hospital, Shiraz University of Medical Sciences, Shiraz, IRAN Tel: 0711-6363174 Email: maral.houshyar@yahoo.com

Introduction

Odontomas are known as benign tumors of odontogenic origin, consisting of mesenchymal and epithelial dental elements. Based on histologic results, they are composed of different dental tissues, such as enamel, dentin, cementum and, in some cases, pulpal tissue [1-2]. Based on the latest classification of the World Health Organization (WHO, 2005), odontomas are of two types of complex and compound. Compound odontomas have different radiographic manifestations, such as regularly shaped, solitary or multiple small youth-like denticles in which all dental tissues are arranged in a more orderly pattern.

A complex odontoma manifests itself as an amorphous conglomeration of dental tissues which consist of enamel, dentin, cementum, pulp and enamel organ [3]. The complex one is twice as common as the com-

pound form. The most frequent location of compound odontoma is the anterior segment of the maxilla, over the crowns of unerupted teeth or between the roots of the erupted teeth.

Odontomas are usually unilocular and contain denticles which are manifested as multiple radiopaque, miniature tooth-like structures [4]. A dilated odontoma has been described as another type of odontoma, however, this is a single structure that can actually be the most advanced state of density in a tooth which results from infolding of the outer surface toward the interior of the tooth. This can occur in either the crown or the root during tooth development and may involve the pulp chamber or root canal and lead to the deformity of either the crown or the root [5].

Clinically, these are asymptomatic lesions which

often make alterations in the pattern of tooth eruption. The diagnosis is usually based on accidental radiological studies (panoramic and intraoral radiographs) or on discovering the cause of delayed tooth eruption [1-2, 4]. Spontaneous eruption of an odontoma is an exceptional circumstance which may lead to pain and inflammation of the adjacent soft tissues, or infection associated with suppuration. Surgical removal of the lesion in all cases is the treatment of choice which must be followed by histopathologic study to confirm the initial diagnosis [6-8].

Case Report

A 22-year-old woman with a request for treatment of her gum swelling on both maxillary sides was referred to the Department of Periodontics and Radiology of Shiraz Dental School in February 2010 (Figure 1). The clinical examination revealed a swelling on the face which was significant on the right side. The intraoral examination also revealed bilateral gingival swelling of the maxilla (that was more remarkable on the right side as shown in Figure 2). The patient had no history of pain but complained about having recurrent gingival swelling during the previous two years. Bilateral eruption of an unusual

tooth-like particle was also observed inside the oral cavity.

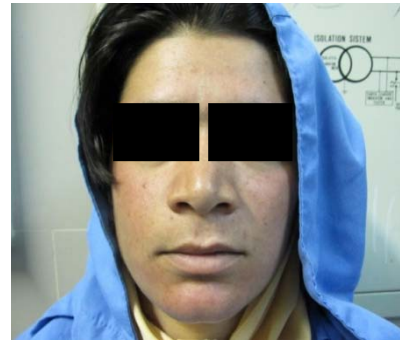

Figure 1 Clinical appearance of the patient with mild swelling of right maxilla in the region of nasolabial fold

Conventional radiographs (panoramic, occlusal and periapical) revealed bilateral cystic lesions associated with bilateral, erupted and dilated odontomas in the maxilla (Figures 3, 4).

The findings of cone beam computed tomography (CBCT) in establishing the precise location and extent of the lesions confirmed the findings of conventional radiographs (Figure 5). So, the definite diagnosis was bilateral radicular cystic lesions associated with erupted dilated odontomas. The patient

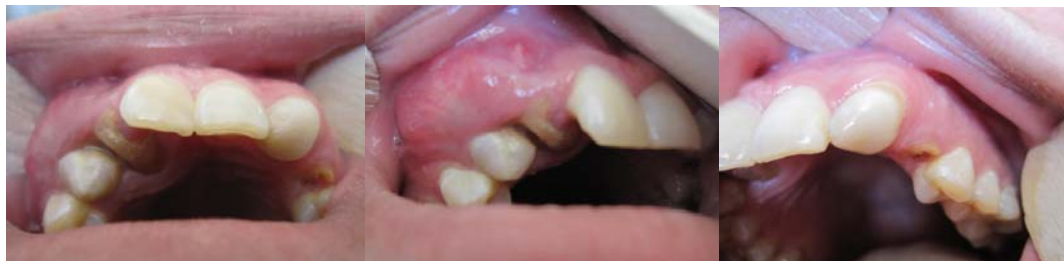

Figure 2 Intraoral views showing bilateral eruption of the lesion. Note the significant gingival swelling on the right side

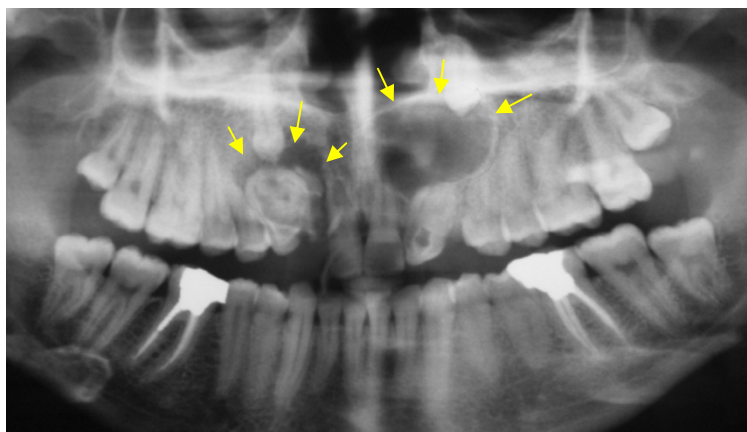


Figure 3 Panoramic view. Note the bilateral cystic odontomas in the maxilla.

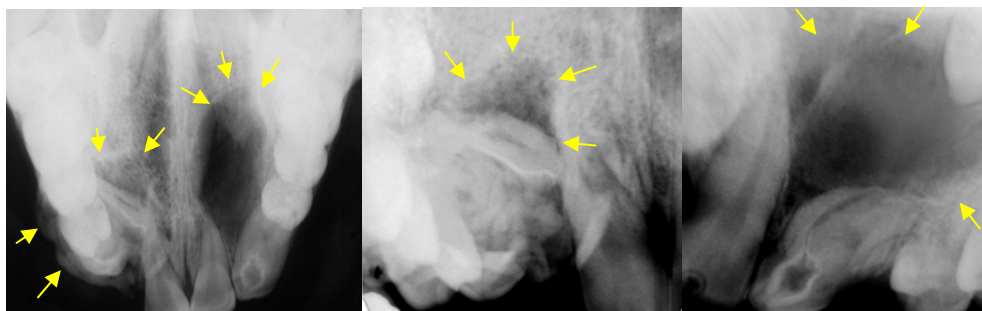


Figure 4 Occlusal and periapical radiographic views showing bilateral cystic lesions.

was scheduled for surgical procedure under general anaesthesia and the lesions were enucleated. The specimen was sent for histopathologic examination and the initial diagnosis was confirmed by histopathologic results.

Discussion

As it is known, odontomas are the most frequent benign odontogenic tumors of the maxillofacial region.

They are generally asymptomatic and diagnosed on the course of routine radiologic studies, especially in the 2nd and 3rd decades of a person's life. Odontomas can be divided into two types: intraosseous and extraosseous. The former occurs inside the bone and may erupt into the oral cavity (erupted odontoma), while the latter (peripheral odontomas) occurs in the soft tissue [9]. Although odontomas are generally intraosseous lesions, in exceptional cases, they may spontaneously erupt into the oral cavity [8, 10].

Based on literature review since 1980, only 20 cases of erupted odontomas were reported in the literature. Of these 20 cases, 12 (60%) were female and 7 (35%) were male. The average age of the patients was 25.35 years which was in line with the fact that the lesions occur more often in the second and third decades of one's life [1, 4, 11-12].

Of the 20 documented cases of erupted odontomas, 9 were related to compound odontomas and 11 to complex ones. None of the mentioned cases were bilateral. To the authors' best of knowledge, our case has been the only bilateral erupted odontoma with cystic lesions in human until February 2010. According to the literature, there have been several cases of bilateral odontoma in lab animals.

The first case describes the morphological features of spontaneous, bilateral complex odontoma of the incisor teeth in a 87-week-old male Swiss mouse. This was the first case describing a bilateral complex

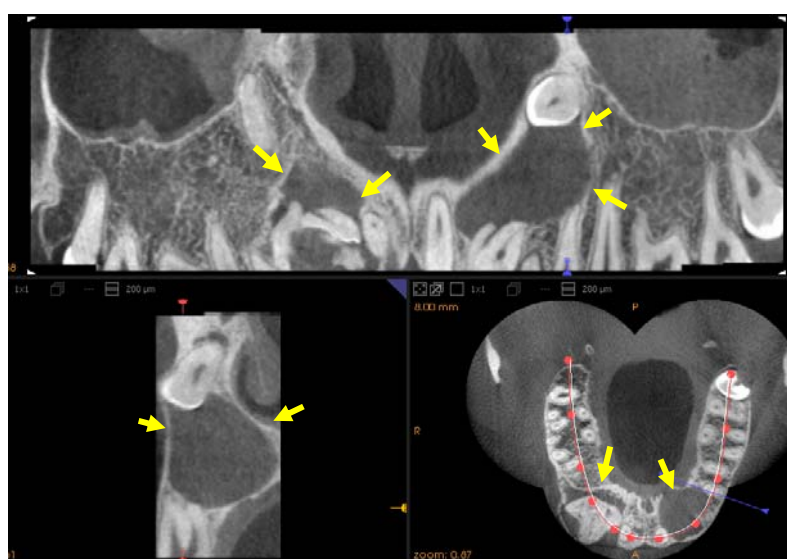


Figure 5 Cone Beam CT showing the frontal (panoramic reconstruction), the sagittal (lower left), and the axial (lower right) view of the lesion

odontoma in this breed of mice. It should be mentioned that bilateral odontoma of this case had not erupted into the mouth [13].

But in the second case, bilateral odontoma was erupted into the mouth and, to the authors' knowledge, it is the only case of bilateral odontoma which has erupted into the oral cavity in lab animals. This case, which has been reported by Hannover School of Veterinary Medicine in Germany, describes bilateral erupted odontoma in a six-month-old, male black Russian terrier dog which manifested oral masses on the distolingual aspect of the mandibular left and right first molar teeth. In the radiographic examination, periodontal support of the small teeth (denticles) was detected. No other abnormality was found in the oral and radiographic examinations of the other teeth. The denticles resembled small teeth in histomorphologic features, including normal appearing crowns and root structures. Based on clinical and histopathologic examinations, diagnosis of bilateral compound odontoma with completely erupted denticles was confirmed [14].

As mentioned previously, eruption of odontoma into the oral cavity is symptomatic and may cause pain, inflammation and infection. The signs and symptoms of erupted odontomas (except having pain) for our case are similar to those documented in the literature. Some other findings which have been reported in association with erupted odontoma consist of facial asymmetry [9], halitosis [15], malocclusions [16-17] and recurrent infections [18].

The case of a 22-year-old female with several infection episodes related to an erupted odontoma in the maxilla and presented with symptoms, including malaise, fever, pain, inflammation and suppuration was reported by Ferrer et al. [6]. First of all, a broad spectrum of antibiotic therapy of the infection, including amoxicillin, clavulanic acid and clindamycin was prescribed. Then, surgical resection of odontoma, together with removal of the tooth was carried out. Subsequently, clinical manifestations disappeared [6].

So, the serious conditions in the presence of super-infection of the lesions associated with erupted odontomas (swelling and inflammation), as it has been mentioned in this study, must be considered.

Odontomas are usually associated with alterations in the permanent or temporary tooth eruption. An

incidence rate of this association ranges from 41% to 87% [19] in a series of 396 odontomas [4, 19].

Although there is no general agreement on the management of these erupted odontomas [11, 20], the treatment options consist of surgical extraction, fenestration and posterior orthodontic traction, followed by periodic clinical and radiological controls in order to evaluate the course of these teeth [2, 19-20]. However, generally the treatment of choice for these erupted odontomas appears to be removal of the lesion with preservation of any impacted tooth if existent. Clinical and radiological follow up for at least 1 year is also recommended [4, 8, 20].

Conclusion

Odontomas seldom erupt into the mouth and are almost always associated with impacted teeth. Unlike most of the odontomas, the above case shows that if erupted odontoma becomes cystic, it may lead to moderately serious conditions, especially in the presence of super infection of the lesion. The effective treatment of choice in our case and such similar cases is surgical removal of the lesion followed by histologic analysis.

References

- [1] Jung M. Endodontic treatment of dens invaginatus type III with three root canals and open apical foramen. *Int Endod J* 2004; 37: 205-213.
- [2] Amado Cuesta S, Gargallo Albiol J, Berini Aytés L, Gay Escoda C. Review of 61 cases of odontoma. Presentation of an erupted complex odontoma. *Med Oral* 2003; 8: 366-373.
- [3] Reichart PA, Philipsen HP. Illustrated Compound Odontoma, in odontogenic tumors & lesions. 1th ed., Quintessence: 2004. p.149-153.
- [4] Tomizawa M, Otsuka Y, Noda T. Clinical observations of odontomas in Japanese children: 39 cases including one recurrent case. *Int J Paediatr Dent* 2005; 15: 37-43.
- [5] White SC, Pharoah MJ. *Oral Radiology Principles and Interpretation*. 6th ed., China: Mosby; 2009. p.366, 378.
- [6] Ferrer M, Silvestre F, Estelles E, Grau D. Infection recurrent de un odontoma complejo tras su apertura a la boca. *Med Oral* 2001; 6: 269-275.
- [7] Junquera L, de Vicente JC, Roig P, Olay S, Rodríguez-Recio O. Intraosseous odontoma erupted into the oral cavity: an unusual pathology. *Med Oral Patol Oral Cir*

- Bucal 2005; 10: 248-251.
- [8] Litonjua LA, Suresh L, Valderrama LS, Neiders ME. Erupted complex odontoma: a case report and literature review. *Gen Dent* 2004; 52: 248-251.
- [9] Vengal M, Arora H, Ghosh S, Pai KM. Large erupting complex odontoma: a case report. *J Can Dent Assoc* 2007; 73: 169-173.
- [10] Ragalli CC, Ferreria JL, Blasco F. Large erupting complex odontoma. *Int J Oral Maxillofac Surg* 2000; 29: 373-374.
- [11] Cildir SK, Sencift K, Olgac V, Sandalli N. Delayed eruption of a mandibular primary cuspid associated with compound odontoma. *J Contemp Dent Pract* 2005; 6: 152-159.
- [12] Hisatomi M, Asaumi JI, Konouchi H, Honda Y, Wakasa T, Kishi K. A case of complex odontoma associated with an impacted lower deciduous second molar and analysis of the 107 odontomas. *Oral Dis* 2002; 8: 100-105.
- [13] Dayan D, Waner T, Harmelin A, Nyska A. Bilateral complex odontoma in a Swiss (CD-1) male mouse. *Lab Anim* 1994; 28: 90-92.
- [14] Eickhoff M, Seeliger F, Simon D, Fehr M. Erupted bilateral compound odontomas in a dog. *J Vet Dent* 2002; 19: 137-143.
- [15] Gomel M, Seçkin T. An erupted odontoma: case report. *J Oral Maxillofac Surg* 1989; 47: 999-1000.
- [16] López-Areal L, Silvestre Donat F, Gil Lozano J. Compound odontoma erupting in the mouth: 4-year follow-up of a clinical case. *J Oral Pathol Med* 1992; 21: 285-288.
- [17] Nik-Hussein NN, Majid ZA. Erupted compound odontoma. *Ann Dent* 1993; 52: 9-11.
- [18] Al-Sahhar WF, Putrus ST. Erupted odontoma. *Oral Surg Oral Med Oral Pathol* 1985; 59: 225-226.
- [19] Katz R. An analysis of compound and complex odontomas. *J Dentist Child* 1989; 56: 445-449.
- [20] Frank C. Treatment options for impacted teeth. *J Am Dent Assoc* 2000; 131: 623-632.