

Case Report

Chronic Multifocal Inflammation of the Alveolar Bone Mimicking Malignancy: A Case Report

Shahidi Sh.^a, Bronoosh P.^b, Zamiri B.^c, Daneshbod Y.^d

^a Dept. of Oral Radiology, Biomaterial Research Center, School of Dentistry, Shiraz University of Medical Sciences, Shiraz, IRAN

^b Dept. of Oral Radiology, School of Dentistry, Shiraz University of Medical Sciences, Shiraz, IRAN

^c Dept. of Oral Surgery, School of Dentistry, Shiraz University of Medical Sciences, Shiraz, IRAN

^d Pathologist

KEY WORDS

Chronic Osteomyelitis;
Multifocal;
Malignant Condition.

Received Sept. 2011;
Received in revised form Dec.2011;
Accepted Jan.2012

ABSTRACT

Chronic inflammation of the alveolar bone is a great clinical and radiologic mimic, which merits recognition by the clinician and pathologist. The patient can thus be reassured of the proper early treatment and a favorable prognosis. Occasionally, it is difficult to differentiate inflammatory lesions from malignant tumors. The aim of this report is to present a case with an inflammatory lesion mimicking malignant condition.

We report a 19-year-old male complaining of rapid onset gingival swelling of the right side of both jaws and looseness of the right upper molar teeth in 20 days. Based on the acute onset of the gingival hyperplasia, severe looseness of the affected teeth especially in the maxilla, and the patient's age, multifocal rapid growing malignant condition was not ruled out. The lesion was misdiagnosed as a malignant condition by clinical and radiographic examination. The whole body bone scan showed no significant increased uptake in the right oral cavity compatible with no active bony pathology. The surgical pathology findings of the lesion showed severe chronic inflammation with surface epithelial hyperplasia.

The initial diagnosis of the lesion was malignant condition but it was ruled out by bone scan and histological appearance.

* **Corresponding author.** Bronoosh P., Address: Dept. of Oral Radiology, School of Dentistry, Shiraz University of Medical Sciences, Shiraz, IRAN; Tel: 0711-6263192; Fax: 0711-6270325; Email: pegah_brix@yahoo.com

Introduction

Inflammatory lesions are by far the most common pathologic condition of the jaws. The jaws are unique from other bones of the body in that the presence of teeth creates a direct pathway for infections and inflammatory agents to invade the bone by means of caries and periodontal disease [1]. Chronic inflammation of the alveolar bone is a great clinical and radiologic mimic, which merits attention by the clinician and pathologist. The patient can thus be reassured of the proper early treatment and a favorable prognosis [2].

Osteomyelitis is uncommon in the immunocompetent host. Considering the high incidence of local infections in the craniomaxillofacial

region (e.g. sinusitis, pharyngitis, periodontitis) and the potentially pathogenic bacteria present in the upper aerodigestive tract, it is surprising that bone infection is not seen more frequently. One explanation for this may be the excellent blood supply normally present in this region. The inherent resistance of the host might account for the condition [3].

On the contrary, osteomyelitis is seen more frequently in the immune compromised patients (i.e. those on immunosuppressive drugs or those who have leukemia or agranulocytosis) and more frequently in patients with vascular insufficiency [3].

Moreover, soft tissue masses are infrequent in chronic osteomyelitis which is usually diagnosed clinically by a combination of radiological and

microbiological characteristics [4].

Occasionally, it is difficult to differentiate inflammatory lesions from malignant tumors. The aim of this report is to present a case with an inflammatory lesion mimicking a malignant condition.

Case Report

We report a 19-year-old male complaining of rapid onset gingival swelling and looseness of the right upper molar teeth within 20 days. Intraorally, there was a large, smooth, exophytic mass occupying the entire upper right oral cavity. The molar teeth both in the right upper and lower jaw were mobile. In the right mandible, gingival swelling with laceration was noted, as seen in advance periodontal disease. There was no pain, paresthesia, dental calculi or evidence of dental carious lesion, bleeding or tenderness.

A panoramic radiograph revealed two separate bony defects in the right side of both jaws (Figure 1). There was severe bone destruction with a ground glass pattern and “hanging in air” molar teeth with significant displacement of the second molar in the right upper quadrant. However, the inferior border of the maxillary sinus was visible and intact. The right mandible showed significant bone loss with furcation involvement around the mandibular first and second molars as well as the distal aspect of the second premolar. Follicular spaces of the third molars in both quadrants were within normal limits.

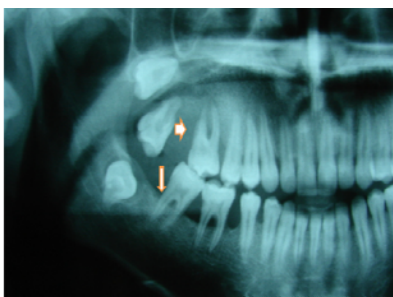

Figure 1 Cropped panoramic radiograph revealed two separate bony defects in the right side of both jaws

Based on acute onset of gingival hyperplasia in the two sites, and severe looseness of the affected teeth especially in the maxilla, a multifocal rapid growing malignant condition such as Burkitt lymphoma was not ruled out. Axial computed tomography (CT) scan revealed expansion of right maxillary lingual plate and

destruction of buccal cortical plate around the molar teeth without any evidence of sequestrum (Figure 2).

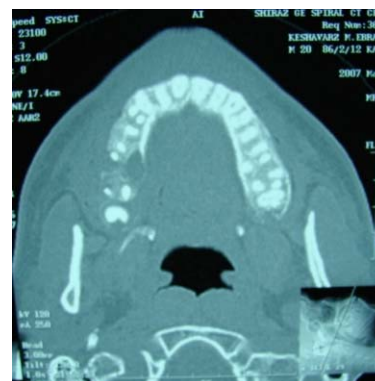

Figure 2 Axial CT scan showed buccal cortical destruction around the molar teeth with a cystic like expansion in the lingual plate of the same region.

Again malignancy was suspected. A technetium whole body bone scan revealed no significant increased uptake in the right oral cavity compatible with no active bony pathology as well as no sign of inflammation in the entire body (Figure 3). To further clarify the diagnosis, biopsies were performed including a biopsy of the affected bone and a biopsy of the soft tissue lesion.

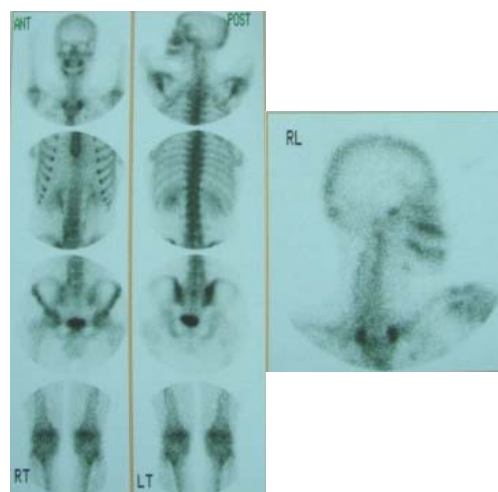


Figure 3 No active bony pathology as well as no sign of inflammation entire body technetium bone scan

Histologically, a severe chronic inflammatory reaction affecting the bone, the periosteum and surrounding tissue with surface epithelial hyperplasia consisting of predominantly lymphocytes was diagnosed. Reparative changes of the osseous tissue

(marrow fibrosis, trabecular osteoid apposition, periosteal hyperostosis) were not recognized and malignancy was ruled out. In addition, extensive microbial investigation (standard culture techniques to detect fungi, mycobacteria, aerobic and anaerobic bacteria) was done and the lesion was sterile. Standard laboratory tests included blood count, erythrocyte sedimentation rate (ESR), C reactive protein (CRP), serum ferritin, serum IgG, IgM, IgA, calcium, phosphorus and alkaline phosphatase checked normal.

Discussion

Histologic changes correlated poorly with clinical features and radiologic findings of the present case. The evidence of malignancy was destruction of the alveolar bone around the molar teeth without any evidence of sequestrum, wide zone of transition on X-ray and ill-defined margin of swelling, variegated consistency especially in the upper jaw and venous prominence over the swelling. Unfortunately, the patient did not allow us to take photography of the clinical appearance.

With regard to multifocal nature of the lesion, different radiographic appearance of the lesion in the two quadrants and coincidence of tooth looseness as the chief complaint in both jaws in a short period of time along with patient age, differential diagnosis included several entities including bone malignancies like Burkitt's lymphoma, Ewing's sarcoma, histiocytosis, rhabdomyosarcoma and osteosarcoma.

After exclusion of malignancy and based on inflammation in histopathology report, with respect to multifocal occurrence, sterile bone lesions was diagnosed. With non-specific signs of inflammation in the bone scan, the descriptive diagnosis of Chronic Non-bacterial multifocal Osteomyelitis (CNO) was made.

Inflammation of the bone can be initiated from a contiguous focus of infection or from a hematogenous source. The hematogenous route is a more common source for osteomyelitis in the long bones of children; however, in the maxillofacial region, spread from a contiguous source is the more typical etiology [4]. Thus, patients with craniomaxillofacial osteomyelitis often give the history or present with clinical findings indicating periodontal infection, sinusitis, and/or

trauma. No cause could be identified or any reason determined for this case occurrence which stressed the misdiagnosis of malignancy.

As stated before, osteomyelitis is seen more frequently in vascular and immune compromised patients. The patient was checked for any vascular and immune system disorders (e.g. diabetes mellitus, sickle cell anemia, atherosclerosis, fibrous dysplasia, bone malignancy, Paget's disease, osteopetrosis, history of radiation therapy or exposure to the bone necrosing chemicals mercury, bismuth, and arsenic), that was inconclusive.

There have been few reports stating that the bone can be inflamed chronically in hypophosphatasia [5]. Therefore, co presentation of chronic nonbacterial osteomyelitis (CNO) and hypophosphatasia (HP) in which CNO can have a uni- or multifocal occurrence had to be considered in our patient. So, laboratory tests to titer calcium, phosphorus and alkaline phosphatase were performed for the patient, all being within the normal range. In this regard, it is of importance that multifocal CNO can also cause hyperostosis and osteolytic lesions. Thus, it can be misdiagnosed as malignancy and vice versa [2].

Rarely, a primary bone neoplasm mimics chronic inflammation of the bone. A case of Burkitt's lymphoma that presented initially with resorption of the alveolar bone was reported by Mitsudo [6] in which there was resorption of the alveolar bone and loss of teeth lamina dura in the panoramic image of a 16-year-old male within 1-month period.

On the other hand, infection may simulate a malignant bone tumor radiographically and pathologically. A case of severe inflammation with an exuberant granulation lesion of the larynx that mimicked laryngeal tumor was reported by Manohar in a chronic smoker patient [7].

To reemphasize the problem, the pathologist must have all the clinical information and X-rays before attempting a diagnosis of a bone tumor; otherwise, errors are almost inevitable. In addition, a microbial workup has to be as detailed and as extensive as possible to exclude the rare chronic bacterial osteomyelitis and to avoid unnecessary long-term antibiotic treatment.

Even though antibiotic treatment has so far been

traditionally recommended for CNO, in general, antibiotic treatment is considered ineffective. In contrast, treatment with non-steroidal anti-inflammatory drugs (NSAIDs) has been reported to be effective [4].

Since for the developing countries' context we have to treat the patients in limited resources, awareness of the spectrum of histologic features encountered enables a correct diagnosis to be made in the appropriate clinical setting.

A distinction between "acute" and "chronic" osteomyelitis is difficult on both clinical and histopathologic grounds. It seems that the definition of chronic lesions according to duration and clinical signs may be revised when facing such complicated cases.

Conclusion

The report merits attention only because there was no clinical and radiographic sign of infection. This case report illustrates some serious diagnostic problems. At first, chronic inflammatory bone lesions can mimic bone tumors, soft tissue tumors and haematological malignancies. Then, diagnostic imaging (CT, bone scan) might not be sufficient enough to make a proper diagnosis. Therefore, the diagnosis often has to be biopsy proven. However, the quality of the biopsy depends significantly on whether representative areas of the lesion are included.

References

- [1] Linda Lee. Inflammatory lesions of the jaws. In: White SC, Pharoah MJ: Oral radiology: principles and interpretation. 6th ed., Mosby Elsevier: China; 2009. p. 331-335
- [2] Kumar P, Singh GK, Singh MP, Pandey S. Pyogenic chronic osteomyelitis mimicking Malignancy. Nigerian J Orthopaedics and Trauma 2006; 5: 54-55.
- [3] Wright DL, Kellman RM. Craniomaxillofacial Bone Infections: Etiologies, Distributions, and Associated Defects. Craniomaxillofac Reconstructive Correct Bone Surg 2002; 1: 76-89.
- [4] Girschick HJ, Raab P, Surbaum S, Trusen A, Kirschner S, Schneider P, et al. Chronic non-bacterial osteomyelitis in children. Ann Rheum Dis 2005; 64: 279-285.
- [5] Girschick HJ, Mornet E, Beer M, Warmuth-Metz M, Schneider P. Chronic multifocal non-bacterial osteomyelitis in hypophosphatasia mimicking malignancy. BMC Pediatr 2007; 7: 3.
- [6] Mitsudo K, Tohnai I, Hayashi Y, Ueda M, Yambe M, Hirose Y. A case of Burkitt's lymphoma that presented initially with resorption of alveolar bone. Oral Dis. 2000; 6: 256-228.
- [7] Manohar MB, Saleem M, McArthur P, Tulbah A. Laryngeal inflammation mimicking laryngeal carcinoma. J Laryngol Otol 1997; 111: 568-570.