

Original Article**Influence of Head Position on the CBCT Accuracy in Assessment of the Proximity of the Root Apices to the Inferior Alveolar Canal**Sadaf Adibi¹, Shoaleh Shahidi², Saeed Nikanjam³, Maryam Paknahad⁴, Mohammadali Ranjbar⁵¹ Dept. of Oral and Maxillofacial Radiology, School of Dentistry, Shiraz University of Medical Sciences, Shiraz, Iran.² Dept. of Oral and Maxillofacial Radiology and Biomaterials Research Center, School of Dentistry, Shiraz University of Medical Sciences, Shiraz, Iran.³ Undergraduate Student, Student Research Committee, Research Committee, School of Dentistry, Shiraz University of Medical Sciences, Shiraz, Iran.⁴ Oral and Dental Disease Research Center, Dept. of Oral and Maxillofacial Radiology, School of Dentistry, Shiraz University of Medical Sciences, Shiraz, Iran.⁵ Dept. of Oral and Maxillofacial Pathology, School of Dentistry, Shiraz University of Medical Sciences, Shiraz, Iran.**KEY WORDS**Cone beam computed tomography;
Head;
Inferior alveolar nerve;
Tooth apex;**ABSTRACT****Statement of the Problem:** The most important risk factor for inferior alveolar nerve (IAN) damage is the proximity of the mandibular root apices to the alveolar canal. Failure to position the patient's head at standardized orientation during cone beam computed tomography (CBCT) scans might adversely affect the relative position of the alveolar canal and mandibular root apices with subsequent treatment failure.**Purpose:** The purpose of the present study was to investigate the influence of the orientations of the skull during the scanning procedure on the accuracy of CBCT images in determining the positional relationship of the mandibular tooth apices to the alveolar canal.**Materials and Method:** CBCT scans of 7 human dry skulls were obtained by using NewTom VGi CBCT in standard, tilt, flexion, extension and rotation positions of the head. The shortest radiographic distance between the mandibular tooth apices and the IAN canal of 20 points were measured on cross sectional images of CBCT in all position scans. A sample t-test was used to compare the measurements at different head position with the standard position values.**Results:** Significant differences were found in the measurements of normal and tilt orientations. However, there was no statistically significant difference between the measurements in standard position and other deviated positions. The mean errors in all head positions were less than 0.5mm.**Conclusion:** Alteration of patient head positioning during CBCT scanning does not affect the relative position of the IAN and the apices of posterior teeth.**Corresponding Author:** Paknahad M., Dept. of Oral and Maxillofacial Radiology, School of Dentistry, Shiraz University of Medical Sciences, Shiraz, Iran. Tel: +98-71-32292680 Fax: +98-71-32292680 Email: paknahadmaryam@yahoo.comReceived May 2016;
Received in Revised form August 2016;
Accepted October 2016;Cite this article as: Adibi S., Shahidi Sh., Nikanjam S., Paknahad M., Ranjbar MA. Influence of Head Position on the CBCT Accuracy in Assessment of the Proximity of the Root Apices to the Inferior Alveolar Canal. *J Dent Shiraz Univ Med Sci.*, 2017 September; 18(3): 181-186.**Introduction**

Iatrogenic damage to the inferior alveolar nerve (IAN) with subsequent neurosensory disturbances is a serious complication associated with various dental procedures, such as third molar extraction, endodontics treatment,

implant placement and orthognathic surgery. [1] The proximity of the IAN to the root apices plays a major role in the occurrence of IAN damage. It has been suggested that the risk for IAN injury increases dramatically when the distance between the canal and root struc-

tures becomes smaller. [2] Therefore, preoperative assessment of the relative position of the IAN and the apices of posterior teeth is very crucial for minimizing the risk of nerve injury. [3]

Cone beam computed tomography (CBCT) is a new developed imaging technique that allows three-dimensional (3D) reconstructions of the maxillofacial structures with high resolution and without any superimposition. [4-7] Patient head positioning during CBCT image acquisition is an important factor, which may have a significant influence on the accuracy of CBCT measurements. Previous studies have shown when patient's head is oriented correctly; CBCT provides precise linear measurement, which is comparable to physical measurements. [8-11] Poor patient positioning during CBCT scanning procedures, as a common clinical occurrence in everyday practice, might adversely affect the measurement accuracy of linear distances between the canal and root tips with subsequent treatment planning failure and IAN damage. There is an inconsistency in the literature regarding the influence of patient positioning on the CBCT measurements accuracy. [12-17] Some studies have reported that incorrect positioning the patient during CBCT scanning causes measurement errors. [12-16] However, other studies suggested that incorrect patient head orientation during image acquisition does not affect the measurements accuracy of the craniofacial complex on CBCT images. [17-18] To the best of our knowledge, there is little information in the literature evaluating the influence of incorrectly positioning the patient during CBCT image acquisition on cross sectional reformatting used to determine the relation of the mandibular teeth and IAN canal. [13, 15, 17] Therefore, the aim of the present study was to evaluate whether changes in skull orientation in the scanner affects the anatomical distance between IAN canal and the mandibular root apices.

Materials and Method

Radiographic scan

The present study was approved by the institutional ethics committee. Ten randomly selected dry mandibles were used in this study. Lateral cephalograms were obtained from each mandible (using Planmeca Proline, Helsinki, Finland) at 68 KV, 1.4 s and 12 mA. 20 points in which close relationship of tooth and mandibular

canal were suspected based on Rood's criteria (darkening of root, deflection of root, narrowing of root, bifid root apex, diversion of canal, narrowing of canal, interruption in white line of canal) were chosen. Seven blocks containing the 20 points were separated from the mandibles. A human phantom skull was prepared in order to place the separated blocks in its mandible. The phantom was placed on a holder with the ability to simulate all head orientations. Two lines parallel to the axial and sagittal planes (lines a and b) were drawn on the skull so that the amount of variation in head position could be measured (Figure 1).

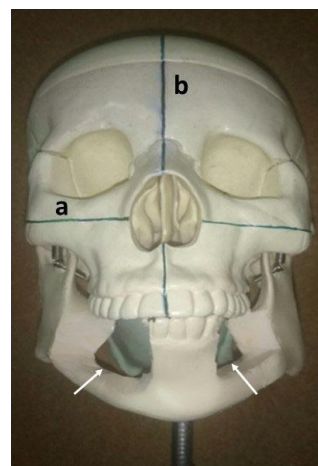


Figure 1: A phantom skull in which line a indicates axial plane and line b indicates sagittal plane. Cavities were prepared for the mandibular blocks (white arrows).

Then, the radiographic scans for each skull were made by same clinician using a NewTom VGi CBCT imaging unit (QR-SRL, Verona, Italy) operated at 110 KVP, 2.04 mA, exposure time of 3.6 S and a field of view of 8×12cm in 5 different head positions:

1. Standard position: following the manufacture's recommendations, the researchers centered the skull in the focal trough with the Frankfort plane parallel to the floor and the mid-sagittal plane perpendicular to the floor.
2. Flexion position: the skull was rotated toward the anterior side by 15-degree downward direction compared to the ideal position. The laser line of the device made a 15-degree angle with line a.
3. Extension position: the skull was rotated 15 degrees upward compared to the ideal position. Laser line of the device made a 15-degree angle with line a.
4. Tilt position (to the same side where the block was mounted): the skull was tilted laterally as much as

15 degrees, compared to the ideal position. Laser line of the device made a 15-degree angle with line b.
 5. Rotation position (to the same side where the block was mounted): the skull was rotated 15-degree, compared to the ideal position. Laser line of the device made a 15-degree angle with line b.

CBCT measurements

Two oral and maxillofacial radiologists evaluated the CBCT images simultaneously. The cross sectional images of each head position scanning were reconstructed at 0.5mm slice interval and 0.5mm slice thickness. On these serial cross-sectional images, the shortest distance from the selected root apex to the superior border of the IAN was measured using NNT viewer software with the accuracy rate of 0.1mm (Figure 2). All images were re-evaluated over the two-week interval by the same observers to assess the significance of any errors during measurements.

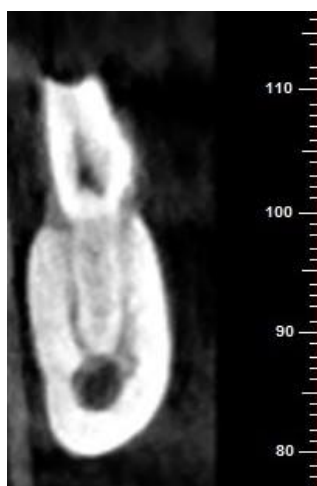


Figure 2: Cross sectional CBCT views for measurement of the distance from the tooth apex to the mandibular canal in a sample

Statistical analysis

All data were analyzed with the SPSS program, version 18 (SPSS Inc., Chicago, IL USA). The results of the first and second series of measurements were compared, using the inter class correlation coefficient (ICC) to assess the inter-observer reliability of measurements. In addition, a paired sample t-test was used to determine any significant differences between dual measurements. The measurements obtained from normal-head-position images were considered as the gold standard. The difference between normal position and other head orientations measurements was assessed. Positive value represents that the tested position overestimated the real

measurements obtained in the standard position; negative values indicates that the tested positions underestimated the values obtained in ideal position. Finally, to evaluate the influence of skull orientation during scanning, the researchers performed measurements on the CBCT images of different head orientations and compared them with those conducted on the standard position, using independent sample t-test at the significance level of 0.05.

Results

ICC showed that intra observer reliability was high ($r > 0.90$) and there were no significant differences between the first and second series of measurements ($p > 0.05$). Therefore, the average of dual measurements was used for further analysis to minimize the error in the measurements. The frequency of underestimation (the measured distance of deviated position was smaller than that of normal position) and overestimation for various head orientations is presented in Figure 3.

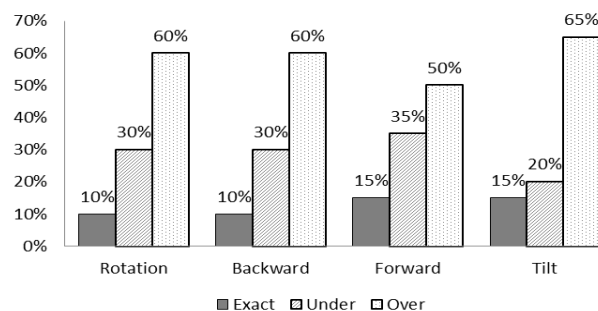


Figure 3: The frequency of underestimation and overestimation for various head orientations

The mean difference \pm SD of the measurements for each head orientations are presented in Table 1.

Table 1: The mean difference \pm SD of the measurements for each head orientations

Head orientation	Mean difference (mm) \pm SD	p Value
Tilt	0.19 \pm 0.35	0.02*
Rotation	0.02 \pm 0.48	0.82
Extension	0.13 \pm 0.56	0.29
Flexion	0.11 \pm 0.50	0.32

SD: standard deviation
 * p Value less than 0.05 was considered statistically significant.

Significant differences were found in the measurements of normal and tilt orientations. However, there was no statistically significant difference between the measurements in standard position and other deviated positions. The mean errors were smaller than 0.5mm for

all head orientations that is insignificant clinically.

Discussion

Erroneous estimation (underestimation or overestimation) of the positional relationship of the IAN canal to mandibular teeth can cause inadvertent injury to neurovascular bundles. Patient head positioning during CBCT image acquisition is an important factor, which may have a significant influence on the accuracy of CBCT measurements. Patient head orientation may inadvertently deviate from the standard head positioning which may lead to changes in the image size with consequent distortion of the image. In a study by Gianluigi Frongia *et al.*, [12] the effect of skull orientation on 3D cephalometric measurements of CBCT images was evaluated. They believed that even if the statistical analysis showed no significant differences, the difference found should be considered significant for a correct diagnosis from a clinical point of view. This issue is even more important for preoperative assessment of proximity of IAN canal to root apices since a quite shorter distance is being measured and the submillimeter inaccuracy may lead to inadvertent nerve injury. Bou Serhal *et al.*, [18] have suggested that improper patient positioning during scanning may result in measurement errors in multiplanar reformatting (MPR) cross sectional images, which are not fully perpendicular to the inferior border of mandible, which leads to inaccurate distance measurement between the apex and the mandibular canal.

Little is known about the influence of incorrectly positioning the patient during CBCT image acquisition on cross sectional reformatting used to determine the relation of the mandibular teeth and IAN canal needed for different dental procedures. There is an inconsistency in the literature regarding the influence of patient positioning on the CBCT measurements accuracy. In the present study, although the mean differences between tilt position measurements and standard position measurements were statistically significant, no statistically significant difference between the measurements in standard position and other deviated positions were found. This similarity supports the findings of previous studies suggesting that incorrect patient head orientation during image acquisition does not affect the measurements accuracy of the craniofacial complex on CBCT images. The absence of spatial distortion during various

head orientations may be related to the isotropic nature of voxels creating the CBCT images. [19] However, other studies have reported that incorrectly positioning the patient during CBCT scanning causes measurement errors. [12-16] The variability in the results of previous studies may be due to the extent of head deviation, the number of measurements, the length of measured distances, difference in the scanning protocol and the CBCT machine used. In the present study, the measurements were carried out on cross sectional images on the curve of the mandible between the points within the bone. However, several previous studies measured the distance between the external points on the skull. [12, 20-25] This difference can significantly affect the accuracy of findings. Few studies in the literature assessed the effect of patient's head positioning on the accuracy of cross sectional CBCT measurements. Dalili *et al.*, [17] found no significant differences between the height and width measurement of mandibular bone in different head orientations compared with the standard position. They mentioned that the difference of CBCT measurements in various head positions, compared with actual ones, was in the range of acceptable value (<0.5mm). These results are in line with our findings. Sabban *et al.*, [15] found a statistically significant difference between the mean errors in vertical measurements with greatest discrepancy of the extension head orientation, ranging between -2 to 3mm. No statistically significant difference was found between the mean errors in horizontal measurements. Sheikhi *et al.*, [13] showed a significant difference between physical measurements and radiographic ones at different deviated positions. However, the discrepancy of measurements in various head positions was less than 0.5mm. Visconti *et al.*, [16] demonstrated that head orientation could significantly affect the measurement reliability of CBCT images. Likewise, Nikneshan *et al.*, [14] found that changing the slice orientation in the range of -12 to +12° reduced the accuracy of CBCT measurements.

In the present study, the mean differences between various position measurements and standard position measurements were even less than voxel sizes. This finding is consistent with findings of many previous studies [13-14, 19-20] showing that the mean error value of less than 1 mm in different head positioning was considered clinically insignificant. Mean measurement

error was significantly higher for tilt position, compared with standard position. Sheikhi *et al.*, [13] showed rotation and flexion positions are the deviations having the most impact on the accuracy of measurements on CBCT. [13] In another study by Sabban *et al.*, [15] the mean measurement error between the standard and extension head position was different significantly.

Underestimation of the distance to the IAN canal is safer than overestimation. Therefore, the frequency of underestimation and overestimation of the measured distances is more important for assessing the risk of nerve damage than the absolute differences between different head orientation and standard position. Overestimation of the values is more damaging than underestimation because it might lead to injury to IAN. The tilt position was found to be more responsible for overestimating the real distances than other head orientations.

The accuracy of measurements carried out on CBCT images have been confirmed previously by comparing the craniofacial measurements at standard scanning position with physical ones. [8-11, 26] Therefore, in the present study, the standard patient positioning measurements were considered as the reference with which other patient positioning could be compared.

The present study suffers from certain limitations. Different factors, such as scanning protocol and the CBCT unit, may influence the results. Therefore, considering that only one CBCT unit (NewTom VGi) was used in this study, the results of the present study cannot extrapolate to other CBCT machines. The extent of patient positioning error and the rotation angle during CBCT scanning may also affect the results of this study. Therefore, further studies evaluating the influence of different angular rotations are recommended.

Conclusion

In conclusion, it seems that the use of head positioning devices during CBCT scanning or correction software tools to overcome patient positioning error should not be mandatory. Furthermore, standardization of patient positioning in the CBCT scanner during follow-up period to compare CBCT scans with previous scans is not essential.

Acknowledgement

The authors thank the Vice-Chancellery of Research Sh-

iraz University of Medical Science for supporting this research (Grant #7280). This article is based on the thesis by Dr. Nikanjam. The authors also thank Dr. Vosoughi of the Dental Research Development Center, of the School of Dentistry for the statistical analysis and also Center for Development of Clinical Research of Nemazee Hospital and Dr. Nasrin Shokrpour for editorial assistance.

Conflict of Interest

Authors have no conflicts of interest to declare.

References

- [1] Iacopetti I, Faughnan M, Bono S, Cozzi B, Facchini C. The Inferior Alveolar Nerve of the Horse: Course and Anatomical Relationship with Mandibular Cheek Teeth. *Anat Histol Embryol.* 2015; 44: 333-337.
- [2] Wang WQ, Chen MY, Huang HL, Fuh LJ, Tsai MT, Hsu JT. New quantitative classification of the anatomical relationship between impacted third molars and the inferior alveolar nerve. *BMC Med Imaging.* 2015; 15: 59.
- [3] Ghaemina H, Meijer GJ, Soehardi A, Borstlap WA, Mulder J, Vlijmen OJ, et al. The use of cone beam CT for the removal of wisdom teeth changes the surgical approach compared with panoramic radiography: a pilot study. *Int J Oral Maxillofac Surg.* 2011; 40: 834-839.
- [4] Shahidi S, Vojdani M, Paknahad M. Correlation between articular eminence steepness measured with cone-beam computed tomography and clinical dysfunction index in patients with temporomandibular joint dysfunction. *Oral Surg Oral Med Oral Pathol Oral Radiol.* 2013; 116: 91-97.
- [5] Paknahad M, Shahidi S. Association between mandibular condylar position and clinical dysfunction index. *J Craniomaxillofac Surg.* 2015; 43: 432-436.
- [6] Paknahad M, Shahidi S, Abbaszade H. Correlation between condylar position and different sagittal skeletal facial types. *J Orofac Orthop.* 2016; 77: 350-356.
- [7] Paknahad M, Shahidi S, Akhlaghian M, Abolvardi M. Is Mandibular Fossa Morphology and Articular Eminence Inclination Associated with Temporomandibular Dysfunction? *J Dent (Shiraz).* 2016; 17: 134-141.
- [8] Kamburoğlu K, Kiliç C, Ozen T, Yüksel SP. Measurements of mandibular canal region obtained by cone-beam computed tomography: a cadaveric study. *Oral Surg Oral Med Oral Pathol Oral Radiol Endod.* 2009; 107: e34-e42.
- [9] Kim TS, Caruso JM, Christensen H, Torabinejad M. A

- comparison of cone-beam computed tomography and direct measurement in the examination of the mandibular canal and adjacent structures. *J Endod.* 2010; 36: 1191-1194.
- [10] Cavalcanti MG, Rocha SS, Vannier MW. Craniofacial measurements based on 3D-CT volume rendering: implications for clinical applications. *Dentomaxillofac Radiol.* 2004; 33: 170-176.
- [11] Stratemann SA, Huang JC, Maki K, Miller AJ, Hatcher DC. Comparison of cone beam computed tomography imaging with physical measures. *Dentomaxillofac Radiol.* 2008; 37: 80-93.
- [12] Frongia G, Piacino MG, Bracco P. Cone-beam computed tomography: accuracy of three-dimensional cephalometry analysis and influence of patient scanning position. *J Craniofac Surg.* 2012; 23: 1038-1043.
- [13] Sheikhi M, Ghorbanizadeh S, Abdinian M, Goroohi H, Badrian H. Accuracy of linear measurements of galileos cone beam computed tomography in normal and different head positions. *Int J Dent.* 2012; 2012: 214954.
- [14] Nikneshan S, Aval SH, Bakhshalian N, Shahab S, Mohammadpour M, Sarikhani S. Accuracy of linear measurement using cone-beam computed tomography at different reconstruction angles. *Imaging Sci Dent.* 2014; 44: 257-262.
- [15] Sabban H, Mahdian M, Dhingra A, Lurie AG, Tadinada A. Evaluation of linear measurements of implant sites based on head orientation during acquisition: An ex vivo study using cone-beam computed tomography. *Imaging Sci Dent.* 2015; 45: 73-80.
- [16] Visconti MA, Verner FS, Assis NM, Devito KL. Influence of maxillomandibular positioning in cone beam computed tomography for implant planning. *Int J Oral Maxillofac Surg.* 2013; 42: 880-886.
- [17] Kajan ZD, Asli HN, Taramsari M, Chai SMF, Hemmaty YB. Comparison of height and width measurements of mandibular bone in various head orientations using cone beam computed tomography: an experimental in vitro study. *Oral Radiology.* 2015; 31: 28-35.
- [18] Bou Serhal C, Jacobs R, Flygare L, Quirynen M, van Steenberghe D. Perioperative validation of localisation of the mental foramen. *Dentomaxillofac Radiol.* 2002; 31: 39-43.
- [19] Tomasi C1, Bressan E, Corazza B, Mazzoleni S, Stellini E, Lith A. Reliability and reproducibility of linear mandible measurements with the use of a cone-beam computed tomography and two object inclinations. *Dentomaxillofac Radiol.* 2011; 40: 244-250.
- [20] Hassan B, van der Stelt P, Sanderink G. Accuracy of three-dimensional measurements obtained from cone beam computed tomography surface-rendered images for cephalometric analysis: influence of patient scanning position. *Eur J Orthod.* 2009; 31: 129-134.
- [21] El-Beialy AR, Fayed MS, El-Bialy AM, Mostafa YA. Accuracy and reliability of cone-beam computed tomography measurements: Influence of head orientation. *Am J Orthod Dentofacial Orthop.* 2011; 140: 157-165.
- [22] Berco M, Rigali PH Jr, Miner RM, DeLuca S, Anderson NK, Will LA. Accuracy and reliability of linear cephalometric measurements from cone-beam computed tomography scans of a dry human skull. *Am J Orthod Dentofacial Orthop.* 2009; 136: 17.e1-9.
- [23] Ludlow JB, Laster WS, See M, Bailey LJ, Hershey HG. Accuracy of measurements of mandibular anatomy in cone beam computed tomography images. *Oral Surg Oral Med Oral Pathol Oral Radiol Endod.* 2007; 103: 534-542.
- [24] Cevidanes L, Oliveira AE, Motta A, Phillips C, Burke B, Tyndall D. Head orientation in CBCT-generated cephalograms. *Angle Orthod.* 2009; 79: 971-977.
- [25] Shahidi Sh, Feiz A. Effect of Minor Amendments of Patient's Position on the Accuracy of Linear Measurements Yielded from Cone Beam Computed Tomography. *J Dent (Shiraz).* 2013; 14: 1-5.
- [26] Ganguly R, Ruprecht A, Vincent S, Hellstein J, Timmons S, Qian F. Accuracy of linear measurement in the Galileos cone beam computed tomography under simulated clinical conditions. *Dentomaxillofac Radiol.* 2011; 40: 299-305.