

Case Report**Peripheral Ameloblastic Fibroma: Report of a Rare Case**Mahsa Kalantari ¹, Sahand Samieirad ², Parisa Kalantari ³¹ Dept. of Oral and Maxillofacial Pathology, School of Dentistry, Kerman Oral and Dental Diseases Research Center, Kerman University of Medical Sciences, Kerman, Iran.² Dept. of Oral and Maxillofacial Surgery, Mashhad University of Medical Sciences, Mashhad Dental School, Mashhad, Iran.³ Postgraduate Student, Dept. of Orthodontics, School of Dentistry, Kerman Oral and Dental Diseases Research Center, Kerman University of Medical Sciences, Kerman, Iran.**KEY WORDS**

Ameloblastic fibroma;

Gingiva;

Peripheral;

*Received: June 2015;**Received in revised form: August 2015;**Accepted: October 2015;***ABSTRACT**

Ameloblastic fibroma is a rare mixed odontogenic tumor mostly occurring in the posterior region of the mandible. The peripheral variant is very rare and to the best of our knowledge, only three cases have been reported in the English literature. In this report, we describe a case of peripheral ameloblastic fibroma in a 54-year-old woman with two years of follow-up.

Corresponding Author: Kalantari M., Dept. of Oral and Maxillofacial Pathology, School of Dentistry, Kerman Oral and Dental Diseases Research Center, Kerman, Iran. Tel: + 98-3432118071
Email: kalantary.mahsa@yahoo.com

Cite this article as: Kalantari M., Samieirad S., Kalantari P. Peripheral Ameloblastic Fibroma: Report of a Rare Case. *J Dent Shiraz Univ Med Sci.*, 2016 December; 17(4): 367-369.

Introduction

Ameloblastic fibroma is a rare odontogenic tumor in which both odontogenic epithelial and ectomesenchymal components are neoplastic. [1] Most cases tend to occur in the first two decades of life with mean age of 15 years. [2] There is a slight male predominance and the posterior region of the mandible is the most commonly involved area. [3] The peripheral (extraosseous) form is an exceedingly rare lesion. [4] In a review of the literature in relation to the peripheral odontogenic tumors carried out by Buchner and Sciubba in 1987, no peripheral ameloblastic fibroma was reported. [5] To the best of our knowledge, only five cases of peripheral ameloblastic fibromas have been reported; two of which are in the Japanese literature. [6-10] In this study, we report a case of peripheral ameloblastic fibroma occurring in a 54-year-old woman.

Case Report

A 54-year-old woman complaining of a swelling of the mandibular anterior lingual gingiva was referred to the Department of Oral and Maxillofacial Surgery, Kerman Dental School, Iran. The patient reported that the lesion had been present for 2 years with a progressive increase in size. The medical history was unremarkable and the results of hematologic tests were

within normal limits. On oral examination, a sessile lesion was found on the lingual gingiva of mandibular incisors. The lesion was approximately 6×8mm in diameter, pink in color, and firm. Radiographic examination showed no involvement of the underlying bone. Based on the clinical findings, the diagnosis was peripheral ossifying fibroma.

Excisional biopsy was performed under local anesthesia and the specimen was sent to the Oral and Maxillofacial Pathology Department for definitive diagnosis. The microscopic examination revealed a mixed benign odontogenic neoplasm composed of nests and islands of odontogenic epithelium with outer columnar cell layer and central stellate reticulum-like areas interspersed within a very cellular ectomesenchymal connective tissue. No inductive changes were present (Figures 1). Based on these findings, a diagnosis of peripheral ameloblastic fibroma was reached. No recurrence has occurred two years after surgery.

Discussion

Odontogenic tumors constitute 7% of the cases of oral lesions and among them; ameloblastic fibroma is relatively rare and represents 1.4-5.4% of all of these lesions. [5, 11-12] It is a mixed tumor consisting of proliferating odontogenic epithelium in an ectomesenchy

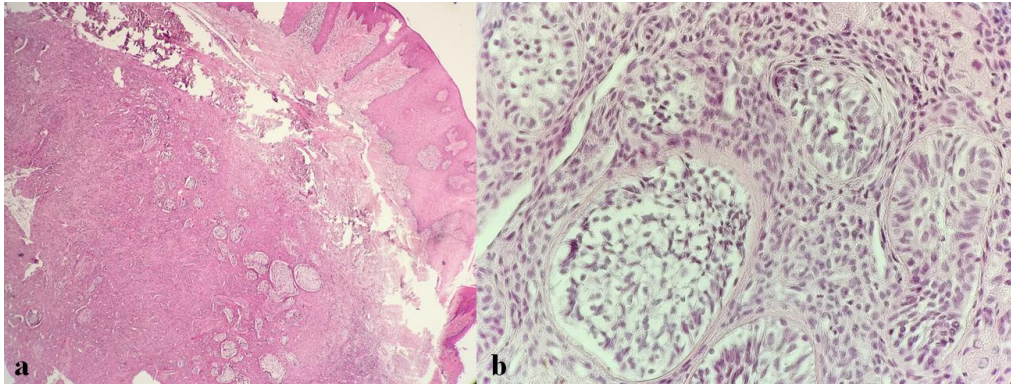


Figure 1a: Photomicrograph showing nests and islands of proliferating odontogenic epithelium within a cell-rich ectomesenchymal connective tissue (H & E stain. 100x), **b:** Higher magnification showing islands of odontogenic epithelium with outer columnar cell layer and central stellate reticulum-like areas interspersed within a cellular connective tissue (H & E stain. 400x).

mal connective tissue that resembles the dental papilla. [13] In more than 80% of cases, the mandible is affected with a prevalence rate of 88% in the posterior region. [7] This tumor has been reported more frequently in males, with a mean age of 15 years (0.5-62 years). [11, 13] It is mainly intraosseous and only few peripheral cases have been reported. The peripheral variant was not described in the odontogenic tumor literature until 1991. [14] Kusama *et al.* reported a case of peripheral ameloblastic fibroma in the mandibular posterior gingiva in a 40-year-old woman in 1998. [8] Darling *et al.* presented another case in 2008 in the maxillary gingiva of a 5-year-old girl. [6] Abughazale *et al.* discussed a case of peripheral ameloblastic fibroma in a 3-year-old girl in the maxillary gingiva of the primary lateral incisor. [7] Two cases of peripheral ameloblastic fibroma have been reported in the Japanese literature. Nakamura *et al.* and Harada *et al.* presented two cases in a 2-year-old boy and a 1-year-old girl, respectively. [9-10]

The case presented here was a 54-year-old woman with the lesion in the mandibular anterior gingiva. Although the mean age of central ameloblastic fibroma is 15 years, her age is in the age range of ameloblastic fibroma (0.5-62 years). [11, 13]

To reach a diagnosis of peripheral ameloblastic fibroma, it must be distinguished from the peripheral odontogenic fibroma. The latter has been reported more frequently in men with a wide age range of recurrence. Histologically, peripheral odontogenic fibroma is composed of a myxoid, fibroblastic or hyalinized stroma with varying amounts of odontogenic epithelium. The epithelial component may be absent,

scanty or inactive. Foci of calcification, dentinoid, cementicle or bone formation may be present. The peripheral ameloblastic fibroma has a prominent epithelial component consisting of cords and islands of odontogenic epithelium with central stellate reticulum-like areas that resemble early enamel organ development. Areas of hyalinization may be present in its cellular mesenchymal connective tissue. [6, 8]

Conservative excision is the treatment of choice for central ameloblastic fibroma. The present patient was treated by surgical excision and after 16 months; there was no evidence of recurrence. Other reported peripheral ameloblastic fibromas had no recurrence after follow-up time which was reported to be 10 months to 4 years. [6- 8]

In conclusion, it is important to make a distinction between peripheral ameloblastic fibroma and other peripheral odontogenic tumors in the differential diagnosis. It seems that no recurrence occurs after conservative surgical treatment of the peripheral variant of ameloblastic fibroma.

Conflict of Interest

The authors of this manuscript certify no financial or other competing interest regarding this article.

References

- [1] Munde AD, Karle RR, Kale UB. Ameloblastic fibroma in one-year-old girl. J Oral Maxillofac Pathol. 2013; 17: 149.
- [2] Chen Y, Wang JM, Li TJ. Ameloblastic fibroma: a review of published studies with special reference to its nature and biological behavior. Oral Oncol. 2007; 43:

- 960-969.
- [3] McGuinness NJ, Faughnan T, Bennani F, Connolly CE. Ameloblastic fibroma of the anterior maxilla presenting as a complication of tooth eruption: a case report. *J Orthod.* 2001; 28: 115-118.
- [4] Buchner A, Sciubba JJ. Peripheral epithelial odontogenic tumors: a review. *Oral Surg Oral Med Oral Pathol.* 1987; 63: 688-697.
- [5] Guerrisi M, Piloni MJ, Keszler A. Odontogenic tumors in children and adolescents. A 15-year retrospective study in Argentina. *Med Oral Patol Oral Cir Bucal.* 2007; 12: E180-E185.
- [6] Darling MR, Daley TD. Peripheral ameloblastic fibroma. *J Oral Pathol Med.* 2006; 35: 190-192.
- [7] Abughazaleh K, Andrus KM, Katsnelson A, White DK. Peripheral ameloblastic fibroma of the maxilla: report of a case and review of the literature. *Oral Surg Oral Med Oral Pathol Oral Radiol Endod.* 2008; 105: e46-e48.
- [8] Kusama K, Miyake M, Moro I. Peripheral ameloblastic fibroma of the mandible: report of a case. *J Oral Maxillofac Surg.* 1998; 56: 399-401.
- [9] Nakamura M, Tamai K. A case of amelo-blastic fibroma in an infant (2-year-old). *J Japan Stomatol Societ* 1980; 29: 99-103.
- [10] Harada H, Kusukawa J, Oh-uchida M, Tanaka S, Okina T, Kameyama T. Ameloblastic fibroma in an infant - A case report. *J Jpn Soc Oral Tumors.* 1992; 4: 286-293.
- [11] Curran AE. Peripheral odontogenic tumors. *Oral Maxillofac Surg Clin North Am.* 2004; 16: 399-408.
- [12] Gupta DRS, Tandon A, Mehrotra D, Gupta OP. Ameloblastic fibroma: report of 3 cases and literature review. *Int J Oral Maxillofac Pathol.* 2011; 2: 59-63.
- [13] Cohen DM, Bhattacharyya I. Ame-loblastic fibroma, ameloblastic fibro-odontoma, and odontoma. *Oral Maxillofac Surg Clin North Am.* 2004; 16: 375-384.
- [14] Takeda Y. Amelo-blastic fibroma and related lesions: current pathologic concept. *Oral Oncol.* 1999; 35: 535-540.