

## Case Report

## Resolution of a Cutaneous Lesion Associated with a Periapical Actinomycosis Following Endodontic Surgery: A Case Report

Farhad AR.<sup>a</sup>, Ajami M.<sup>b</sup>, Rastegar Khosravi M.<sup>b</sup>

<sup>a</sup> Dept. of Endodontics and Torabinejad Dental Research Center, School of Dentistry, Isfahan University of Medical Sciences, Isfahan, IRAN

<sup>b</sup> Endodontist

### KEY WORDS

Actinomycosis;  
Cutaneous lesion;  
Periapical surgery

Received Sept. 2011;  
Received in revised form Nov.2011;  
Accepted Jan.2012

### ABSTRACT

Actinomycosis is a granulomatous infection of the cervicofacial, thoracic, abdominal and cerebral regions. Cervicofacial actinomycosis usually presents as a palpable mass, which is sometimes painful and may be associated with a draining sinus tract. Periapical actinomycosis is a cervicofacial form of actinomycosis. Periapical actinomycosis is a persisting periapical lesion that usually do not respond to routine endodontic treatment and persists for a long period of time. In this case report, the healing of a cutaneous and periapical lesion associated with acti-nomycosis following routine root canal treatment and periapical surgery is presented.

\* **Corresponding author.** Farhad AR., Address: Department of Endodontics, School of dentistry, Isfahan University of medical Sciences, Isfahan, Iran; Tel: 0311-7922846 Fax: 0311-6687080 Email: farhad@dnt.mui.ac.ir

### Introduction

Egress of microorganisms and their by-products from the infected root canal are considered the major cause of periapical pathosis [1]. In certain cases, despite adequate endodontic treatment, periapical lesion may persist and about 10 percent of well treated cases end in failure [2]. Persisting extraradicular infection of the periapical tissue is one of the factors that results in failure of endodontic therapy [3]. An extraradicular infection occurs when the microorganism establishes colonies on the external root surface within the periapical region [4].

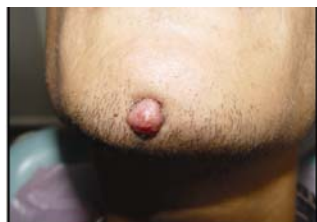Actinomycosis is a chronic infectious disease caused by anaerobic gram-positive, pleomorphic, non-spore forming rods from the actinomyces family. This bacterium provokes a chronic productive and colliquative inflammatory reaction which produces granulomatous and suppurative lesions by bacterial proliferation [5]. A hallmark of this disease is the tendency to spread without regard for anatomical barriers, including facial planes and lymphatic channels [6]. Sinus tracts are a frequent occurrence. Repeated temporary improvement or resolution of the sinus tract with antibiotic therapy, followed by relapse,

is indicative of actinomycosis [7]. Actinomyces destroys the local tissue and replaces it with granulomatous inflammatory tissue often associated with a sinus tract. Granules are formed by masses of branching microorganism extending in radiation (Sunburst-Fashion) [8].

Human actinomycosis occurs in four different clinical forms: cervicofacial, abdominal, thoracic, and cerebral. The cervicofacial site is the most common of the four types and it is found in about 60% of the cases. Periapical actinomycosis is a cervicofacial form of actinomycosis [9-10]. Actinomyces israelii is the most commonly isolated species in actinomycosis, which is followed by Propionibacterium propionicum, Actinomyces naeslundii, Actinomyces viscosus and Actinomyces odontolyticus [11]. Periapical actinomycosis is believed to be a persisting periapical lesion and has been suggested as a predisposing factor in the perpetuation of periapical lesions after root canal treatment [12]. The following case report describes the resolution of a periapical actinomycosis with a cutaneous lesion after routine endodontic treatment and periapical surgery.

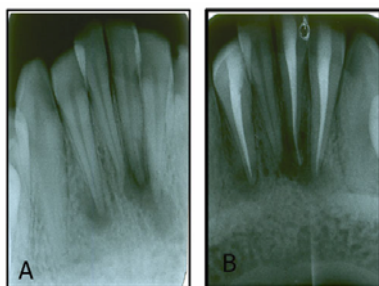
### Case Report

A 22 year old male was referred with a chief complaint of a cutaneous lesion in the midline of his chin (Figure 1). The lesion had been persisting for three years and when palpated, a purulent discharge was expressed from the cutaneous nodule. The patient had a non-contributory medical history.



**Figure 1** Cutaneous lesion on midline of chin before endodontic treatment

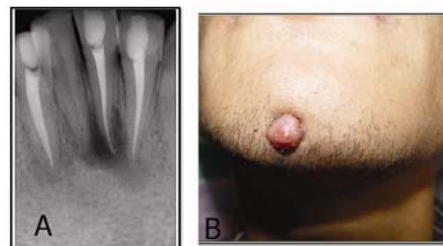
Radiographic examination revealed ill-defined periradicular radiolucencies associated with teeth # 31, 32 and 42. The teeth were slightly sensitive to percussion and had normal periodontal probing and mobility. The alveolar mucosa adjacent to the teeth was not tender to palpation. Crowns of the teeth were intact and the patient could not remember previous history of trauma or other possible causes for his dental problem. Pulp vitality testing of the teeth with electric and thermal pulp testing revealed no pulpal response in the teeth # 31, 32 and 42, which indicated a necrotic pulp. A diagnosis of necrotic pulp with chronic suppurative periradicular periodontitis for teeth # 31, 32, and 42 was established. The patient was informed of treatment plan, possible discomfort, and potential risks. A consent form was collected before each phase of treatment. Root canal therapy was completed and the endodontic access properly restored (Figure 2).



**Figure 2a** Preoperative radiograph before endodontic treatment. **b** Postoperative radiograph after endodontic treatment.

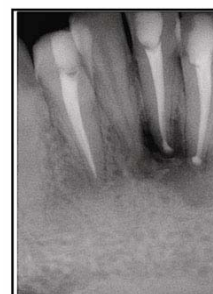When the patient returned for the 6 month follow

up examination, a periapical radiograph showed that the periapical lesion associated with tooth #42 was healed, but radiolucencies associated with teeth # 31 and 32 and the cutaneous lesion had persisted (Figure 3).



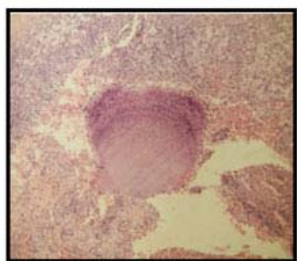
**Figure 3A** Six month follow-up radiograph after endodontic treatment. **B** Cutaneous lesion persists six month after endodontic treatment.

At the next appointment, a surgical endodontic treatment was performed. After local anesthesia with Citocaina (Cristalia, Itapira, Brazil), a rectangular full-thickness muco-periosteal flap with vertical releasing incisions was reflected from teeth # 42 to 33, revealing a bony lesion at the apex of teeth # 31 and 32. The granulation tissue from the bony defect was carefully removed by 4R/4L curette (Hufriedy, Chicago, IL, USA) and sent for histological evaluation. Yellowish gray appearing granules were noticed in the granulomatous tissue. Apicoectomy of teeth # 31 and 32 was performed and retropreparations were made using a ultrasonic tip (E3ID, NSK, Japan). A retrofilling of Pro Root MTA (Dentsply, Tulsa dental, OK, USA) was placed. The flap was reapproximated and sutured with 3-0 silk sutures (Ethicon, PA, USA). A postsurgical radiograph was taken (Figure 4). After the surgery, the patient was prescribed amoxicillin 500mg three times a day for one week and 0.2% chlorhexidine mouth wash 15mL twice a day for two weeks. The sutures were removed one week later and the patient reported only mild discomfort after the surgical intervention.



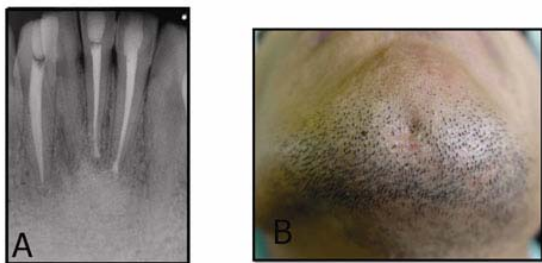
**Figure 4** Postoperative radiograph after periapical surgery

Histological examination of the biopsy consisted of granular tissue with diffuse inflammatory infiltrate of plasma cells, fibroblasts and giant cells. It also showed an infiltrate of polymorphonucleates. Microscopic examination also indicated basophilic fine branching filamentous bacterial aggregate that is suggestive of actinomyces (Figure 5). A diagnosis of periapical actinomycosis was established.



**Figure 5** Actinomycotic colony surrounded by granulomatous tissue

Radiographical and clinical examination 1 year after surgery showed complete regeneration of the bone in the periapical region of teeth # 31 and 32; the cutaneous lesion was completely healed and there was no sign of re-occurrence (Figure 6).



**Figure 6A** One year follow-up radiograph after periapical surgery. **B** Complete healing of cutaneous lesion one year after periapical surgery

### Discussion

Actinomyces are a normal part of the gastrointestinal flora and generally have a low potential to produce disease in their usual environment because of their inability to penetrate mucosa. But when normal mucosal barrier is disrupted, this microorganism is capable of establishing a chronic and saprophytic infection. Actinomyces lack hyaluronidase enzyme, and in order to achieve pathogenictiy the aid of other bacteria is required [13]. The majority of cases of actinomycosis are seen in patients with poor oral

hygiene, dental or periodontal problems, trauma and following oral surgical procedures.

The data on the frequency of periapical actinomycosis among apical periodontitis lesions are scarce. A few studies have reported the incidence of periapical actinomycosis to be about 2-4% [12, 14-15].

Actinomyces have been shown to inhibit normal periradicular healing following conventional root canal therapy due to their capacity to survive in the periapical tissues beyond the root canal system [14]. These bacteria are associated with the ability to form cohesive aggregates of branching filaments via fimbria- like structures, enabling them to collectively escape destruction by host defense system [16].

The definitive diagnosis of this case was established through the microscopic examination of the submitted periapical tissue sample rather than through clinical diagnosis. This shows the importance of submitting all surgical tissue samples for histologic and microscopic evaluation. The findings from these examinations may provide additional information which can, in some circumstances, be used to follow a more accurate course of treatment for the patient.

Medicaments such as sodium hypochlorite and calcium hydroxide are highly effective in killing (or damaging) actinomyces Israeli, but the lack of direct contact of these microorganisms established in periapical tissue with sodium hypochlorite and calcium hydroxide, and/or inactivation of these medicaments by the dentin, tissue fluids and organic matter could explain the lack of response of such cases to conventional treatment [17-18].

Classic treatment for actinomycosis involves the excision of the lesion and prescription of prolonged antibiotics. Some investigators have routinely recommended that the use of high concentrations of antibiotics like penicillin is necessary to first penetrate the areas of dense fibrosis and then to kill the microorganisms [19-21]. In this case, antibiotics were not administered in long term because recent studies have shown that in the treatment of localized cervicofacial (periapical) actinomycosis, the use of antibiotics may not be necessary [22-23].

### Conclusion

If a sinus tract associated with a root infection does not

heal after appropriate root canal treatment, one of the reasons might be actinomycosis. In such cases, surgical intervention subsequent to a proper orthograde endodontic treatment approach may be necessary for periradicular healing to occur.

## References

- [1] Torabinejad M. Mediators of acute and chronic periradicular lesions. *Oral Surg Oral Med Oral Pathol* 1994; 78: 511-521.
- [2] Sjogren U, Hagglund B, Sundqvist G, Wing K. Factors affecting the long-term results of endodontic treatment. *J Endod* 1990; 16: 498-504.
- [3] Nair PN. On the causes of persistent apical periodontitis: a review. *Int Endod J* 2006; 39: 249-281.
- [4] Abbott PV. Classification, Diagnosis and Clinical Manifestations of Apical Periodontitis. *Endod Topics* 2004; 8: 36-54.
- [5] Tortorici S, Burruano F, Buzzanca ML, Difalco P, Daniela C, Emiliano M Cervico-Facial Actinomycosis: Epidemiological and Clinical Comments. *J Am Infect Dis* 2008; 4: 204-208.
- [6] Oostman O, Smego RA. Cervicofacial Actinomycosis: Diagnosis and Management. *Curr Infect Dis Rep* 2005; 7: 170-174.
- [7] Jeansonne BG. Periapical actinomycosis: a review. *Quintessence Int* 2005; 36: 149-153.
- [8] Xia T, Baumgartner JC. Occurrence of Actinomyces in infections of endodontic origin. *J Endod* 2003; 29: 549-552.
- [9] Siqueira JF Jr. Periapical actinomycosis and infection with. *Propionibacterium propionicum*. *Endod Top* 2003; 6: 78-95.
- [10] Sakellariou PL. Periapical actinomycosis: report of a case and review of the literature. *Endod Dent Traumatol* 1996; 12: 151-154.
- [11] Miller M, Haddad AJ. Cervicofacial actinomycosis. *Oral Surg Oral Med Oral Pathol Oral Radiol Endod* 1998; 85: 496-508.
- [12] Hirshberg A, Tsesis I, Metzger Z, Kaplan I. Periapical actinomycosis: a clinicopathologic study. *Oral Surg Oral Med Oral Pathol Oral Radiol Endod* 2003; 95: 614-620.
- [13] Oppenheimer S, Miller GS, Knopf K, Blechman H. Periapical actinomycosis. An unusual case report. *Oral Surg Oral Med Oral Pathol* 1978; 46: 101-116.
- [14] Bystrom A, Happonen RP, Sjogren U, Sundqvist G. Healing of periapical lesions of pulpless teeth after endodontic treatment with controlled asepsis. *Endod Dent Traumatol* 1987; 3: 58-63.
- [15] Martin IC, Harrison JD. Periapical actinomycosis. *Br Dent J* 1984; 156: 169-170.
- [16] Figdor D, Davies J. Cell surface structures of Actinomyces Israeli. *Aust Dent J* 1997; 42: 125-128.
- [17] Barnard D, Davies J, Figdor D. Susceptibility of Actinomyces Israeli to antibiotics, sodium hypochlorite and calcium hydroxide. *Int Endod J* 1996; 29: 320-326.
- [18] Haapasalo M, Qian W, Portenier I, Waltimo T. Effects of dentin on the antimicrobial properties of endodontic medicaments. *J Endod* 2007; 33: 917-925.
- [19] Nichlos DR, Herrell WE. Penicillin in the treatment of actinomycosis. *J Lab Clin Med* 1948; 33: 521-525.
- [20] Smego RA Jr, Foglia G. Actinomycosis. *Clin Infect Dis* 1998; 26: 1255-1261.
- [21] Peabody JW Jr, Seabury JH. Actinomycosis and nocardiosis. A review of basic differences in therapy. *Am J Med* 1960; 28: 99-115.
- [22] Rush JR, Sulte HR, Cohen DM, Makkawy H. Course of infection and case outcome in individuals diagnosed with microbial colonies morphologically consistent with Actinomyces species. *J Endod* 2002; 28: 613-618.
- [23] Ricucci D, Siqueira JF Jr. Apical actinomycosis as a continuum of intraradicular and extraradicular infection: case report and critical review on its involvement with treatment failure. *J Endod* 2008; 34: 1124-1129.