

Case Report

Mandibular Mural Ameloblastoma with Unusual Histopathologic Features: a Rare Challenging Case

Soudabeh Sargolzaei, DMD, MScD¹; Saede Atarbashi-Moghadam, DMD, MScD¹; Aliasghar Roohi, DMD, MScD²

¹ Dept. of Oral and Maxillofacial Pathology, Dental School, Shahid Beheshti University of Medical Sciences, Tehran, Iran.

² Oral and Maxillofacial Surgen, Tehran, Iran.

KEY WORDS

Ameloblastoma;
Oral Neoplasm;
Odontogenic tumor;
Mandible;

Received: February 2018;

Revised: July 2018;

Accepted: August 2018;

ABSTRACT

Ameloblastomas demonstrate various clinical and microscopic patterns. They typically have been described as possessing three biologic variants including solid, cystic (unicystic) and peripheral, of which about 13% to 21% of all cases are unicystic. Granular cell subtype is a rare variant especially when both the inner and peripheral layers of tumoral islands composed exclusively of eosinophilic granular cells. The purpose of this case report is to present a unique case of cystic ameloblastoma with an unusual radiographic and microscopic pattern affecting a 25-year-old female. Awareness of these rare histopathologic features for oral pathologist is essential to help correct diagnosis.

Corresponding Author: Atarbashi-Moghadam S, Dept. of Oral and Maxillofacial Pathology, Dental School, Shahid Beheshti University of Medical Sciences, Velenjak Street, Tehran, Iran. Tel: +98-2122403075
Fax: +98-2122403194 Email: dr.atarbashi@gmail.com

Cite this article as: Sargolzaei S, Atarbashi-Moghadam S, Roohi AA. Mandibular Mural Ameloblastoma with Unusual Histopathologic Features: a Rare Challenging Case. *J Dent Shiraz Univ Med Sci.* December 2019; 20(4): 304-307.

Introduction

Ameloblastoma is a benign, locally aggressive epithelial odontogenic neoplasm, which reveals several different microscopic variants [1-3].

It is divided into three groups of solid, cystic (unicystic), and peripheral. Unicystic ameloblastomas are seen more often in younger patients during the second decades of life. The posterior mandible is the most common location [4-5]. The lesion is often asymptomatic, although large lesions may cause a painless swelling of the jaws [5]. Unicystic ameloblastoma is classified into three microscopic groups including luminal, intraluminal (plexiform), and mural. In luminal variant, the tumor is confined to the luminal surface of the cyst. In the intraluminal variant, one or more nodules of ameloblastoma project from the cystic lining into the lumen of the cyst. In mural type, the fibrous wall of the cyst is infiltrated by typical follicular or plexiform ameloblastoma [4-6]. Although luminal and intraluminal ameloblastoma may be treated by enucleation, radical surgery is the treatment of choice for mural ameloblastoma [4]. Granular cell subtype is rare variant [1-3]. To the best of our knowledge, granular cytoplasmic changes are seen in the stellate reticulum regions of the ameloblastoma-

tous follicles and interlacing cords and nests. Rarely granular changes can also be detected in peripheral ameloblastic cells [1, 6]. Failure to recognize ameloblastoma patterns is caused confusion for pathologist; therefore, the aim of this study was to present a rare challenging case of granular cell mural ameloblastoma in the posterior mandible of 25-year-old female.

Case Report

A 25-year-old female was referred to the Oral and Maxillofacial Pathology Department of Shahid Beheshti University of Medical Sciences (Tehran, Iran) for evaluation of the painless expansion on the right side of the face. Intraoral examination revealed a swelling in the posterior area of right mandible. There was no cervical lymphadenopathy and the laboratory data was unremarkable. The panoramic radiograph revealed a well-defined corticated multilocular radiolucent lesion with coarse and curved internal septa in the right side of the mandible from first premolar to ramus with root resorption of 45, 46 measuring 5cm×2cm (Figure 1). Given the radiographic feature, the diagnosis of ameloblastoma was considered. To make a final diagnosis, incisional biopsy was performed under local anesthesia.

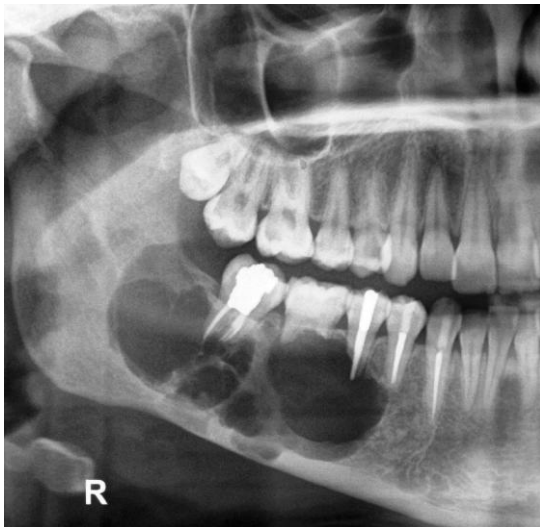


Figure 1: The panoramic radiograph revealed a well-defined corticated multilocular radiolucent lesion with coarse and curved internal septa and root resorption of #45, #46

The specimen demonstrated a cystic white and homogenous cut surface. It was processed for routine hematoxylin and eosin (H&E) histopathologic study. Microscopic examination showed a cystic lesion lined by granular cell epithelium. The fibrous wall of the cyst is infiltrated by multiple islands, nests, cords, and sheets of neoplastic epithelial cells with abundant, finely granular, eosinophilic cytoplasm and hyperchromatic nuclei embedded in a densely collagenized stroma. Cystic changes in solid nests were also evident. Mitotic activity or cellular atypia was not found (Figure 2-5). At first glance, these microscopic features reminiscent of oncocytic neoplasm such as intraosseous oncocytic mucoepidermoid carcinoma. However, some peripheral cells of the oncocytic nests revealed reverse polarity and there was a subtle stellate reticulum in some islands. Serial sections showed the presence of conventional follicular ameloblastoma. Immunohistochemical staining for P63 and Ki-67 was performed. All the peripheral and central cells of the neoplastic islands were positive with P63 (Figure 6). The Ki-67 cell proliferation index was found to be about 1-2% (Figure 7). Due to these microscopic features, diagnosis of granular cell mural ameloblastoma was performed. The patient referred for enblock resection. Clinical follow-up was done after radical surgery and the patient was free of tumor for 1 year post-operatively.

Discussion

Radiologically, unicystic ameloblastoma is illustrated as

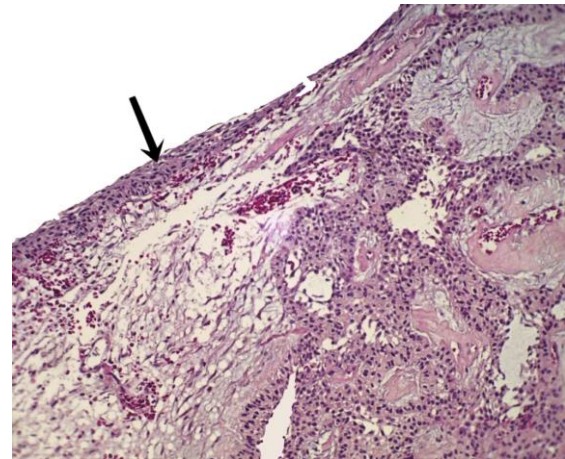


Figure 2: Microscopic sections show a cystic lesion lined by granular cell epithelium (black arrow). The underlying connective tissue demonstrates nests and islands of neoplastic granular cells (hematoxylin-eosin stain, original magnification: 100x)

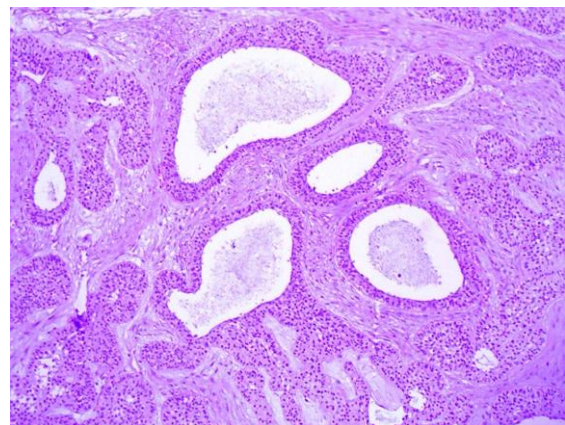


Figure 3: Microscopic sections show nests, islands, and cords of granular neoplastic cells with cystic formations (hematoxylin-eosin stain, original magnification: 100x)

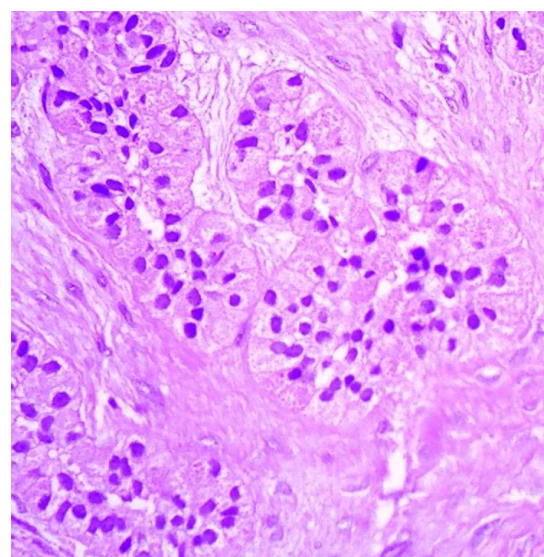


Figure 4: Nests with granular cells (hematoxylin-eosin stain, original magnification: 400x).

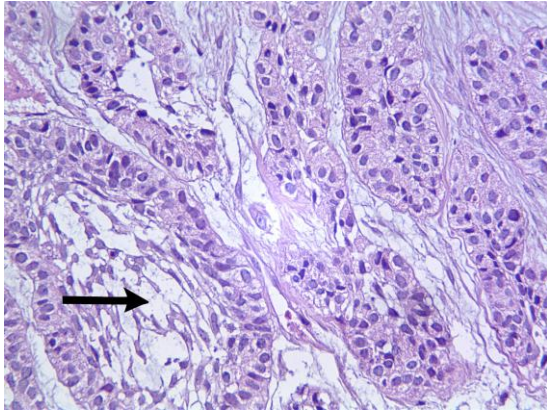


Figure 5: The epithelial nest consists of a core of loosely arranged angular cells resembling the stellate reticulum of an enamel organ (black arrow) (hematoxylin-eosin stain, original magnification: 400×)

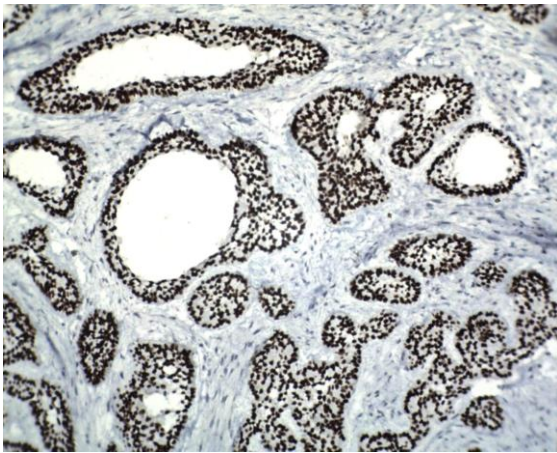


Figure 6: High expression of P63 in almost all granular cells (IHC stain, original magnification: 100×).

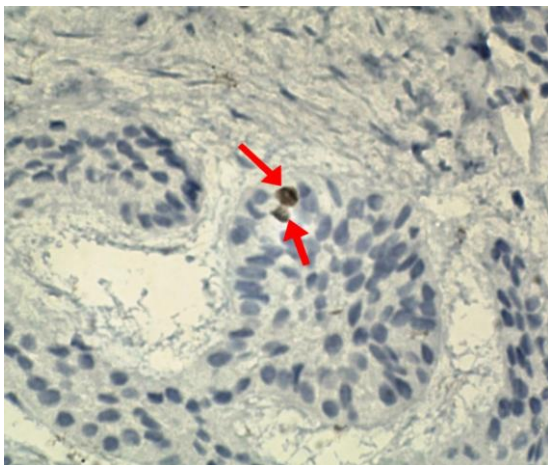


Figure 7: Low expression of ki-67 in granular cells (IHC stain, original magnification: 400×)

a unilocular radiolucency. Unicystic ameloblastoma may also demonstrate a multilocular pattern, particularly when it is not associated with an unerupted tooth. Therefore, the term “cystic” ameloblastoma is preferred

to the unicystic [3]. Granular cell changes in ameloblastoma, especially in cystic variant are infrequent. In cases where granular changes are only in the stellate reticulum part, the diagnosis is usually easy. However, in cases where peripheral cells have also changed, histopathologic diagnosis is very difficult and challenging [1]. The present case had some interesting points including multilocular radiographic pattern. Moreover, both the inner and peripheral layers of follicles were composed of eosinophilic granular cells, and granular cells were polyhedral and cylindrical in appearance. Furthermore, at least some of the peripheral cells of the granular cell nests revealed reverse polarity and many cystic spaces that reminiscent glandular neoplasms were present. The microscopic features of our case are very similar to the Argyris *et al.* [1] report, with the difference that our patient suffered from cystic ameloblastoma and showed some conventional follicular ameloblastic islands in serial sections.

The histopathologic differential diagnosis consists of granular cell odontogenic tumor (GCOF), oncocytic mucoepidermoid carcinoma (OMEC), oncocytic acinic cell carcinoma, and oncocytoma [1, 2, 6]. GCOF is composed of large eosinophilic granular cells intermixed with scattered cords or small islands of inactive odontogenic epithelium. Moreover, small cementum-like or dystrophic calcifications associated with the granular cells have been reported in some lesions [1, 5]. The nature of granular cells in oncocytic ameloblastoma is epithelial but in GCOF, the granular cells are shown mesenchymal origin [1].

The most common intraosseous salivary tumor is the central mucoepidermoid carcinoma. Nevertheless, other salivary gland neoplasms such as acinic cell carcinoma and adenocarcinoma have been reported [6]. OMEC is a rare variant of mucoepidermoid carcinoma composed predominantly of oncocytic cells, however, at least there are a small number of mucous cells in this tumor that help diagnosis. In addition, if there is a perineural or intravascular invasion, it will be useful in differentiating malignancy [7]. Some authors found that p63 expression might be a reliable marker in the diagnosis of OMEC [7] while p63 is also expressed in ameloblastoma [1, 8]. Therefore, it will not help in differentiating between these two neoplasms. In our case, all the central and peripheral cells of ameloblastic islands were

also positive for p63. Matsushita *et al.* [2] stated that immunoreaction with CK19, strongly suggested the odontogenic epithelium origin. Moreover, OMEC exhibits the t (11; 19) translocation and CRTC1-MAML2 fusion gene transcript that it can be useful in challenging case [7]. In the majority of the acinic cell carcinoma, at least some of the cells usually reveal acinar or serous differentiation (zymogen granules) on hematoxylin and eosin staining which are PAS-diastase positive [1]. It often is well circumscribed or may appear encapsulated [5] and is negative for P63 [9]. Oncocytoma of the jaw is an exceeding rare tumor and mandibular oncocytoma has not been reported so far. It tends to be arranged in rows or cords and sometimes in sheets [6]. Moreover, oncocytoma have a distinctive capsule and it is phosphotungstic acid haematoxylin [PTAH] positive [2, 6]. Cytoplasmic granules in oncocytoma are mitochondria [2]. The nature of the granules in granular cell ameloblastoma is lysosome and they are CD68 positive [1-2]. Oncocytoma is negative for CD68 that may be helpful in differential diagnosis. Cell proliferation rate in ameloblastoma variants especially granular cell and acanthomatous types is low and are located predominantly at the periphery of the ameloblastic nests [10]. Ki-67 expression in Argyris *et al.*'s study [1] was 0% and in our case was 1-2%. The low expression of this marker may also be helpful in rule out the malignancy. The biologic behavior and prognosis of granular cell ameloblastoma apparently varies from other microscopic patterns of ameloblastoma [1]. Furthermore, cystic granular cell ameloblastoma may reveal rapid destructive growth [4]. The treatment of choice is radical surgery and long-term follow up is recommended [4].

Conclusion

In rare instances, granular changes may be seen in both central and peripheral cells of islands of ameloblastoma. Moreover, many cystic spaces may be formed in ameloblastic nests. In problematic cases, serial sections and extensive sampling are recommended. In addition, immunohistochemistry might be useful in the diagnosis of complicated cases. As cystic ameloblastoma with such different microscopy are uncommon in the literature, their clinical behavior and prognosis are not clear; thus, reporting more such cases may be useful. Awareness of

these rare histopathologic features for oral pathologist is essential.

Conflict of Interest

The authors declare that there is no conflict of interests regarding the publication of this paper.

References

- [1] Argyris PP, McBeain MJ, Rake A, Pambuccian SE, Gopalakrishnan R, Koutlas IG. Recurrent ameloblastoma of the mandible with unusual granular cell component. *Int J Surg Pathol.* 2015; 23: 298-304.
- [2] Matsushita Y, Fujita S, Kawasaki G, Hirota Y, Rokutanda S, Yamashita K, et al. Granular cell ameloblastoma: case report of particular ameloblastoma histologically resembling oncocytoma. *Pathol Int.* 2015; 65: 43-47.
- [3] Thillaikarasi R, Balaji J, Gupta B, Ilayaraja V, Vani NV, Vidula B, et al. Cystic granular cell ameloblastoma. *J Maxillofac Oral Surg.* 2010; 9: 310-313.
- [4] Jain K, Sharma G, Kardam P, Mehendiratta M. Unicystic Ameloblastoma of Mandible with an Unusual Diverse Histopathology: A Rare Case Report. *J Clin Diagn Res.* 2017; 11: ZD04-ZD05.
- [5] Neville BW, Damm DD, Allen CM, Chi AC. *Oral and Maxillofacial Pathology. Odontogenic cysts and tumors.* 4rd ed. Philadelphia: Saunders; 2016. p. 654-660.
- [6] Oza N, Agrawal K. Granular cell ameloblastoma mimicking oncocytoma. *J Oral Maxillofac Pathol.* 2012; 16: 446-449.
- [7] Fujimaki M, Fukumura Y, Saito T, Mitani K, Uchida S, Yokoyama J, et al. Oncocytic mucoepidermoid carcinoma of the parotid gland with CRTC1-MAML2 fusion transcript: report of a case with review of literature. *Hum Pathol.* 2011; 42: 2052-2055.
- [8] Atarbashi Moghadam S, Atarbashi Moghadam F, Mokhtari S, Eini E. Immunohistochemical analysis of P63 expression in odontogenic lesions. *Biomed Res Int.* 2013; 2013: 624176.
- [9] Sams RN, Gnepp DR. P63 expression can be used in differential diagnosis of salivary gland acinic cell and mucoepidermoid carcinomas. *Head Neck Pathol.* 2013; 7: 64-68.
- [10] Olimid DA, Florescu AM, Cernea D, Georgescu CC, Mărgăritescu C, Simionescu CE, et al. The evaluation of p16 and Ki67 immunoexpression in ameloblastomas. *Rom J Morphol Embryol.* 2014; 55: 363-367.